

GENERAL GYNECOLOGY

Transumbilical versus transvaginal retrieval of surgical specimens at laparoscopy: a randomized trial

Fabio Ghezzi, MD; Antonella Cromi, PhD; Stefano Uccella, MD; Giorgio Bogani, MD; Maurizio Serati, MD; Pierfrancesco Bolis, MD

OBJECTIVE: We sought to compare transumbilical (TU) and transvaginal (TV) route for retrieval of surgical specimens at laparoscopy.

STUDY DESIGN: Women scheduled for a laparoscopic resection of an adnexal mass were randomized to have their surgical specimen removed either through a posterior colpotomy ($n = 34$) or the umbilical port site ($n = 32$). Group allocation was concealed from patients and bedside clinicians. The primary outcome was postoperative incisional pain assessed by a 10-cm visual analog scale at 1, 3, and 24 hours after surgery.

RESULTS: TV retrieval caused less postoperative pain than TU specimen extraction at each time point (visual analog scale score at 1 hour: 2.6 ± 2.9 vs 1.2 ± 2.0 , $P = .03$; at 3 hours: 2.4 ± 2.0 vs 1.4 ± 2.0 ,

$P = .02$; and at 24 hours: 1.1 ± 1.5 vs 0.5 ± 1.4 , $P = .02$). A higher proportion of women in the TU group than in the TV group indicated the umbilicus as the most painful area at 1 and 3 hours postoperatively. Two months after surgery, the participants scored similarly as to their overall satisfaction, cosmetic outcome, and dyspareunia upon resumption of intercourse.

CONCLUSION: A TV approach for specimen removal after laparoscopic resection of adnexal masses offers the advantage of less postoperative pain than TU retrieval.

Key words: adnexal mass, laparoscopy, ovarian cyst, specimen removal, transvaginal

Cite this article as: Ghezzi F, Cromi A, Uccella S, et al. Transumbilical versus transvaginal retrieval of surgical specimens at laparoscopy: a randomized trial. *Am J Obstet Gynecol* 2012;207:xx-xx.

With the firm establishment of laparoscopic surgery in current gynecologic practice, ongoing efforts are now focused on developing strategies to further reduce incisional morbidity and improve the cosmetic outcomes. Abdominal wall incisions are a significant source of postoperative complications including pain, infection, and incisional hernia.^{1,2}

With the advent of a laparoscopic approach to advanced surgical procedures, specimen removal has become a legitimate concern since in most cases of laparoscopic resections, specimens that are

to be extracted are originally larger than the port sites.³ Often the trocar incision is therefore enlarged at the beginning of the extraction procedure. However, an excessive wound enlargement, as well as stretching and tearing of the fascia during the passage of tissue through the port site, may result in the abolition of known advantages of laparoscopic surgery.⁴ Studies focused on perioperative outcomes related to the surgical wound showed that complications at the specimen extraction site account for the vast majority of laparoscopic wound complications.^{2,5}

One solution is to avoid the enlargement of a trocar incision by the use of natural orifices, such as the umbilicus or the vagina, to extract the specimen. We have earlier reported our experience with a routine policy of surgical specimen retrieval through the umbilical incision in a series of >1000 women undergoing laparoscopic gynecologic procedures for a pelvic mass.⁶ Gynecologic surgeons have used a transvaginal (TV) access to the peritoneal cavity via a posterior colpotomy for decades both for diagnostic and extirpative procedures. TV route for retrieval of surgical specimens was first described >100 years ago in the gynecologic literature,⁷ but

this approach fell into disuse with the introduction of laparoscopy into clinical practice. The reasons why TV extraction of the specimen fell out of favor include perceived technical difficulty, potential for infectious complications, concerns about patient acceptance, and unknown effects on future sexual function. Paradoxically, with the development of natural orifice specimen extraction⁸ technique as a bridge to natural orifice transluminal endoscopic surgery,⁹ the vagina has emerged as the preferred extraction site for a variety of specimens and extrapelvic organs among surgeons of several nongynecologic specialties.^{10,11}

The ideal technique of tissue extraction at laparoscopy surgery has not been given much attention in the gynecologic literature, though minimizing abdominal wall trauma may be desirable not only to improve the short-term benefits of minimal access surgery, but also to limit the high health and financial cost of wound complication management. Therefore, we decided to design a randomized trial to compare transumbilical (TU) and TV route for retrieval of surgical specimens in women with adnexal masses undergoing operative laparoscopy.

From the Department of Obstetrics and Gynecology, University of Insubria, Varese, Italy.

Received March 24, 2012; revised April 23, 2012; accepted May 21, 2012.

The authors report no conflict of interest.

Reprints: Fabio Ghezzi, MD, Department of Obstetrics and Gynecology, University of Insubria, Piazza Biroldi 1, 21100 Varese, Italy. fabio.ghezzi@uninsubria.it.

0002-9378/\$36.00

© 2012 Mosby, Inc. All rights reserved.

<http://dx.doi.org/10.1016/j.ajog.2012.05.016>

MATERIALS AND METHODS

This study was conducted in the Department of Gynecology at the University of Insubria from September 2011 through February 2012. Sexually active women found to have an adnexal mass who were scheduled for a laparoscopic procedure were invited to take part. All patients had an ultrasound investigation performed before surgery to evaluate the morphology and size of the adnexal mass. Exclusion criteria were preoperative suspicion or intraoperative diagnosis of malignancy or deep infiltrating endometriosis, indication for concomitant hysterectomy, intraoperative diagnosis of complete obliteration of the pouch of Douglas, and virginal status. Preoperative suspicion or intraoperative findings of endometriomas or pelvic adhesions were not considered as exclusion criteria. We did not set an upper size limit to the adnexal masses that could be removed laparoscopically.

The study was approved by the Azienda Ospedaliero-Universitaria Ospedale di Circolo, Macchi Foundation, Ethics Committee and all participants gave written informed consent. The trial was registered in <http://ClinicalTrials.gov> (NCT01418807). Women who entered the study were randomized to have the surgical specimen removed either through the umbilical port (TU) or TV, through a posterior colpotomy.

Randomization

Suitable patients were randomized to have their surgical specimen removed either TV or through the umbilical port site (TU) using a computer-generated randomization list. This list was held centrally by a trial administrator. Randomization was carried out by telephone. The patient was assigned by the principal investigator to treatment group TU or TV according to the randomization. Once allocated, the treatment was revealed to the surgeon immediately prior to starting the procedure, while group allocation was concealed from patients and bedside clinicians. An opaque sterile dressing was applied postoperatively over the skin wounds to prevent women from looking at their incisions size.

Operative technique

Operative laparoscopy was performed under general anesthesia in all women. Standard anesthesia and perioperative care protocols were used. After the pneumoperitoneum was created (using a Veress needle), a 0-degree 5-mm laparoscope (Karl Storz, Tuttlingen, Germany) was introduced through the umbilicus. Two or three 3-mm ancillary trocars were inserted under direct vision in the lower abdomen. One 3-mm trocar was always inserted in the midline approximately 3-6 cm above the symphysis. The other trocars were inserted under laparoscopic vision laterally to the lateral umbilical ligament. Instrumentation included graspers, scissors, monopolar electrocautery, a bipolar PK System MoLly Forceps (Gyrus Medical Inc, Maple Grove, MN), and suction-irrigation. Pelvic washing for cytological examination was performed whenever needed. Tissue evacuation was always performed using specimen retrieval bags (EndoCatch II, Tyco Healthcare Group LP, Norwalk, CT). Preemptive infiltration of trocar sites or colpotomy site with a local anesthetic was never performed.

TU specimen removal

When the surgical specimen was freed, the laparoscope was then withdrawn from the umbilical trocar. The 5-mm umbilical port was replaced with a 10-mm port to allow insertion of the specimen bag. A specimen retrieval system was then disassembled to split the specimen pouch from the dispensing tube but not from the 40-cm long thread. To facilitate introduction of the retrieval bag into the peritoneal cavity, the bag was rolled up and with the help of a grasper was blindly introduced into the abdominal cavity through the umbilical port, leaving the thread of the specimen pouch protruding from the trocar, with the free end held outside the abdomen. The laparoscope was then reintroduced alongside the thread. Once in the peritoneal cavity, the bag was opened with laparoscopic atraumatic graspers and the surgical specimen was inserted under direct vision. Then, the free end of the thread was withdrawn pulling the bag into the trocar, and this was then removed together with the umbilical tro-

car. If the surgical specimen was too large to pass through the umbilical incision, or solid components were encountered, the mouth of the sac was brought out with the help of atraumatic graspers, and the specimen was carefully morcellated using Kocher clamps and scissors inside the bag to avoid intraabdominal spillage or loss of surgical debris. Even in the presence of large adnexal masses, gentle traction on the bag during the process allowed serial exteriorization of the bag, keeping the cyst components at the incision. In case of large cystic tumors, puncture of the mass and aspiration were performed within the retrieval bag. In the worst-case scenario the port site was expanded for specimen removal. During this procedure, an ancillary trocar served as the gas delivery port to avoid loss of the pneumoperitoneum. Umbilical incisions were closed with a short-term synthetic absorbable suture, while 3-mm wounds were approximated with adhesive skin closure strips.

TV specimen removal

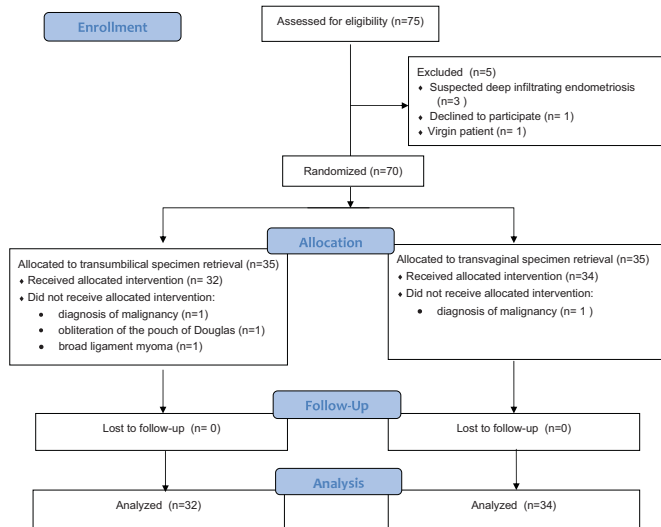
The specimen retrieval device is introduced in the vagina and is gently pushed against the vaginal wall to define the posterior fornix between the uterosacral ligaments. A 1-cm length transverse TV posterior colpotomy was performed under laparoscopic control using a 3-mm monopolar hook set at 60W.

Grasping the bag orifice with ring forceps through the colpotomy, the specimen was then pulled into the vagina. The bag orifice was opened inside the vaginal canal and the specimen was delivered through the vagina. The vaginal opening was irrigated with a povidone-iodine solution. The colpotomy was closed TV with a running 2-0 synthetic medium-term reabsorbable braided and coated suture.

Operative times were recorded from first incision to last suture. Time for specimen retrieval was calculated from TU bag insertion to TU bag removal (TU group) and from insertion of the specimen retrieval device into the vagina to the end of colpotomy closure (TV group).

FIGURE

Diagram of flow of participants through trial



Ghezzi. Transumbilical vs transvaginal specimen retrieval. *Am J Obstet Gynecol* 2012.

Postoperative evaluation

Postoperative pain was managed with 1 g of intravenous paracetamol every 8 hours to a maximum of 3 doses (the first dose was given approximately 30 minutes before skin closure). Rescue analgesia (paracetamol 1 g intravenously or ketorolac 30 mg intravenously) was administered on patient request. The timing of analgesic requirement and the total amount of medication were recorded. Each patient was asked to record the severity of her incisional pain (defined as a “pain located at the wound site”) on a 10-cm visual analog scale (VAS), with 0 being no pain and 10 the worst pain imaginable, at 1, 3, and 24

hours after incision closure. At each time point, women were asked to indicate the location of the most painful area. The patients were interviewed for pain evaluation by research assistants blinded with respect to the treatment group. At our institution, patients undergoing laparoscopy for benign gynecologic conditions are usually observed in hospital overnight and discharged on postoperative day 1. Postoperative instruction included a specific recommendation to avoid sexual intercourse for 2 weeks following the procedure.

Follow-up included an appointment 8 weeks postoperatively, at which time women were interviewed to identify any

complication that may have occurred after hospital discharge and were asked to rate their overall satisfaction with the surgical procedure, cosmetic appearance of their scars, and dyspareunia on resumption of sexual intercourse on separate VAS. If the patient did not attend the follow-up appointment, a follow-up interview was held by telephone call.

Sample size

The primary outcome measure in this trial was postoperative pain. Secondary outcome measures included need for rescue analgesia, postoperative dyspareunia, overall satisfaction score, and cosmetic outcome. Previously published data by our group indicated a mean \pm SD 1-hour postoperative pain score among women undergoing retrieval of a laparoscopically resected adnexal mass through the umbilical port-site incision of 2.3 ± 2.1 .¹² Since the average pain level in this group is low and it has been consistently reported that a difference of 13 mm on a VAS represents, on average, the minimum change in acute pain that is clinically significant,^{13,14} we hypothesized that TV specimen retrieval should at least reduce 1-hour pain score by two thirds (from 2.3-0.8) to be considered a valuable alternative. On the basis of this analysis, 32 patients were required in each arm to detect this difference with a 5% level of significance and 80% power. To allow for a 10% rate due to exclusion for intraoperative findings, a total of 70 women were sought for the study.

Statistical analysis

Statistical analysis was performed with software (GraphPad, Version 5; GraphPad Software, San Diego CA). Proportions in the 2 groups were compared using χ^2 and odds ratio with 95% confidence interval. The *t* test and the Mann Whitney *U* test were used to compare continuous variables sampled from a gaussian or non-gaussian distribution, respectively. Statistical significance was assumed when $P < .05$.

RESULTS

During the study period, 70 women were considered eligible to enter the study, consented to participate, and were ran-

TABLE 1
Patients' characteristics

Characteristic	TU retrieval (n = 32)	TV retrieval (n = 34)	P value
Age, y	42.5 \pm 12.5	47.7 \pm 12.9	.11
BMI, kg/m ²	24.1 \pm 3.9	23.8 \pm 3.6	.74
Obese	3 (9.3%)	2 (5.9%)	.67
Previous abdominal surgery	5 (15.6%)	7 (20.6%)	.75
Nulliparous	17 (53.1%)	19 (55.9%)	1.0
Adnexal mass size, cm	5 (3-30)	6 (3-21)	.51

Values are reported as mean \pm SD or number (%) or median (range).

BMI, body mass index; TU, transumbilical; TV, transvaginal.

Ghezzi. Transumbilical vs transvaginal specimen retrieval. *Am J Obstet Gynecol* 2012.

TABLE 2
Laparoscopic procedures and intraoperative details

Variable	TU retrieval (n = 32)	TV retrieval (n = 34)	P value
Estimated blood loss, mL	10 (10-50)	10 (10-200)	.08
Operative time, min	64.8 ± 28	56.6 ± 20.5	.16
Specimen retrieval time, min	4 (1-40)	3.1 (2-20)	.28
Procedures			
Ovarian cystectomy	8 (25.0%)	6 (17.6%)	.55
Monolateral salpingo-oophorectomy	12 (37.5%)	7 (20.6%)	.18
Bilateral salpingo-oophorectomy	10 (31.2%)	15 (44.1%)	.32
Monolateral salpingectomy	1 (3.1%)	2 (5.9%)	1.0
Bilateral salpingectomy	0 (0%)	2 (5.9%)	.49
Appendectomy	1 (3.1%)	0 (0%)	.48

Values are reported as median (range), mean ± SD, or number (%).

TU, transumbilical; TV, transvaginal.

Ghezzi. Transumbilical vs transvaginal specimen retrieval. *Am J Obstet Gynecol* 2012.

domized in the study. Flow of participants through the randomized clinical trial is displayed in the Figure. Four (5.7%) subjects subsequently were excluded: 2 women had intraoperative diagnoses of malignancy, 1 had severe endometriosis with complete obliteration of the pouch of Douglas, and 1 had a broad ligament 7-cm fibroid misdiagnosed as ovarian mass. The remaining 66 women were randomized to TU retrieval of the surgical specimen (n = 32) and TV removal of the specimen (n = 34).

There were no significant differences between the groups at baseline for any demographic parameter and indication for surgery (Table 1). One patient each in the TV group and in the TU group had a vaginal hysterectomy. Table 2 displays intraoperative details. No woman underwent conversion to laparotomy electively before removal of the mass or after

laparoscopic removal due to frozen section findings. No intraoperative complications occurred in either group. In the TU group, extension of the umbilical incision to about 1 cm was necessary to allow extraction of the specimen in 3 (9.4%) women. Extension of the initial colpotomy incision was necessary in 1 patient who had TV retrieval of an ovarian fibroma. Postoperative complications in the TU group included hemoperitoneum managed conservatively (n = 1) and fever in a patient with 3-cm hematoma at the site of a 3-mm ancillary port that required readmission to administer intravenous antibiotics (n = 1). The patient who had hemoperitoneum required blood transfusion (she received 4 U of packed red cells and 2 of fresh frozen plasma) and antibiotics. No postoperative complication (including col-

potomy dehiscence) occurred in the TV group.

Table 3 shows mean postoperative pain scores at specific time points. Patients who had the surgical specimen retrieved TV reported significantly less pain than those undergoing TU removal at each time point. The proportion of women who indicated the umbilicus as the most painful area was 31.2%, 31.2%, and 12.5% at 1, 3, and 24 hours postoperatively in the TU group. The corresponding figures for the TV group were 5.7%, 2.8%, and 5.7% ($P = .01$ and $P = .002$ for 1- and 3-hour assessment; $P = .42$ for the 24-hour comparison). Rescue analgesia was required in 5 (15.6%) cases in the TU group and 1 (2.8%) case in the TV group ($P = .10$).

Four (11.8%) and 2 (6.2%) patients failed to attend their follow-up visit and required telephone follow-up in the TV and TU group, respectively. The participants scored similarly on their overall satisfaction with surgery (9.5 ± 0.6 in the TU group vs 9.6 ± 0.5 in the TV group, $P = .66$) and cosmetic appearance of their scars (9.7 ± 0.5 vs 9.8 ± 0.4 , $P = .86$) 2 months after the procedure. Five women (3 in the TU group and 2 in the TV group) did not resume sexual activity due to personal or relationship issues. Dyspareunia upon resumption of intercourse was rated similarly between group (0.34 ± 0.55 in the TU group vs 0.24 ± 0.43 in the TV group, $P = .52$).

COMMENT

The results of this study suggest that retrieval of adnexal masses following laparoscopic excision via an incision at the posterior fornix of the vagina causes less postoperative pain than transabdominal specimen extraction through the umbilical port.

Over the past 20 years laparoscopy has become the accepted gold standard for the management of benign adnexal tumors. Although specimen extraction is a crucial step in laparoscopic procedures, selection of optimal extraction site has received little research attention, with only a handful of case series addressing methods of specimen evacuation available in gynecologic literature.¹⁵⁻¹⁸ There

TABLE 3
Pain scores on a 10-cm visual analog scale

Postoperative time, h	TU retrieval (n = 32)	TV retrieval (n = 34)	P value
1	2.6 ± 2.9	1.2 ± 2.0	.03
3	2.4 ± 2.0	1.4 ± 2.0	.02
24	1.1 ± 1.5	0.5 ± 1.4	.02

Values are reported as mean ± SD.

TU, transumbilical; TV, transvaginal.

Ghezzi. Transumbilical vs transvaginal specimen retrieval. *Am J Obstet Gynecol* 2012.

are several possible explanations for such limited interest in techniques for tissue extraction. First, in the early stages of laparoscopy implementation, ovarian masses >10 cm in size were considered a contraindication for minimally invasive management. Second, most ovarian tumors have a cystic structure and can be decompressed before removal. Therefore, retrieval through the abdominal ports of small, collapsed cysts may be relatively uncomplicated. Third, laparoscopists might have had the erroneous perception that a "minimal" wound enlargement is indispensable and a small difference in wound size would never result in clinically relevant outcome differences. However, with increasing ability to perform advanced laparoscopic procedures, the difficulties in retrieving bulky and rigid specimens should have arisen, and assessment of the potential suitability of alternative extraction methods was expected, just as it occurred in the urologic and general surgery literature. It is now firmly established that the size of abdominal wall incisions correlates with postoperative pain, complication rates such as hernia development, infection, and less pleasing cosmetic results.^{1,5,12,19,20} Skin incisions of ≥ 10 mm are associated with an increased risk of trocar hernias, but there is evidence that fascial and peritoneal stretching of the original incision for specimen retrieval can result in trocar site hernia even when smaller ports are used.^{21,22}

TV extraction has been proposed in an attempt to obviate the need for secondary incisions or enlargement of a trocar incision to extract the specimen. Ironically, the vagina is currently used for extraction of laparoscopically resected gallbladder, kidney, spleen, colon, gastric, and rectal tumors more frequently than for gynecologic specimens. The paucity of accounts in the literature exploring the value of posterior colpotomy to extract the specimens and explicit opinion from some authors³ indicate that gynecologists appear to be poorly convinced about the benefits to create an opening from the vagina into the peritoneal cavity for tissue evacuation. TV extraction never gained widespread adoption likely

in large part because of concerns about the potential complications of entering the peritoneal cavity via the posterior vaginal fornix and the lack of evidence of decreased morbidity compared to traditional procedure. It has been speculated that performing a colpotomy could place the patient at risk for infection, trauma to adjacent structures, dyspareunia, and adhesions that may potentially compromise fertility.

Several authors inferred conclusions on the potential risk for infectious complications with TV specimen retrieval from the hysterectomy literature. Surgical site infection after vaginal hysterectomy is rare (<1%),²³ lending further support to the use of TV access. However, the surgical field in vaginal hysterectomy is exposed to the vaginal flora during the entire operation and surgical and instrumental manipulations are carried out in the vagina throughout the procedure. With laparoscopic adnexal surgery, the time elapsed with an opening in the vagina is usually short and occurs late in the operation, therefore the potential magnitude of contamination seems lower. Similarly, estimating the risk of infection associated with posterior colpotomy for specimen extraction by reviewing the literature on culdoscopy or more recent techniques for infertility investigation seems likewise inappropriate. We have reported 63 patients and added a systematic review of the literature that included 501 patients who had undergone TV extraction of pelvic masses of >5 cm, in whom only 1 noninfectious complication related to the colpotomy was recorded.¹⁶ The risk of injury to adjacent organ seems negligible when the colpotomy incision is performed under laparoscopic vision. Our results on postoperative pain at the vaginal extraction site are in keeping with those of Gill et al²⁴ in a series of 10 patients who had undergone laparoscopic nephrectomy with vaginal specimen extraction. The patients tolerated the vaginal incision well with minimal pain (median pain questionnaire score was 2 of 10), and all women reported that the abdominal port-site incisions were more painful than the vaginal extraction site.

It can be argued that differences in VAS scores in the order of <15 mm, although of possible statistical significance, are of questionable clinical significance. Several investigators explored the concept of "minimally clinically significant" change in pain using a VAS.^{13,14,25,26} In these studies, the numeric change on the VAS was linked to the patients' subjective change in pain. A patient was considered to have a clinically significant change in pain when they reported "a little less" or "a little more" pain from the previous measurement. Patients reporting their pain as "about the same" were considered to have clinically insignificant changes in their level of pain. The investigators found that the absolute change in VAS score associated with a minimally clinically significant change in pain is directly related to the initial VAS score, whereas percentage change scores seem less biased by pretreatment pain than absolute change scores. A 33% decrease in pain has been identified as a reasonable primary standard with which different treatments can be compared.^{25,26} In a study cohort with VAS scores of <34, patients reporting a "little less" pain had a mean associated VAS score changes of 11 ± 6 mm.¹³ In the setting of postoperative pain, "little relief" was associated with an average decrease of 9.4 ± 12.4 mm (percentage changes of 12.5%) among patients who had a laparotomy.²⁵ We were not able to find any study on this issue in the setting of minimally invasive surgery, where the average postoperative pain intensity is expected to be low. However, bringing together available data in the literature, we believe that a 54% difference (14-mm absolute difference) in mean VAS scores 1-hour postoperatively between study arms in the current study can be judged as clinically meaningful. Similarly, a 42% difference (10-mm absolute difference) in the mean VAS scores 3 hours postoperatively seems of clinical significance. Whether a 6-mm difference from 1.1-0.5 at the 24-hour assessment, although statistically significant, would be of any appreciable benefit is probably questionable.

TV access for specimen retrieval should produce little if any adverse effects in terms of sexual function. The colpotomy incision is at the apex of the vagina in the midline posteriorly, causing minimal disturbance

of the pelvic nerve plexus and vaginal innervation, which lies in a relative anterolateral position. Women in the TV group reported high satisfaction with the procedure and a low average dyspareunia score at 2 postoperative months, although detailed effects on sexual function and quality of life have not been addressed. However, we acknowledge the potential for imperfect blinding causing bias in the results of the 2-month interview, since patients in the TU group might have had a larger surgical scar that may have been noticed after removal of the dressing.

In conclusion, a TV approach for specimen removal after laparoscopic resection of adnexal masses offers the advantage of less postoperative pain, with equivalent operative time and patient satisfaction rates compared with TU retrieval. The ideal specimen extraction method must not compromise patient safety either intraoperatively or in the postoperative period, must not be too time-consuming, should prove easy to perform, and should not nullify the advantages of minimally invasive approach. TV specimen extraction following laparoscopy seems to meet most of these requirements. Since patient safety is paramount, the potential complications related to the retrieval technique are of greatest importance and need to be investigated in larger cohorts. Moreover, the outcomes of TV retrieval must be studied using validated pain and quality-of-life questionnaires that include sexual function domains and compared in a prospective randomized fashion with conventional transabdominal techniques. ■

REFERENCES

- Swank HA, Mulder IM, la Chapelle CF, Reitsma JB, Lange JF, Bemelman WA. Systematic review of trocar-site hernia. *Br J Surg* 2012; 99:315-23.
- Winslow ER, Fleshman JW, Birnbaum EH, Brunt LM. Wound complications of laparoscopic vs open colectomy. *Surg Endosc* 2002;16:1420-5.
- Miller CE. Methods of tissue extraction in advanced laparoscopy. *Curr Opin Obstet Gynecol* 2001;13:399-405.
- Ihedioha U, Mackay G, Leung E, Molloy RG, O'Dwyer PJ. Laparoscopic colorectal resection does not reduce incisional hernia rates when compared with open colorectal resection. *Surg Endosc* 2008;22:689-92.
- Singh R, Omiccioli A, Hegge S, McKinley C. Does the extraction-site location in laparoscopic colorectal surgery have an impact on incisional hernia rates? *Surg Endosc* 2008; 22:2596-600.
- Ghezzi F, Cromi A, Uccella S, Siesto G, Bergamini V, Bolis P. Transumbilical surgical specimen retrieval: a viable refinement of laparoscopic surgery for pelvic masses. *BJOG* 2008;115: 1316-20.
- Kelly HA. Treatment of ectopic pregnancy by vaginal puncture. *Bull Johns Hopkins Hosp* 1896;7:208.
- Palanivelu C, Rangarajan M, Jategaonkar PA, Anand NV. An innovative technique for colorectal specimen retrieval: a new era of "natural orifice specimen extraction" (N.O.S.E). *Dis Colon Rectum* 2008;51:1120-4.
- Palanivelu C, Rajan PS, Rangaranjan M, Parthasarathi R, Senthilnathan P, Prasad M. Transvaginal endoscopic appendectomy in humans: a unique approach to NOTES: world's first report. *Surg Endosc* 2008;22:1343-7.
- Diana M, Perretta S, Wall J, et al. Transvaginal specimen extraction in colorectal surgery: current state of the art. *Colorectal Dis* 2011; 13:e104-11.
- Box GN, Bessler M, Clayman RV. Transvaginal access: current experience and potential implications for urologic applications. *J Endourol* 2009;23:753-7.
- Ghezzi F, Cromi A, Colombo G, et al. Minimizing ancillary ports size in gynecologic laparoscopy: a randomized trial. *J Minim Invasive Gynecol* 2005;12:480-5.
- Bird SB, Dickson EW. Clinically significant changes in pain along the visual analog scale. *Ann Emerg Med* 2001;38:639-43.
- Todd KH, Funk KG, Funk JP, Bonacci R. Clinical significance of reported changes in pain severity. *Ann Emerg Med* 1996;27:485-9.
- Teng FY, Muzsnai D, Perez R, Mazdisnian F, Ross A, Sayre J. A comparative study of laparoscopy and colpotomy for the removal of ovarian dermoid cysts. *Obstet Gynecol* 1996; 87:1009-13.
- Ghezzi F, Raio L, Mueller MD, Gyr T, Buttarelli M, Franchi M. Vaginal extraction of pelvic masses following operative laparoscopy. *Surg Endosc* 2002;16:1691-6.
- Ghezzi F, Cromi A, Ciravolo G, Rampinelli F, Braga M, Boni L. A new laparoscopic-transvaginal technique for rectosigmoid resection in patients with endometriosis. *Fertil Steril* 2008; 90:1964-8.
- Pillai R, Yoong W. Posterior colpotomy revisited: a forgotten route for retrieving larger benign ovarian lesions following laparoscopic excision. *Arch Gynecol Obstet* 2010;281: 609-11.
- Yamamoto M, Minikel L, Zaritsky E. Laparoscopic 5-mm trocar site herniation and literature review. *JLS* 2011;15:122-6.
- Sajid MS, Khan MA, Ray K, Cheek E, Baig MK. Needleoscopic versus laparoscopic cholecystectomy: a meta-analysis. *ANZ J Surg* 2009;79:437-42.
- Kadar N, Reich H, Liu CY, Manko GF, Gimpelson R. Incisional hernias after major laparoscopic gynecologic procedures. *Am J Obstet Gynecol* 1993;168:1493-5.
- Tonouchi H, Ohmori Y, Kobayashi M, Kusunoki M. Trocar site hernia. *Arch Surg* 2004;139:1248-56.
- Edwards JR, Peterson KD, Andrus ML, Dudeck MA, Pollock DA, Horan TC. National Healthcare Safety Network (NHSN) report, data summary for 2006 through 2007, issued November 2008. *Am J Infect Control* 2008;36: 609-26.
- Gill IS, Cherullo EE, Meraney AM, Borsuk F, Murphy DP, Falcone T. Vaginal extraction of the intact specimen following laparoscopic radical nephrectomy. *J Urol* 2002;167:238-41.
- Jensen MP, Chen C, Brugger AM. Interpretation of visual analog scale ratings and change scores: a reanalysis of two clinical trials of postoperative pain. *J Pain* 2003;4:407-14.
- Farrar JT, Portenoy RK, Berlin JA, Kinman JL, Strom BL. Defining the clinically important difference in pain outcome measures. *Pain* 2000;88:287-94.