

TECNICHE DI RICOSTRUZIONE DELLA SUPERFICIE POSTERIORE DEL PADIGLIONE AURICOLARE E DELLAMASTOIDE CON LEMBI LOCALI

MARIO CHERUBINO - MASSIMILIANO TRIPOLI - DOMENICO CAPIZZI - SALVATORE MARTORANA - CARMELA MOSSUTO - SALVATORE D'ARPA

Università degli Studi di Palermo - Dipartimento di Discipline Chirurgiche ed Oncologiche - Sezione di Chirurgia Plastica e Ricostruttiva - (Direttore: Prof. F. Moschella)

[Techniques for reconstruction of the posterior auricular and mastoid surfaces with local flaps]

SUMMARY

Background. Reconstruction of the posterior auricular surface and of the mastoid has never been given much attention and there are no techniques described.

The authors describe two techniques for reconstruction of these areas after cancer excision with local flaps.

Methods. 13 patients have been treated after cancer resection with an advancement flap from the posterior auricular surface and a bilobed flap from the mastoid.

Results. All flaps healed uneventfully with a satisfactory aesthetic outcome. No relevant complications have been observed.

Conclusions. Reconstruction of the posterior auricular surface and of the mastoid with the techniques described allows satisfactory defect closure even in complex situations such as cartilage or bone exposure.

Key words: Ear reconstruction, mastoid region reconstruction, ear cancer, bilobed flap, advancement flap

RIASSUNTO

Introduzione. La ricostruzione della superficie posteriore del padiglione auricolare e della mastoide è stata sempre poco studiata e non esistono tecniche specifiche in letteratura.

Gli autori descrivono due tecniche per ricostruire queste regioni dopo asportazione di tumori con lembi locali.

Metodi. Un lembo di avanzamento dalla superficie posteriore dell'orecchio, ed un lembo bilobato dalla mastoide sono stati usati in 13 pazienti per la ricostruzione, della mastoide e della superficie posteriore del padiglione auricolare.

Risultati. Tutti i lembi hanno consentito una copertura adeguata della perdita di sostanza insieme ad un risultato estetico soddisfacente. Non sono state osservate complicanze di rilievo.

Conclusioni. La ricostruzione della superficie posteriore del padiglione e della mastoide con le tecniche descritte assicura una ottimale copertura delle perdite di sostanza anche in situazioni complesse come in caso di esposizione ossea o cartilaginea.

Parole chiave: Ricostruzione dell'orecchio, ricostruzione della regione mastoidea, tumori dell'orecchio, lembo bilobato, lembo d'avanzamento

Article

Reconstruction of posterior auricular and mastoid defects is a difficult issue because there are not many techniques described in literature and because it may sometimes be challenging due to bone and cartilage exposure.

In cases of cartilage or bone exposure and in cases of deep defects in the sulcus, or when a skin graft donor site is to be avoided, the authors use local flaps from the posterior auricular and mastoid regions: an advancement flap from the posterior-medial auricular surface or the mastoid and a tran-

sposition bilobed flap from the mastoid for posterior auricular and complex posterior auricular and mastoid defects.

The advancement flap from the posterior-auricular skin is nourished by anastomoses from the three – inferior, middle and superior – divisions of the posterior auricular artery which also interconnect, along the helix and through the cartilage, with the anterior auricular artery network⁽³⁾.

Since its first description by Esser in 1918⁽¹⁾, the bilobed flap, due to the possibility of harvesting a transposition flap from an area of minor laxity, where direct closure is not possible, and to close the

donor site with a second flap based on the same pedicle, has found several application in face and other body regions reconstruction ^(1-2,5-13,15-20).

In this article, an advancement flap from the posterior auricular surface and a modified bilobed flap from the mastoid and lateral neck regions are described for reconstruction of mastoid and posterior auricular surfaces after cancer resection.

Materials and methods

13 patients with cancers of the posterior auricular and mastoid surfaces have been treated at the Istituto di Chirurgia Plastica e Ricostruttiva of the Università degli Studi di Palermo.

In 5 cases the defect was located in the mastoid surfaces and was reconstructed with an advancement flap from the posterior-auricular surface. In three of them there was bony exposure.

In 3 cases the defect after cancer resection involved the posterior auricular skin and was covered by a bilobed flap from the mastoid region.

In 4 cases cancer resection led to a composite defect in the posterior-auricular and mastoid surfaces also involving the deep retroauricular sulcus. A bilobed flap from the mastoid surface was used in these cases.

The average size of the defect was 2.3 x 1.7 cm (range 1x1.5- 3x2 cm).

Surgical Technique

Advancement flap

Cancer resection is performed with adequate margins and the defect is given a square shape. A flap of adequate dimensions is planned laterally based on the posterior auricular surface and excision of two skin triangles at the base of the flap is planned in order to let the flap advance (Fig. 1-7).

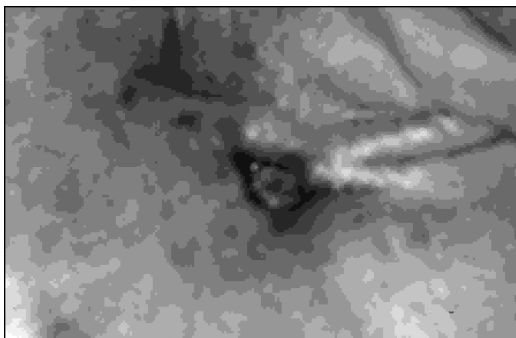


Figure 1: Basal cell carcinoma of the left retroauricular sulcus.

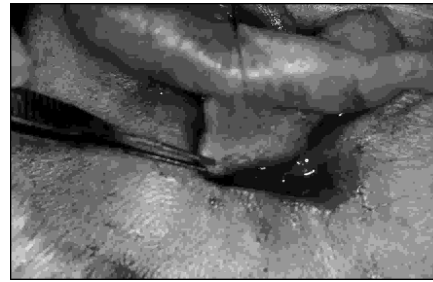

Figure 2: After cancer excision and flap harvesting, the flap is advanced to cover the defect.

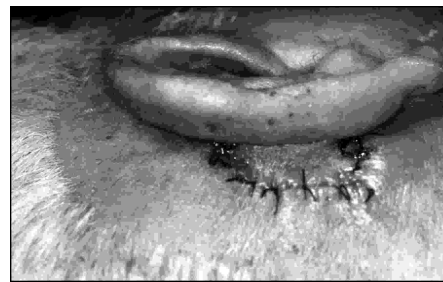

Figure 3: Immediate postoperative result with the stitches in place.

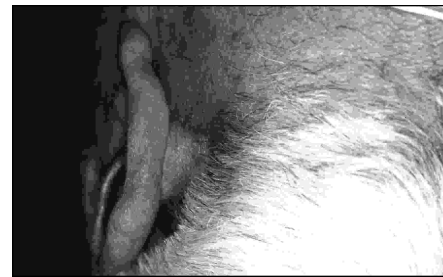

Figure 4: 6 months after the operation scars are unapparent and the sulcus is maintained.

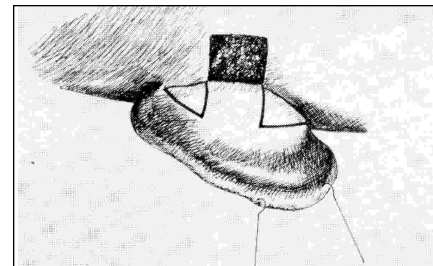


Figure 5: Schematic drawing of the defect and of the flap outlined in the skin.

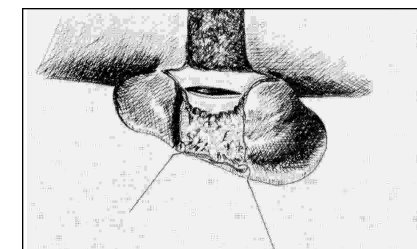


Figure 6: Schematic drawing of the flap raised in its entirety and of the incision in the cartilage to achieve more advancement.

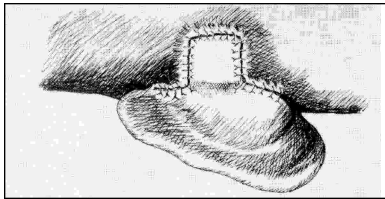


Figura 7: Schematic drawing of the flap sutured. Suture lines placed cephalad and caudad correspond to the two triangles excised to let the flap advance.

The flap is undermined in a supraperichondral plane.

To achieve better advancement the conchal cartilage may be scored or partially resected as needed.

Bilobed flap

Cancer resection is performed with adequate margins.

The flap is planned with the first lobe, as big as the defect, transversely or obliquely oriented over the mastoid and posterior neck, taking care to avoid the air bearing skin.

The tip of this lobe may be split to fit the apex of the sulcus.

The pivot point is the caudal edge of the defect.

The second lobe is placed in the lateral neck just behind the ascending ramus of the mandible and parallel to it in order to conceal the scar.

This lobe may be also as big as the first one as there is very little tension in this area in contrast with the mastoid.

Subcutaneous dissection is completed to raise the flap taking care not to injure the Great Auricular Nerve.

The two lobes are transposed, anchored to the deep surface of the defect to reproduce the sulcus, and sutured to the defects (Fig. 8-10).

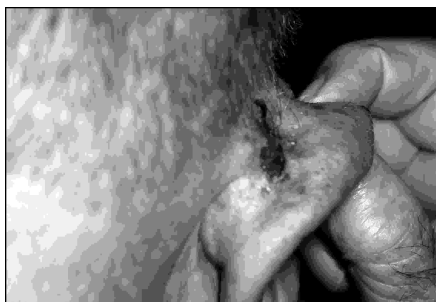

Figure 8: Basal cell carcinoma of the right retroauricular sulcus.

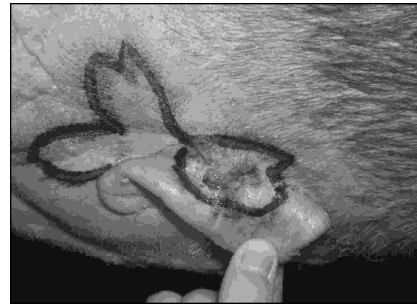


Figure 9: Excision margins and the bilobed flap are drawn in the skin.

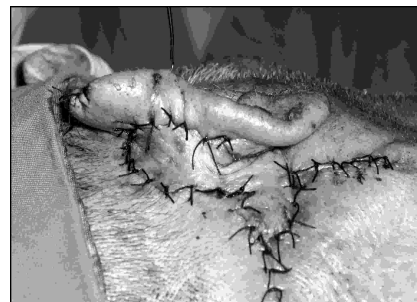


Figure 10: Immediate postoperative result with the flap sutured to the defect.

Results

Follow-up ranges from 12 to 36 months.

All flaps healed uneventfully.

On histopathological examination, besides 3 squamous cell carcinomas, all the lesions were basal cell carcinomas.

No recurrence was observed during the follow-up period.

All the flaps healed uneventfully and allowed for satisfactory defect coverage with preservation of good ear shape and cephalic-auricular angle.

Discussion

The postero-medial auricular or the mastoid surfaces are not a concern for the reconstructive surgeon because these areas are well hidden. Skin grafting or primary closure are the preferred methods for reconstruction without concerns for functional or aesthetic morbidity⁽¹⁶⁾.

Reconstruction of this area has not in fact been given much attention⁽¹⁷⁾ both because of the poor aesthetic importance of this area and the relative rarity of cancers arising in this area. Furthermore, posterior auricular and mastoid skin are shaded areas and subsequently seldom affected by sun-related malignancies.

The rarity of this tumors, together with the poor aesthetic relevance of this region, account for the lack of well described techniques for reconstruction of this area.

Primary closure or skin grafting, however, are not always feasible. In cases in which there is bone exposure the skin graft is not indicated, as it is not in deep, hollow defects. Furthermore, sometimes a skin graft donor site is not desirable. Flap reconstruction is indicated in these cases.

The flaps described in this article provide a simple, reliable, option to reconstruct the area behind the ear.

Skin with similar colour, texture and thickness is used.

Vascularization is safe. It is provided in both cases by branches of the posterior auricular artery which for a rich network behind the ear^(4,14).

The overall shape of the ear is preserved and so is the auriculo-cephalic angle. The airline is not disrupted.

The possibility of wearing glasses is not compromised because the apex of the sulcus is always preservable.

Conclusions

The authors describe two safe and effective options to reconstruct the posterior auricular surface and the mastoid surfaces which may sometimes be a challenge in cases of big and deep defects.

Coverage is satisfactory and the aesthetic result is pleasing as the scars are well concealed and the transferred skin is very similar to the skin to be replaced.

References

- 1) Aguilar E. F. III *Ear Reconstruction*. Clin Plast Surg. 2004; 31: 87-91.
- 2) Alam M. and Goldberg L. H. *Two-lobed advancement flap for cutaneous helical rim defects*. Dermatol Surg. 2003; 29: 1044-9.
- 3) Cordova A., Di Gregorio C., Leopardi V., Bivona F., Salerno S. *Descrizione di un metodo per la riparazione delle perdite di sostanza della regione mastoidea*. Gior Chir Plast Ricostr ed Estet. 1992; 1.
- 4) D'Arpa S., Cordova A., Moschella F. *Further application of the bilobed flap: The split bilobed flap for reconstruction of composite posterior auricular and mastoid defects*. J Plast Reconstr Aesthet Surg 2006; 59: 1330-1335.
- 5) Friedman M., Toriumi D. M., Grybauskas V. *The bilobed deltopectoral advancement flap*. Arch Otolaryngol Head Neck Surg. 1987; 113: 612-4.
- 6) Guleman R., Speranzini M. B., Guleman B. *The bilobed flap in nasal reconstruction*. Br J Plast Surg. 1998; 51: 493-8.
- 7) Harch R. E., Stark G. B. *The contralateral bilobed trapezius flap for closure of large defects of the dorsal neck permitting primary donor site closure*. Head and Neck. 2000; 22: 513-9.
- 8) Iida N., Ohsumi N., Tonegawa M., Tsutsumi Y. *Reconstruction of scalp defects using simple designed bilobed flap*. Aesthetic Plast Surg. 2000; 24: 137-40.
- 9) Jackson I. T. *Bilobed Flap*. In: Jackson I.T. *Local Flaps in Head and Neck Reconstruction*. St. Louis – Toronto – Princeton, The C.V. Mosby Company, 1985, 21.
- 10) Mc Gregor J. C., Mc Leon N. R. *Reconstruction of a large nasal defect using a bilobed forehead flap*. Ann Plast Surg. 1982; 9: 419-24.
- 11) Mc Gregor J. C., Soutar D. S. *A critical assessment of the bilobed flap*. Br J Plast Surg. 1981; 34: 197-205.
- 12) Meyer R., Kelly T. P., Abul Failat A. S. *Single bilobed flap for use in head and neck reconstruction*. Ann Plast Surg. 1981; 6: 203-6.
- 13) Reddy L. V. and Zide M. F. *Reconstruction of skin cancer defects of the auricle*. J Oral Maxillofac Surg 2004; 62: 1457-71.
- 14) Renner G. and Templer J. *Reconstruction of the external ear*. Facial Plast Surg Clin North Am. 1996; 4: 491-503.
- 15) Sutton A. E., Quatela V. C. *Bilobed flap reconstruction of the temporal forehead*. Arch Otolaryngol Head Neck Surg. 1992; 118: 978-82.
- 16) Weerda H. *Ear- the auricle*. In: Soutar D. S. and Tiwari R. *Excision and reconstruction in head and neck cancer*. New York, Churchill Livingstone, 1994, p. 223;
- 17) Zimany A. *The Bilobed Flap*. Plast Reconstr Surg. 1955; 16: 434.
- 18) Zitelli J. A. *The bilobed flap for nasal reconstruction*. Arch Dermatol. 1989; 125: 957-9.

Request reprints from:

Dott. D'ARPA SALVATORE

U.O. Chirurgia Plastica e Ricostruttiva

Via del Vespro, 129

90127 Palermo

(Italy)