



# Radiology of Mummies

Marta Licata, PhD\*, Adelaide Tosi, PhD student\*,

Omar Larentis, PhD student\*, Chiara Rossetti, MD\*,

Silvia Iorio, PhD\*\*, and Antonio Pinto, MD, PhD\*\*\*

\*Centre of Research in Osteoarchaeology and Paleopathology, Department of Biotechnology and Life Sciences, University of Insubria, Via O. Rossi 9, 21100 Varese, Italy.

\*\* Department of Molecular Medicine, Unit of History of Medicine, Sapienza University of Rome, Viale Regina Elena, 291, 00161 Rome, Italy.

\*\*\* Department of Radiology, CTO Hospital, Azienda Ospedaliera dei Colli, Naples, Italy.

Corresponding author: Marta Licata [marta.licata@uninsubria.it](mailto:marta.licata@uninsubria.it)

## Abstract

In the past, autoptic examinations were usually performed for research. This type of examination, for obvious reasons, did not appeal to paleopathologists as these procedures potentially damaged the finds destined to musealization. Since the discovery of X-ray, radiology has been used to study mummies as a non-invasive technique. The radiology of mummies allows us to discover pathologies, to elaborate on the type of ritual mummification for the artificial embalming, to comprehend the diagenetic process that guaranteed a natural mummification or to conclude anthropological identification.

We present a review on the latest studies on mummies that have shown that the radiological approach has been essential to conduct research.

## The development of Paleoradiology

Immediately after the discovery of X-rays by Wilhelm Conrad Röntgen in November 1895, George Walter Koenig performed the first radiographic study on ancient human remains. The results of this first investigation, conducted at the *Physical Society of Frankfurt am Main*, were published in 1896 in the volume entitled *14 Photographs with X-rays taken from the Physical Society of Frankfurt am Main*.<sup>i</sup> The investigation was carried out on a mummified cat and on the knees of a mummy of a child.<sup>ii</sup> From that moment, X-ray has been used for a very long time to analyze ancient mummified bodies.<sup>iii</sup> In 1896, one year after the discovery by Röntgen, an X-ray investigation on an Egyptian mummy was performed. It is, therefore clear that, from the first possibilities of its use, we have tried to apply radiological techniques to archaeology or rather to physical anthropology. After Koenig, in 1897, Petrie X-rayed ancient human mummies, Khayat X-rayed the mummy of Pharaoh Thutmose IV, followed by Moodie in 1931 who analyzed seventeen Egyptian mummies preserved in the Field Museum in Chicago in 1931.<sup>iv</sup> At this point, it is interesting to remember that among the first radiological analysis conducted on royal Egyptian mummies were those of Pharaohs Thutmosis IV<sup>v</sup> and Amenophis I.<sup>vi</sup> In 1967, the great project of radiological study of the royal mummies collected at the Cairo Museum, developed this field of research.<sup>vii-viii</sup>

However, we had to wait about a century for the term “paleoradiology coined by Derek Notman, a radiologist at Park Nicollet Center, to appear in an article published in the *American Journal of Roentgenology*<sup>9</sup> in 1987.

The official recognition of radiological techniques by the anthropological and archaeological sciences came during the study of bodies not just mummified but also frozen. Notman and two of his colleagues, a pathologist and an anthropologist studied, from the radiological point of view, the frozen bodies of the tragic 1845 John Franklin expedition. The examinations have gained greater importance in recent years mainly thanks to the evolution of radiological technologies.<sup>ix</sup>

While bone structures due to physical properties (high attenuation) are quite easily differentiated, soft tissue components are much more challenging, especially if they are overlapping (skin on top of muscle fascia and muscles above internal organs etc.). Fundamentally, with conventional X-rays, a structure is exposed two-dimensionally and the various soft-tissue layers show equal attenuation values, eventually making discrimination (spatial / tissue) difficult. It is here that the CT scan takes over, becoming the chosen imaging technique: the CT scanner offers three-dimensional segmentation of the structures.<sup>x-xi</sup>

In addition to this, when the find is not easily observable, such as when the body is in a fetal position inside a sarcophagus, still enclosed in the bandage or when there are overlapping images, it is difficult to investigate with X-rays.<sup>xii</sup> These problems were resolved when in 1970 computerized axial tomography was added to X-ray technology.<sup>xiii</sup> Soon thereafter, the first CT scans were conducted on mummies.<sup>xiv</sup> In 1979, the radiologist Harwood-Nash reported the CT examination of an Egyptian mummy.<sup>xv</sup>

For high spatial resolution, image contrast and the various post-processing modes, CT immediately became a sophisticated technique to study mummified remains.<sup>xvi</sup> With the improvement of the radiological techniques of computerized tomography in the nineties, other innovations including multidetector CT (MDCT) led to a better rendering of radiological images.

MDCT has the advantage of eliminating all overlapping structures and has a much higher resolution than the first generation CT scanners. MDCT scanners also allow the spatial relationships of different structures to be examined. This data can then be reformatted into any visualization plane and provide a 3D rendering of the structures.

Other the advantages offered by MDCT include being able to select the area of interest (ROI) and therefore the ability to measure the density using so-called Hounsfield unit measurements. These are used for mummified artifacts to ensure that substances and structures are accurately identified.

With the introduction of digitalized radiology and multi-layered computerized axial tomography, spatial resolution improves substantially allowing for three-dimensional reconstructions.<sup>xvii</sup>

Moreover, it is possible to perform a guided bio-autopsy, obtaining samples in areas of interest without risk of damage to the mummified body's integrity. Even Magnetic Resonance (MR), although initially considered unnecessary to study the mummified remains because it is difficult to apply this on dry tissue, was available with surprising results for the study of bio-archeological findings.<sup>xviii-xix</sup> X-ray microtomography or MICRO CT is also used to examine and reconstruct in 3D, allowing better observation of anatomical changes in the tissues associated with mummification.<sup>xx</sup>

Furthermore, CT-Osteoabsorptiometry (CT-OAM), based on the set of conventional CT, is a system that allows visualizing the disposition of mineral density in the subchondral bone plate and to show in this way the surfaces of the joints. Recently this method has also been tested on mummified finds. The study showed that with the CT-OAM, it was possible to see the pathological distributions at the level of the articular surfaces.<sup>xxi</sup>

It is evident that radiology makes it possible to observe the inside of the find, usually intended for musealization, without destroying it. For this reason, it represents the first method of investigation to be used when studying mummified finds.

### **The radiology of natural mummies**

The word mummy is used to indicate a body that has been preserved both naturally and artificially. Among the natural mummies which we are aware such as the *bog bodies*, human remains, especially those recovered in Denmark and date back mainly to the Iron Age, have been preserved because they existed within the swamp land.

The low temperatures, anaerobic environment and acidity of the water allowed this extraordinary preservation of the tissues, so that the bodies, once found and dug thousands of years later, are noticeably intact.

On the contrary, the preservation of the skeleton is almost never perfect because the mineral component of the bone has been altered by the acidity of the bog. For this reason, it is difficult to

evaluate these finds radiographically. Additionally, connective tissues such as ligaments, fascia and subcutaneous tissue, become more radio-dense. In this way, some structures can remain masked, especially when only two dimensions are used. In recent times, many bog bodies have been re-radiologically analyzed with CT scans. This investigation has allowed us to distinguish certain lesions, for mortals from post-mortem injuries, caused by diagenetic and taphonomic agents.

It is important to report here the case of the Grauballe man. The remains were found in 1952 and the first medical and radiological analysis revealed that the individual had a cut to the throat and he had also received a blow to the head and a blow to the leg. According to these early interpretations of the lesions they had been classified as perimortal. The individual was dealt the blow to his leg before the execution to prevent him from running away while the blow to the head had taken place during the sacrificial ritual as well as cutting the throat.

This theory was known as “over-kill”. When the Grauballe mummy was scanned with CT in 2001, scientists were able to better evaluate he skull and to understand that the head was fractured post-mortem and not because of the blow. It was also questioned whether the leg had also not suffered a blow, instead could it have been the pressure of the soil that shattered the tibia bone post mortem.

In this way, CT analysis allowed us to offer an alternative version of the human history of Grauballe, not a history of inter-personal violence.<sup>xxii</sup>

### **Radiology of artificial mummies**

The most representative artificial mummification is most certainly Egyptian mummified men and animals. The preservation of the post-mortem body was a necessary condition for continuing existence toward the afterlife.

In the radiological investigation of artificial mummified finds, the aims are different: study the burial equipment underneath the bandage and then proceed with the examination of the mummified human remains and the underlying skeleton. At the same time, proceed with the identificative

examination by studying the mummified animal remains to better understand the funeral ritual but also to have information on the animal of that period.

The latest studies on mummies include the use of the multidetector computed tomography (MDCT). In this regard, it is interesting to point out the study of amulets, jewelry and other items discovered external to the mummy in the Egyptian royal mummies of the 18<sup>th</sup>-20<sup>th</sup> dynasty to better understand the funeral preparations of that time. Using MDCT it is possible in a short time using thin sections to provide a complete non-invasive mummy analysis. The technique in this study allowed us to recognize the metals and the ceramics with which the funeral goods were produced. In addition, the ability to obtain three-dimensional images also allowed us to recognize the type of equipment. For example, the 3D image of the sovereign Thutmose III (1479-1425 BC) allowed us to observe two bracelets that had been worn on the right arm; moreover the high density of the bracelets (3060 HU) permitted us to recognize that they were made of metal, probably gold. The three-dimensional image reconstructed in an oblique coronal projection in the mummy of Ramesses III (1187-1156 BC) at the level of the thorax, shows four terracotta figures representing the four sons of Horus.<sup>xxiii</sup>

It is also important to understand the ritual of Egyptian mummification is also includes the study of mummified animals. Taking this into account, a particularly interesting study was carried out on 152 mummies of animals from 17 UK museum collections. The radiographs were obtained by posterior, lateral and oblique projection. Every single image has been recorded and archived with the PACS (Picture Archiving and Communication System).

This radiological investigation allowed us to obtain several details of the mummy to identify the taxonomic attribution. For example, the researchers noted that bird mummies, especially ibis and falcons, were predominantly represented. Crocodiles, perch and catfish were also presented in the collection of mummified animals. In this study, the CT analyses were important to understand the pathological condition of the animals and the post mortem treatment of the body of the animals, and to determine if the animals were sacrificed. One example of perimortem trauma was discovered in a crocodile: a blunt force trauma to the periorbital region. This research highlighted that it was

difficult to identify the evidence for evisceration in the preparation of animals, only one case clearly shows traces of this treatment.<sup>xxiv</sup>

### **“Paleoradiopathology” of mummies**

The radiological investigations carried out on the mummified findings also allow us to highlight the pathological conditions and to evaluate the possible causes of death of the subject. In this regard, there is an interesting study with MDCT on the Fontego dei Turchi (Venice), collected by the Italian explorer Giovanni Maini (1810-1872) who discovered several mummies in a cave above the Arabian Chain. In particular, the MDCT analysis allowed us to see a spinal fracture and a severe degenerative osteoarthritis of the left femur of a mummy from the coronal section.

Another case is the paleoradiological investigation of a female mummy, dating from 1451-1642 AD, that allowed us to obtain circumstantial evidence of a massive head injury afflicted on a young adult female just before death. The paleopathological investigation on the mummy also revealed a chronic *Trypanosoma ruzi* infection (Chagas disease). The mummy (initially considered a German swamp body) was confined by stable isotopic analysis in South America. The CT scan allowed us to see signs of a severe craniocerebral lesion, in particular the destruction of the central, upper and frontal parts of the skull. The sagittal image of the head and neck showed numerous bone fragments inside the skull. In fact, the CT three-dimensional reconstruction of the skull from the back view showed a particular anthropological trait typical of Inca populations: an additional bone in the lambdoid suture, known as wormian bone. This study is very interesting from an anthropological point of view because through a multidisciplinary approach (macroscopical, isotopically, molecular and radiological examinations) it was possible to suggest a hypothesis of ritual homicide of a Peruvian young female affected by Chagas disease.<sup>xxv</sup>

Among several natural mummified human remains collected in the Center of Research in Osteoarchaeology and Paleopathology of University of Insubria and discovered in the common



ossuary of Sacro Monte, a little lower limb was radiologically investigated and showed a fracture of the fibula (Fig. 1A and 1B). From the same burial site, a partially mummified skull (Fig. 2A) was examined with CT and showed small osteomas (Fig. 2B).

Among the paleopathological investigations carried out to resolve the etiological origin of several diseases, there are the studies regarding atherosclerosis of Egyptian mummies. Fifty-two mummies preserved at the Egyptian National Museum of Antiquities in Cairo are particularly interesting. CT was performed revealing that twenty of them had signs of atherosclerosis pathology represented by arterial calcifications.

For example, the oblique image 3D volume shows the coronary artery with calcification in the Amhose-Meritatum mummy of Thebes, an Egyptian ruler who lived in 1580-1550 BC, who died between 40-45 years of age.<sup>xxvi</sup>

There is another paleoradiological study in which it was necessary to use radiology to discover a pathological condition. The radiological investigation conducted on the mummy of the Patriarch Joseph Tyan by the researchers of Was Qadisha mummy project allowed us to understand the state of preservation of the mummy and the possible cause of death of the Patriarch. For X-ray analysis, a mobile digital radiographic system was transported into a room near the tomb of the Patriarch. Through a radiological approach, it was possible to understand that the mummy was rapidly and naturally mummified but some signs of degradations were noted. This mummy is interesting, from the paleopathological point of view, because the radiographic analysis discovered a densely radio-opaque solid mass diagnosed as urinary bladder stone. Radiological investigation showed the impressive width of the ovoid stone having a maximum diameter of 48 mm. The internal structure was composed of several concentric layers around a nucleus, indicating the growth of a nidus.<sup>xxvii</sup>

The CT examination conducted on the ancient Iranian salt mummy (Chehrabad ca. 410-350 BC) showed an extraordinary state of preservation of an adolescent corpse. Through radiological investigation it was possible to note several variants such as aplasia of the frontal sinus and a rare congenital deformity of the 5<sup>th</sup> vertebral body. A CT scan also revealed multiple peri- and

postmortem alterations of the body especially at the level of the skull (evident in the 3D reconstruction) where there were multiple fractures of the temporal and parietal bones as well as rib fractures on the right side of the thorax. The radiological evaluation has shown that the individual had multiple fractures supporting the theory that he died due to a collapse in the ancient salt mine.<sup>xxviii</sup>

Other studies show how the interdisciplinary approach is indispensable for revealing some historical enigmas; the CT study conducted on the mummy of Ramses III (1190-1070 BC) confirmed that the sovereign had been attacked. In fact, a previous study of the computed tomography (CT) of the mummified Ramesses neck proposed that an assailant cut the Pharaoh's throat with a knife in the plot known as the Harem conspiracy.

New CT scans showed the partially amputated left foot with no signs of healing. With these new radiological observations, it was possible to reinforce the hypothesis that the pharaoh suffered a brutal and fatal attack inflicted by assailants who used different instruments.

In addition, radiological investigations have also made it possible to point out that the embalmers replaced the missing part with a linen prosthesis and placed 6 metal amulets (eye of Horus) in the region of the feet.<sup>xxix</sup>

The pathological case of dysplasia of the congenital hip in a mummy recovered in the Roccapelago crypt in the Italian Apennines along with 12 other natural mummies is certainly interesting. With the use of the reconstructions of coronal MPR and VC, the findings were clearly demonstrated; the disease shows a superficial bilateral hip dysplasia associated with marked coxo-femoral arthritis. In addition, moderate bilateral arthritis of both knees was also noted.<sup>xxx</sup>

From a paleopathological point of view, the study of the baby mummy from South America, collected in the State Museum of Detmold (Germany), where CT analysis shows hypoplastic left heart syndrome. The signs of pathology are characterized by a small left ventricle and a small ventriculoseptal defect. This is particularly fascinating because 3D CT showed a small vessel feeding the coronary arteries at the area of the aorta.<sup>xxxii</sup>

Another interesting study was carried out with CT for the systematic detection of orthopedic conditions in 52 ancient Egyptian mummies with a technique of medical imaging where all the large joints and the vertebral column were inspected. These investigations revealed that the cruciate ligaments and the meniscus are highlighted with a certain frequency. Above all, several cases of scoliosis have been diagnosed.<sup>xxxii</sup>

The radiological approach in the study of mummies was important particularly in the research that was conducted on several mummies of the Capuchin church of Palermo. Using paleoradiological investigations, it was possible to identify evidence of gout, DISH and degenerative joint disease<sup>xxxiii</sup>. Again, from the site, a CT scan was performed on a mummy that belonged to a young man revealing interesting pathological conditions. From the CT images it was possible to observe the edge of the aortic dissection, approximately 1.8 cm distal to the level of the aortic valve suggesting the diagnosis of Marfan syndrome.<sup>xxxiv</sup>

Included within the paleoradiological research conducted in Italy, is a recent study using CT analysis on the mortal remains of Saint Leopold Mandic (1866-1942), a Capuchin Saint of Padova, Italy. This study allowed the researcher to observe the presence of osteoarthritis on the spinal column, left knee, and left hand. A mummy housed in the Basel Museum of Cultures, dated 1650 AD, was examined using CT to determine tissue conservation status, gender, age at death, pathological markers and the type of mummification.<sup>xxxv</sup> The mummy belonging to a child aged 7-9 years, shows several signs of neurofibromatosis type 1 (paravertebral and cutaneous neurofibromas, a mammary neurofibroma, dysplasia of the sphenoid wing), Chagas disease (dilatation) of the esophagus, stomach, rectum and large amounts of feces) and pulmonary infection (pleural adhesion, calcification) probably due to tuberculosis. Interestingly, the CT analysis also revealed an image of an envelope indicating a ceremonial burial. Within the cultural background, the signs of fatal violence have been discussed as a possible result of war, murder, accident or human sacrifice.<sup>xxxvi</sup>

In addition, the mummy discovered in the site of Mungyeong Country (Korea) in 2010 and dated to 1650 CE showed signs of tuberculosis. The CT images of the mummy, highlighted six radiopaque

nodules in the right lung. The presence of the nodules and associated pleural adhesion has allowed us to formulate a hypothesis of pulmonary tuberculosis. This study is very important from a paleopathological point of view because it represents the first test of tuberculosis attested to in the pre modern Korean sample.<sup>xxxvii</sup> Another case from Korea is the radiological analysis on the mummy of the Joseon Dynasty (1392-1910 CE), that belonged to a man of 63 years of age who lived in the 17<sup>th</sup> century. The CT scan, using MDCT scanner revealed a radiopaque round mass noted at the level of the liver and the autopsy inspection carried out later revealed the mass to be fossilized feces. A subsequent parasitological examination of the mass sample revealed a large number of ancient *Paragonimus* sp. Eggs, therefore the diagnosis was a liver abscess caused by ectopic paragonimiasis.<sup>xxxviii</sup>

### **Paleoradiology on the embalming-mummification process**

In the case of the friar Leopoldo Mandic's mummy discussed above, it is also interesting to understand some of the methods of embalming the bodies of the saints. In fact, radiological investigation showed the preservation of some viscera. This is interesting from a religious point of view as the CT scan demonstrated that the corpse of the saint was not subjected to any conservative treatment. In actuality, the corpse of Saint Leopold was found mummified due a natural process.<sup>35</sup> More recently, a study was published in the *International Journal of Legal Medicine* on the radiological approach of a mummy of a noble man, Messer Louys de Bruslon, Lord of Plessis, who died on November 1661,. To understand the type of mummification the researcher used MSCT, angiography and an autopsy. MSCT images provided interesting information regarding the mummification process. The images showed multiple cuts and fractures revealing that the embalmers had cut the thoracic cavity and raised the ribs and the sternum to eviscerate the abdominal cavity which they subsequently filled with packing materials of different density.<sup>xxxix</sup>

Another study on the preservation of tissue was conducted on the mummies of Capuchin Catacomb of Palermo, with the “Checklist and Scoring System for the Assessment of Soft Tissue Preservation in Human Mummies”.<sup>40</sup> CT was performed on twenty-three mummies to understand the type of embalming procedure used on the corpses. Seventeen of these mummies were anthropogenically mummified while six were mummified spontaneously. The artificial mummies that have obtained the highest level of conservation are those in which the radiological survey allowed us to see the intra-arterial filling.

The “medical mummy”, dating back to the 19th-20th century and housed in the History of Medicine Museum, Vilnius University, has recently been scanned with CT. The images showed several incisions indicating that this is a case of chemical embalming through a multi-point injection method. Through the last radiological analysis, the researchers hypothesized that the body was artificially mummified for educational-scientific purposes and not for funeral purposes.<sup>xl</sup>

Radiological analysis with MDCT and post-processing was performed on a child’s mummy from the Egyptian Museum in Turin date back to the Roman period (119-123 AD). The latest CT images have allowed us to identify the thickness of the bandage that varies from a minimum of 30 mm to the head and a maximum of 70 mm around the legs. The thoracic and abdominal cavities are largely filled with impregnated linen, with densities ranging from 60 to 80 HU compatible with the resin. The CT images also show a lesion 55 mm long and 15 mm wide at the level of the left anterior wall of the abdomen incision occurred during access for evisceration.<sup>xli</sup>

At this point of our discussion, it is essential to highlight an archive project of radiological images (with the IMPACT database) in which samples of large-scale primary data were collected for anthropological and paleopathological investigations. This IMPACT database allows researchers to appreciate and interpret health and disease patterns in ancient times and the variability present in mummification traditions in ancient Egypt and in other cultures that wanted to preserve their corpse for eternity.<sup>xlii</sup>

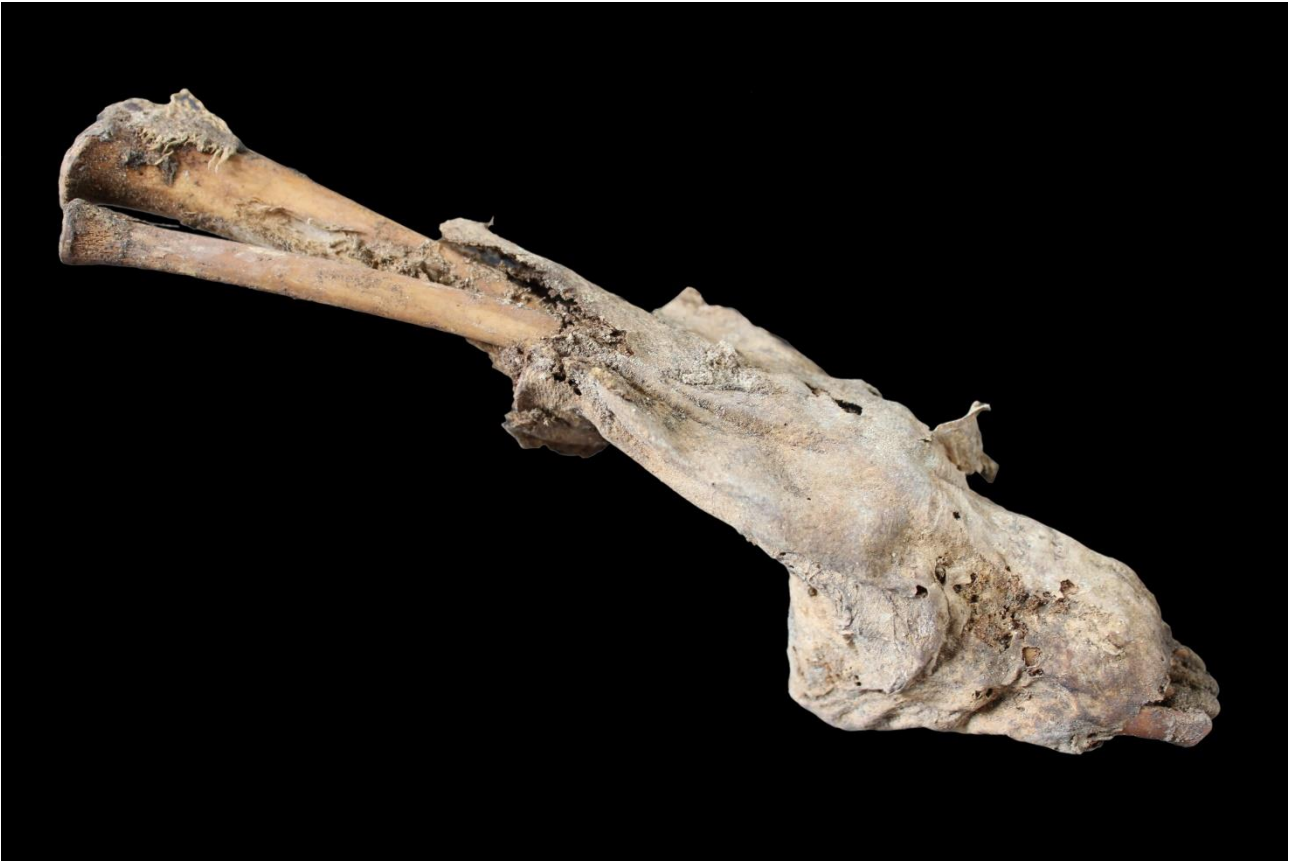## Conclusions

Today's literature offers many paleoradiology studies on mummified remains. Today, thanks to the techniques continuously developing, it is possible to go deeply into anthropological and paleopathological research. We can better analyze certain pathological conditions of the past and better understand the different embalming techniques that characterized funeral procedures in different cultures.

In the future, we also envisage a greater involvement of museums as well as research facilities in the creation of virtual reconstructions of finds, especially for those not who may not have ready access, improving the dissemination of anthropological goods. We could do this thanks to "paleoradiology".

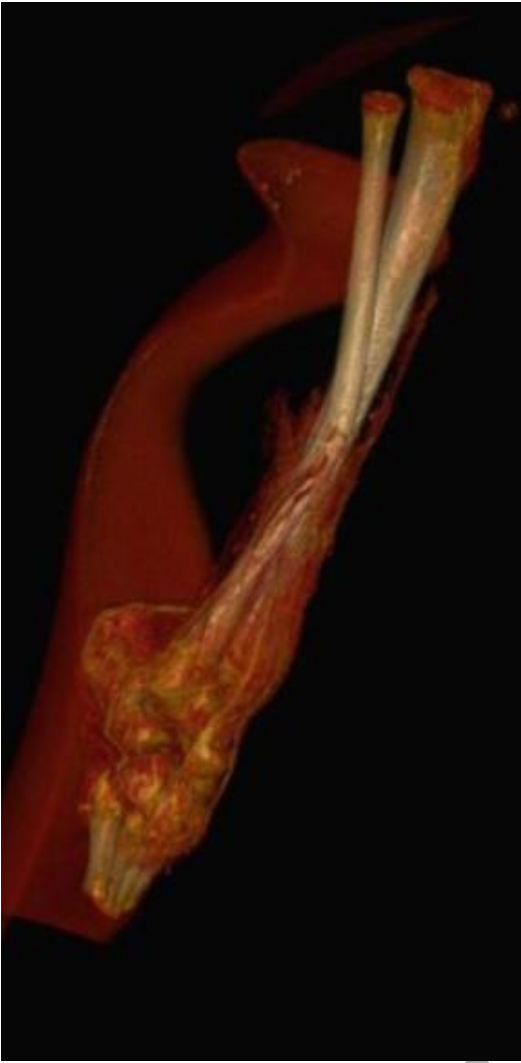
### Figure 1

A Mummified lower limb of a child from Sacro Monte (Varese, Italy).



B Computed Tomography of lower limb showing the fracture of the fibula.

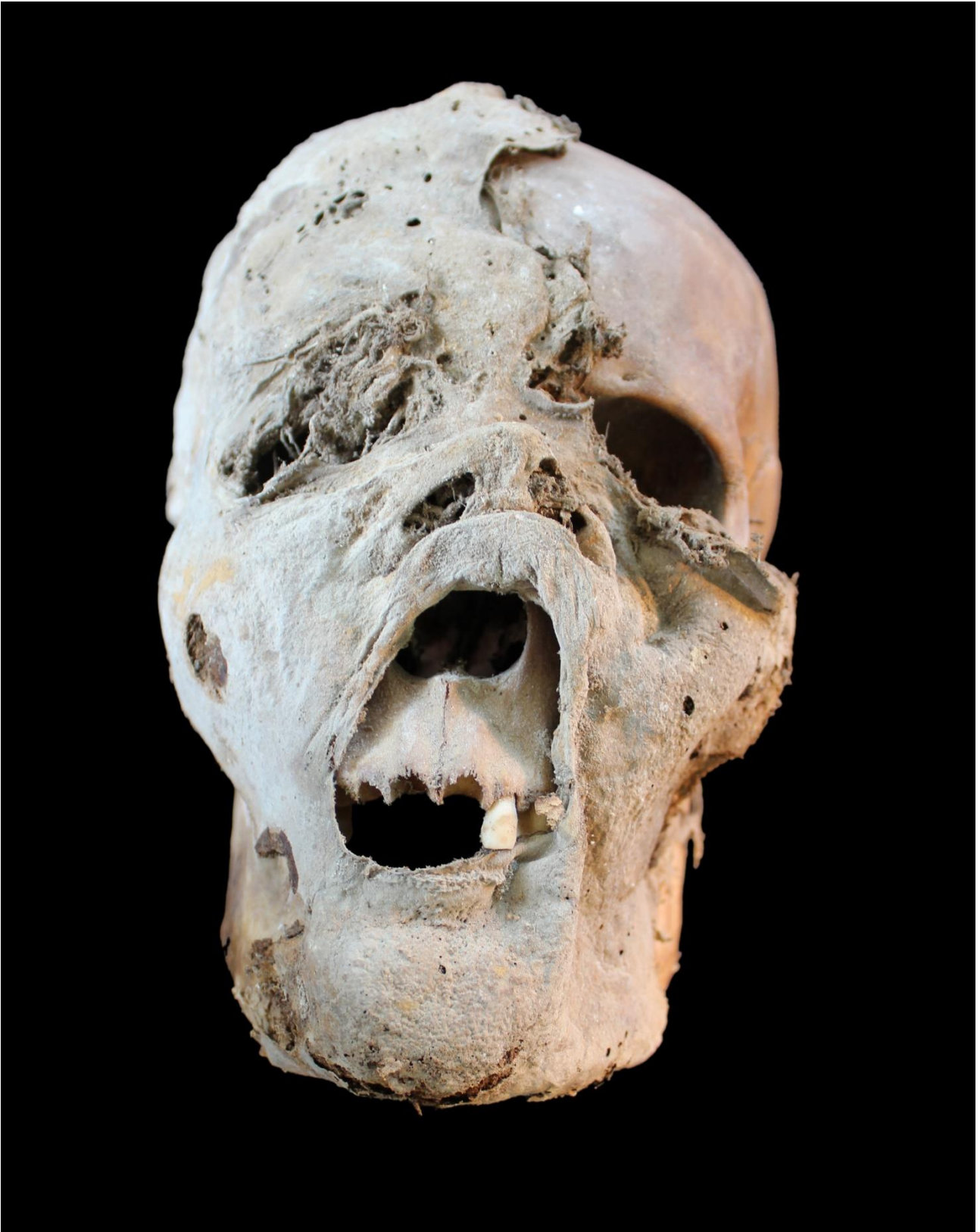ACCEPTED MANUSCRIPT



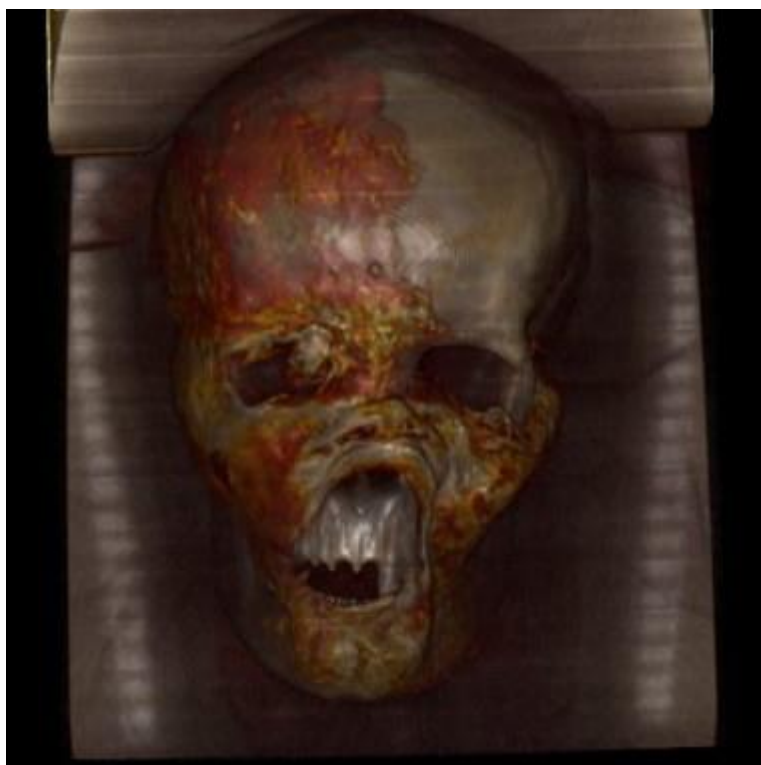
**Figure 2**

A. Mummified skull from Sacro Monte (Varese, Italy).





B. Computed Tomography showing osteomas in the frontal region.




---

## References

1. Zesch S, Panzer S, Rosendahl W, et al: From first to latest imaging technology: Revisiting the first mummy investigated with X-ray in 1896 by using dual-source computed tomography. *Eur J Radiol Open* 3:172-181, 2016
2. Beckett RG, Conlogue GJ. *Paleoimaging field applications for cultural remains and artifacts*. Boca Raton: CRC Press, 2010.
3. Lynnerup N, Rühli F. Short Review: The Use of Conventional X-rays in Mummy Studies. *Anat Rec (Hoboken)* 298(6):1085-1087, 2015
4. Fiori MG, Nunzi MG: The earliest documented applications of X-rays to examination of mummified remains and archaeological materials. *J R Soc Med* 88(2):67-69, 1995
5. Smith GE: *The royal mummies*. Le Caire: Imprimerie de l'Institut Français d'Archéologie Orientale, 1912
6. Derry DE: An X-ray examination of the mummy of king amenophis I. *Ann Service Antiquités* 34:47-48, 1934.
7. Harris JE, Weeks KR: *X-raying the pharaohs*. London: McDonald, 1973
8. Harris JE, Wentz EF: *An X-ray atlas of the royal mummies*. Chicago: University of Chicago, 1980
9. Notman DNH, Anderson L, Beattie O, et al: Arctic paleoradiology: portable radiographic examination of two frozen sailors from the Franklin expedition (1845–1848). *Am J Radiol* 149: 347-350, 1987
10. Licata M, Borgo M, Armocida G, et al: New paleoradiological investigations of ancient human remains from North West Lombardy archaeological excavations. *Skel Radiol* 45(3):323-331, 2016
11. Licata M, Armocida G, Brogginini M, et al: To investigate the degenerative alterations of the spine in Paleopathology. *Acta Reumatol Porto* 42:94-95, 2017
12. Licata M, Rossetti C, Tosi A, et al: A foetal tile from an archaeological site: anthropological investigation of human remains recovered in a medieval cemetery in Northern Italy. *J Matern Fetal Neonatal Med Jun*;31(11):1527-1529, 2018
13. Rogers LF: The radiography of ephyseal incurie. *Radiol* 96:289-299, 1970
14. Lewin PK, Harwood-Nash DC: Computerized axial tomography in medical archaeology. *Paleopathol Newsl* 17:8-9, 1977.
15. Harwood-Nash DC: Computed tomography of ancient Egyptian mummies. *J Comput Assist Tomogr* 3(6):768-773, 1979
16. Beckett RG: Paleoimaging: a review of applications and challenges. *Forensic Sci Med Pathol* 10:423-436, 2014.

17. Dedouit F, Savall F, Mokrane FZ, et al: Virtual anthropology and forensic identification using multidetector CT. *Br J Radiol* 87(1036):20130468, doi: 10.1259/bjr.20130468, 2014
18. Notman DNH: Use of nuclear magnetic resonance imaging of archaeological specimens. *Paleopath Newsl* 24;9-12, 1983
19. Rühli FJ: Short Review: Magnetic Resonance Imaging of Ancient Mummies. *Anat Rec (Hoboken)* 298(6):1111-1115, 2015
20. Beckett RG: Paleoimaging: a review of applications and challenges. *Forensic Sci Med Pathol* 10:423-436, 2014
21. Hirsch AC, Hotz G, Rosendahl W, Zumstein V, Rühli FJ, Müller-Gerbl M: CT-Osteoabsorptiometry (CT-OAM) - a new investigation technique in the field of mummy research. *Anthropol Anz* 74(1):1-7, 2017
22. Lynnerup N: Bog bodies. *Anat Rec (Hoboken)* 298(6):1007-1012, 2015
23. Saleem SN, Hawass Z: Multidetector Computed Tomographic Study of Amulets, Jewelry, and Other Foreign Objects in Royal Egyptian. *J Comput Assist Tomogr* 38(2):153-158, 2014
24. McKnight LM, Atherton-Woolham SD, Adams JE: Imaging of Ancient Egyptian Animal Mummies. *Radiographics* 35(7):2108-2120, 2015
25. Panzer S, Peschel O, Haas-Gebhard B, et al: Reconstructing the life of an unknown (ca. 500 years-old South American Inca) mummy--multidisciplinary study of a Peruvian Inca mummy suggests severe Chagas disease and ritual homicide. *PLoS One* 9(2), 2014
26. Clarke EM, Thompson RC, Allam AH, et al: Is atherosclerosis fundamental to human aging? Lessons from ancient mummies. *J Cardiol* 63(5):329-334, 2014
27. Capasso L, Licata M, Pinto A, et al: A giant urinary bladder stone in the mummy of Lebanese Maronite Patriarch Joseph Tyan (1760–1820) and its environmental and nutritional implications. *Radiogr* 23(1):67-72, 2017
28. Öhrström LM, Seiler R, Böni T: Radiological findings in an ancient Iranian salt mummy (Chehrābād ca. 410-350 BC). *Skeletal Radiol* 44(6):811-821, 2015
29. Saleem SN, Hawass Z: Computed Tomography Study of the Feet of Mummy of Ramesses III: New Insights on the Harem Conspiracy. *Send to J Comput Assist Tomogr* 41(1):15-17, 2017
30. Petrella E, Piciocchi S, Feletti F, Barone D, Piraccini A, Minghetti C, Gruppioni G, Poletti V, Bertocco M, Traversari M: CT Scan of Thirteen Natural Mummies Dating Back to the XVI-XVIII Centuries: An Emerging Tool to Investigate Living Conditions and Diseases in History. *PLoS One* 11(6):e0154349. doi: 10.1371, 2016
31. Haas NA, Zelle M, Rosendahl W, et al: Hypoplastic left heart in the 6500-year-old Detmold Child. *Lancet* 385(9985):2432, 2015
32. Fritsch KO, Hamoud H, Allam AH, Grossmann A, Nur El-Din AH4, Abdel-Maksoud G, Soliman MA, Badr I, Sutherland JD8, Sutherland ML, Akl M, Finch CE, Thomas GS, Wann LS, Thompson RC: The orthopedic diseases of ancient Egypt. *Anat Rec (Hoboken)* 298(6):1036-1046, 2015
33. Piombino-Mascalì D, Jankauskas R, Zink AR, et al: Paleoradiology of the Savoca Mummies, Sicily, Italy (18th-19th Centuries AD). *Anat Rec (Hoboken)* 298(6):988-1000, 2015
34. Panzer S, Thompson RC, Hergan K, Zink AR, Piombino-Mascalì D: Evidence of aortic dissection and Marfan syndrome in a mummy from the Capuchin Catacombs of Palermo, Sicily. *Int J Paleopathol* 22:78-85, 2018
35. Macchi V, Picardi EEE, Porzionato A, Morra A, Tabarin L, Gusella F, Grignon B, De Caro R: Friar Leopold Mandic (1866-1942): the computed tomography of the body of a saint. *Surg Radiol Anat* doi: 10.1007/s00276-018-2050-0, 2018
36. Panzer S, Wittig H, Zesch S, Rosendahl W, Blache S, Müller-Gerbl M, Hotz G: Evidence of neurofibromatosis type 1 in a multi-morbid Inca child mummy: A paleoradiological investigation using computed tomography. *PLoS One* 12(4):e0175000, 2017
37. Kim YS, Lee IS, Oh CS et al: Calcified Pulmonary Nodules Identified in a 350-Year-Old-Joseon Mummy: the First Report on Ancient Pulmonary Tuberculosis from Archaeologically Obtained Pre-modern Korean Samples. *J Korean Med Sci* 31(1):147-151, 2016
38. Shin DH, Kim YS, Yoo DS, et al: A Case of Ectopic Paragonimiasis in a 17th Century Korean Mummy. *J Parasitol* 103(4):399-403, 2017
39. Colleter R, Dedouit F, Duchesne S, et al: Study of a seventeenth-century French artificial mummy: autopsical, native, and contrast-injected CT investigations. *Int J Legal Med* doi: 10.1007/s00414-018-1830-8, 2018
40. Piombino-Mascalì D, Jankauskas R, Kozakaitė J, et al: Paleoimaging of a modern mummy from Lithuania (circa 19th-20th century). *Medicina (Kaunas)* 53(6):410-419, 2017
41. Martina MC, Cesariani F, Boano R, et al: Petamenophis (Padiamenemipet), an Egyptian Child Mummy Protected for Eternity: Revelation by Multidetector Computed Tomography. *J Comput Assist Tomogr* 42(2):178-183, 2018

- 
42. Nelson AJ, Wade AD: Impact: development of a radiological mummy database. *Anat Rec (Hoboken)* 298(6):941-948, 2015

ACCEPTED MANUSCRIPT