



Modified reverse septal flap: A surgical hint

Gianluca Dalfino¹  | Andrea Ronchi¹ | Giorgio Sileo¹ | Luca Volpi^{2,3} |
Maurizio Bignami^{1,3}

¹Division of Otorhinolaryngology Head and Neck Surgery, Department of Biotechnology and Life Sciences, University of Insubria, Varese, Italy

²Department of Otolaryngology Head and Neck Surgery, Ospedale Sant'Anna, University of Insubria, Como, Italy

³Head and Neck Surgery & Forensic Dissection Research center (HNS&FDRc), Department of Biotechnology and Life Sciences, University of Insubria, Varese, Italy

Correspondence

Gianluca Dalfino and Maurizio Bignami, Division of Otorhinolaryngology Head and Neck Surgery, Department of Biotechnology and Life Sciences, University of Insubria, Via Guicciardini, 9 21100 Varese, Italy.
Email: gianluca.dalfino@gmail.com

Funding information

None

Abstract

Endoscopic resection with transnasal craniectomy (ERTC) and skull-base reconstruction (SBR) are effective techniques for sinonasal/skull-base malignancies treatment. Endoscopic endonasal SBR techniques are mainly based on homologue-free grafts with excellent outcomes, but alternative techniques can be used such as regional vascularized pedicled flaps or local pedicled flap-like Hadad–Bassagasteguy nasoseptal flap and the septal flip flap (SFF). The purpose of this article is to describe an inferiorly based septal flap aimed to promote mucosal healing and improve patients' quality of life. We reported a clinical case of 51-year-old female affected by olfactory neuroblastoma, Hyams-II, Kadish-INSICA-B treated with unilateral ERTC and SBR with fascia lata, SFF, and modified reverse septal flap (mRSF). The mRSF harvesting is described in detail, to obtain a lower hinged flap with random vascularization, which can be rotated to cover the exposed bone of the nasal cavity floor. Endoscopic evaluations immediately showed rapid healing with a minimal amount of nasal crusting, despite the adjuvant treatment and the short time since the surgery. This surgical technique is a simple and viable way to boost nasal healing after endoscopic endonasal surgery and for nasal floor resurfacing after septal removal following a unilateral ERTC.

KEYWORDS

endoscopic transnasal craniectomy, reverse flap, septal flip flap, sinonasal malignant tumor, skull-base reconstruction

Key points

- A new septal pedicled flap with random vascularization, easy and rapidly to harvest, useful in endoscopic endonasal surgery when performing an endoscopic resection with transnasal craniectomy.
- This surgical technique allowed to improve mucosal healing and patients' quality of life affected by sinonasal malignant tumors; particularly, patients that are treated with multimodal treatments.

This is an open access article under the terms of the [Creative Commons Attribution-NonCommercial-NoDerivs](https://creativecommons.org/licenses/by-nc-nd/4.0/) License, which permits use and distribution in any medium, provided the original work is properly cited, the use is non-commercial and no modifications or adaptations are made.

© 2024 The Authors. *World Journal of Otorhinolaryngology - Head and Neck Surgery* published by John Wiley & Sons Ltd on behalf of Chinese Medical Association.

INTRODUCTION

Endoscopic resection with transnasal craniectomy (ERTC) is an effective technique for sinonasal/skull base malignancies treatment which implies an anterior skull base (ASB) defect. Endoscopic endonasal skull-base reconstruction (SBR) techniques are mainly based on homologue-free grafts with excellent outcomes,¹ but side-effects are still a problem, especially nasal crusting when extra-nasal grafts are used.

Alternative techniques like regional vascularized pedicled flaps offer great results in terms of closure, but involve major surgeries, with aesthetic and hospitalization problems.

Local pedicled flap-like Hadad-Bassagasteguy nasoseptal flap (nSF) and the septal flip flap (SFF) have high success rates, boost healing of the surgical cavity, and are optimal for patients who require adjuvant treatments,² but are also burdened by morbidities in form of nasal crusting and pain.

Our intent is to describe an inferiorly based septal flap aimed to promote mucosal healing and improve patients' quality of life.

MATERIALS AND METHODS

A 51-year-old female was referred to our department complaining with a 6-month history of right nasal obstruction. Radiology (computed tomography [CT] scan and magnetic resonance imaging) showed a solid unilateral neformation in the right nasal cavity with ethmoidal and lamina cribra involvement (Figure 1). Preoperative histology was olfactory neuroblastoma, Hyams-II, Kadish-INSICA-B according to Kadish-INSICA staging system.³ Surgical indication was given to obtain a free margin resection via unilateral ERTC and SBR with fascia lata, SFF and modified reverse septal flap (mRSF).⁴ The procedures performed in this study were in accordance with the ethical standards of the institutional research committee and with Helsinki Declaration.

Unilateral ERTC of malignant tumors invading the ASB has been described elsewhere.^{1,4} The skull base defect is reconstructed transnasally in a multilayered manner using two layers of iliotibial tract and/or fascia lata as free grafts. The duraplasty is then resurfaced using the SFF. Flap harvesting is performed as previously described.⁴ Inferiorly, however, the horizontal back-to-front incision

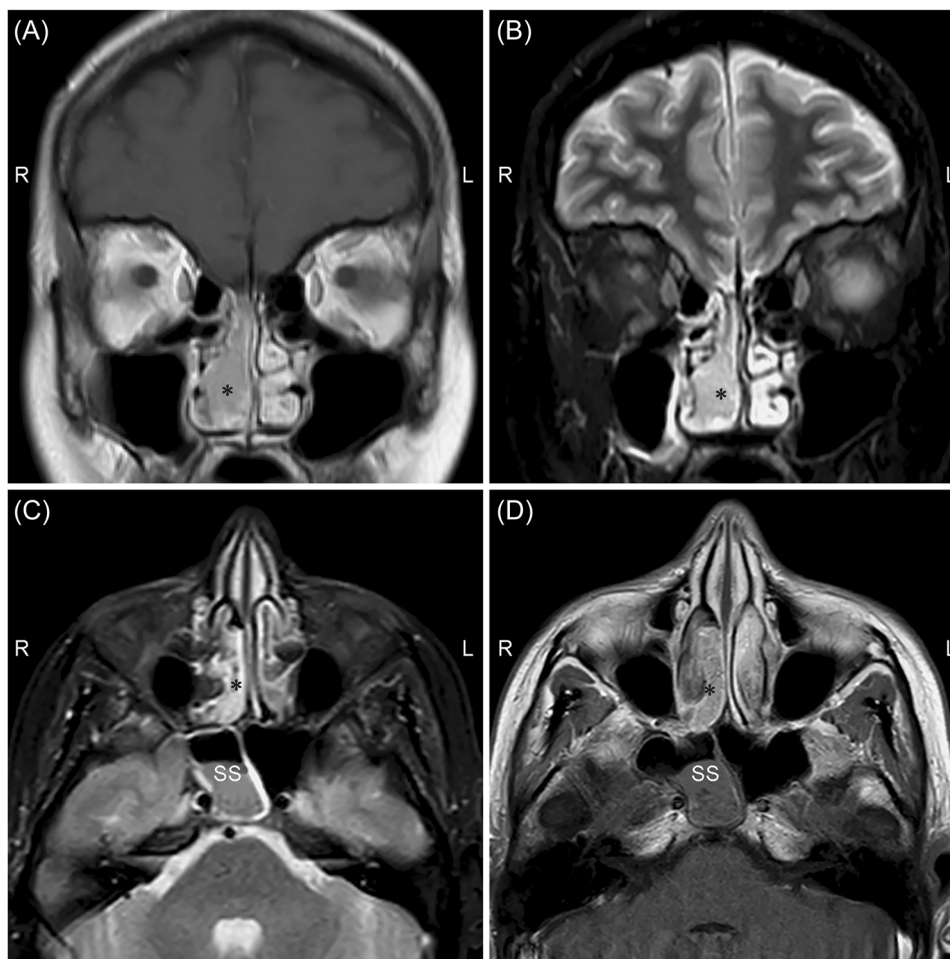


FIGURE 1 Preoperative contrast-enhanced T1-weighted magnetic resonance imaging (MRI) in coronal (A) and axial (C) view showing a hyperintense neformation of right ethmoid and nasal fossa with contrast enhancement. The black asterisk points out the neformation. Preoperative coronal (B) and axial (D) MRI showing a T2-hypointense signal of the ethmoidal neformation and the T2-hyperintense inflammatory signal in right sphenoidal sinus (SS).

must be made at least 1 cm from the floor of the nasal cavity, to obtain a lower hinged flap with random vascularization.

In this manner, the SFF is hinged superiorly and rotated freely to cover the ASB defect as overlay third layer, and the mRSF, hinged inferiorly, is rotated to cover the exposed bone at the level of the nasal palatine crest and the nasal maxillary crest (Figure 2).

Both flaps are then fixed with fibrin glue and Surgicel (Johnson & Johnson Medical) and the nasal cavities are packed bilaterally with Merocel 2000 (Medtronic Xomed Surgical Products) for about 48 h. No Foley balloon catheter is needed to buttress the flap.

RESULTS

Procedure's time was 240 min. No intraoperative and postoperative complications were observed. Definitive histological examination confirmed olfactory neuroblastoma, Hyams-II, Kadish-INSICA-B.

The CT scan performed on postoperative Day 1 showed good surgical outcomes and no pneumoencephalus. The multidisciplinary evaluation, based on the final histological examination, indicated an adjuvant radiotherapy treatment. Endoscopic evaluations immediately showed rapid healing with a minimal amount of nasal crusting, despite the radiotherapy treatment and the short time since the surgery (Figure 3). Patient showed no evidence of disease at 6 months of follow-up (Figure 4).

DISCUSSION

SFF proved to be a valid alternative to the reliable nSF in selected cases. Its harvesting requires a subtotal septectomy to be performed, leaving the nasal fossa floor bone at the level of nasal palatine crest and nasal maxillary crest exposed and leading to extensive crusting and patient discomfort, with the necessity of several endoscopic medications.

Resurfacing the exposed bone proved to reduce this inconvenience even during a complete radiotherapy treatment. Strober et al.⁵ described a so-called reverse septal flap (RSF) used to cover the nSF donor site where septal cartilage is left exposed that can be effective to reduce crusts, pain, and patient discomfort.

We then designed a lower hinge flap, harvested from the remaining inferior part of the uninvolved side of septum mucoperiosteum, remnant from flip-flap harvesting, that is flipped over to cover the exposed bone of the nasal floor.

We found very encouraging outcomes using our mRSF in terms of crusting reduction, improvement of patients' clinical well-being and quality of life. This flap allows the resurfacing of the exposed nasal floor with healthy respiratory epithelium, preserving the physiological mucociliary clearance and enabling a faster healing. The resurfaced nasal floor was noticeably less covered by crusts; patients experienced little to none pain during medications and referred an overall better postoperative course. The need of less extensive endoscopic medications results in a better follow-up compliance.

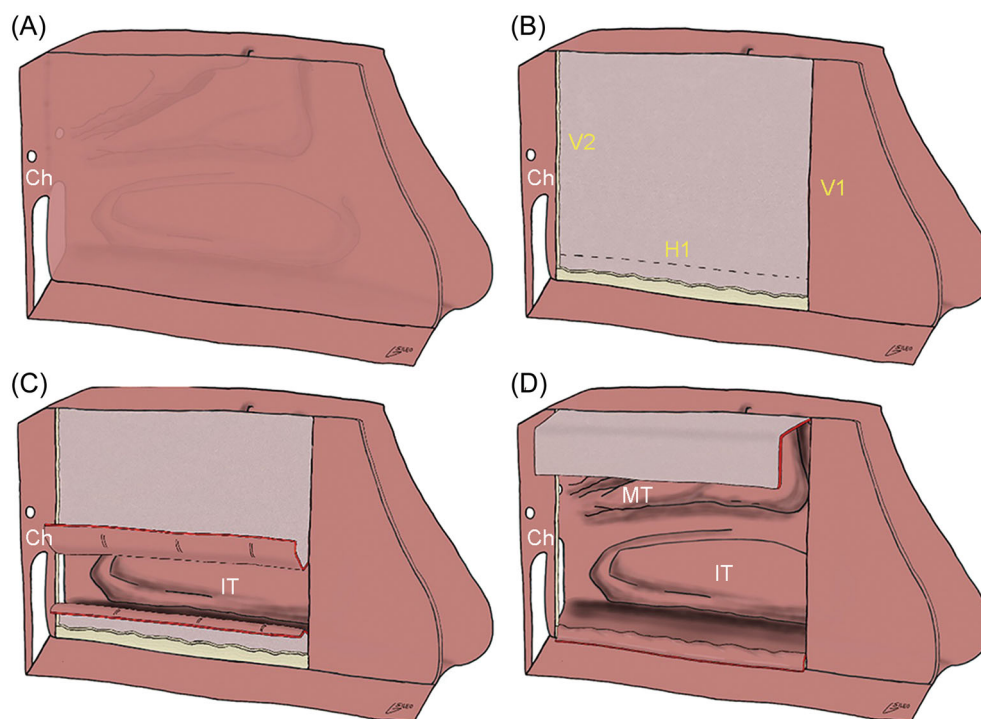


FIGURE 2 Drawing illustrating modified reverse septal flap (mRSF) harvesting. (A) Septal mucoperiosteum and mucoperichondrium on the contralateral side which is removed with cartilaginous part. (B) mRSF and flip-flap harvesting incisions. (C) Elevation of the harvested flaps. (D) In setting of the two flaps; the mRSF cover the exposed bone of the nasal floor and the flip-flap resurface the duraplasty. Ch, choana; H1, inferior horizontal incision connects inferiorly V1 and V2 above 1 cm from the nasal floor; IT, inferior turbinate; MT, middle turbinate; V1, vertical incision from the frontal beak to the nasal floor; V2, vertical incision from the sphenoidal planum to the nasal floor.

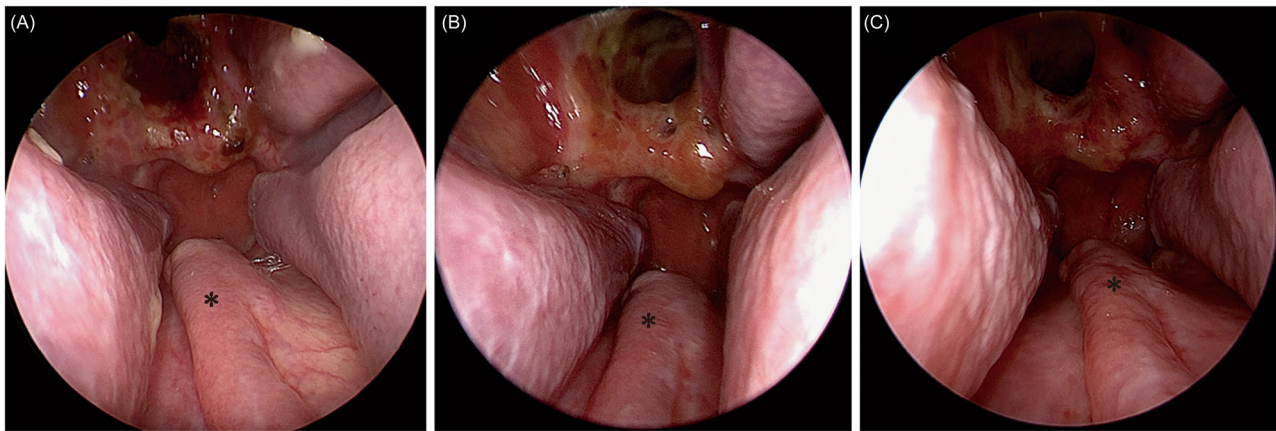


FIGURE 3 Endoscopic images of the nasal cavity performed at 1-month (A), 3-month (B), and 6-month (C) intervals. The images show rapid healing and integration of the reverse flap (black asterisk) already 1 month after surgery. The adjuvant radiotherapy treatment did not lead to worsening of the nasal crusts nor of the symptoms reported by the patient.

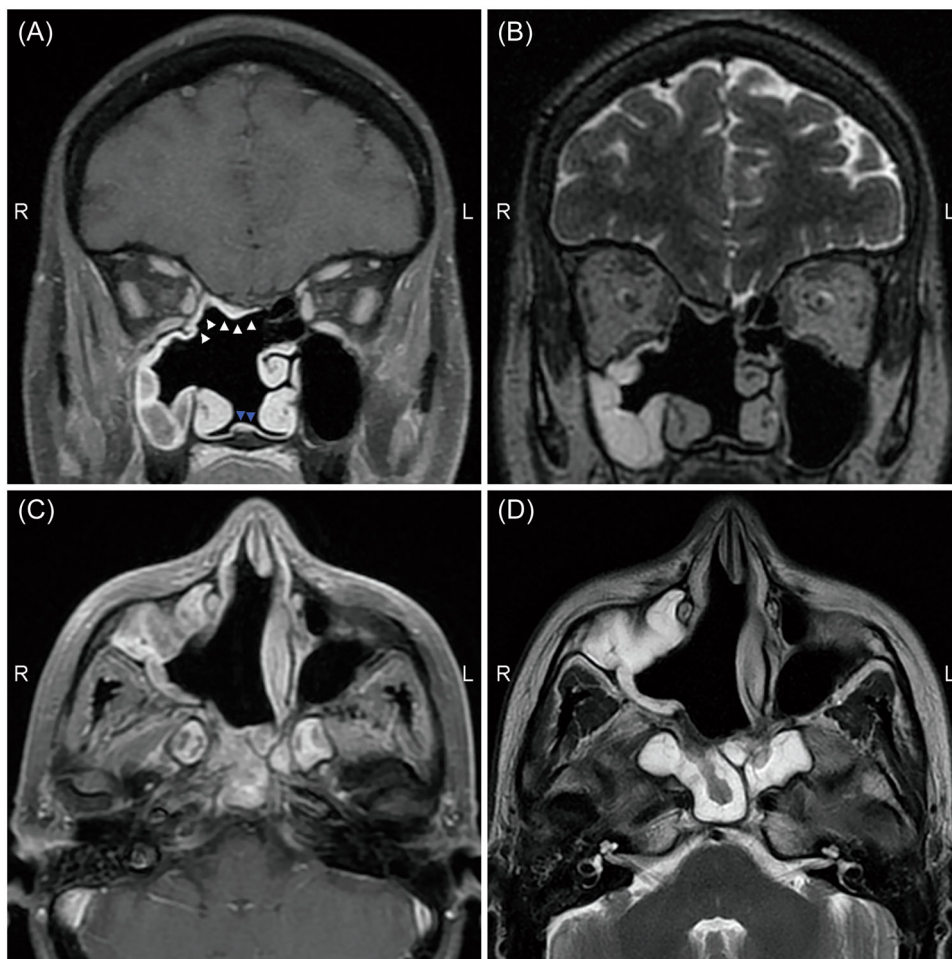


FIGURE 4 Postoperative contrast-enhanced T1-weighted and T2-weighted magnetic resonance imaging in coronal (A, C) and axial (B, D) view, performed 6 months after multimodal treatments, showed complete tumor removal without recurrence of disease. White arrows mark the septal flip flap of the anterior cranial fossa reconstruction; blue arrows mark the reverse septal flap.

CONCLUSION

This surgical technique is a simple but effective way to boost nasal healing after endoscopic endonasal surgery. It appears to be a viable option for nasal floor resurfacing after septal removal following a unilateral ERTC in well-selected cases. Larger case series with a longer follow-up are needed to validate these preliminary results.

AUTHOR CONTRIBUTIONS

Gianluca Dalfino, Andrea Ronchi, and Luca Volpi conceptualized and designed the document, collected and analyzed data and drafted the work. Giorgio Sileo has collected and analyzed the data, compiled the work and realized the figure of the surgical steps for the harvesting of the modified reverse septal flap. Maurizio Bignami conceptualized the surgical technique, coordinated the data collection and data analysis and critically revised the manuscript. All authors approved the final manuscript as submitted and agreed to be accountable for all aspects of the work.

ACKNOWLEDGMENTS

The authors have nothing to report.

CONFLICT OF INTEREST STATEMENT

The authors declare no conflict of interest.

DATA AVAILABILITY STATEMENT

Research data is not shared.

ETHICS STATEMENT

The authors have nothing to report.

ORCID

Gianluca Dalfino  <http://orcid.org/0000-0002-1380-4206>

REFERENCES

1. Castelnovo P, Turri-Zanoni M, Battaglia P, Antognoni P, Bossi P, Locatelli D. Sinonasal malignancies of anterior skull base. *Otolaryngol Clin North Am*. 2016;49:183-200.
2. Hadad G, Bassagasteguy L, Carrau RL, et al. A novel reconstructive technique after endoscopic expanded endonasal approaches: vascular pedicle nasoseptal flap. *Laryngoscope*. 2006;116:1882-1886.
3. Lechner M, Takahashi Y, Turri-Zanoni M, et al. Clinical outcomes, Kadish-INSICA staging and therapeutic targeting of somatostatin receptor 2 in olfactory neuroblastoma. *Eur J Cancer*. 2022;162:221-236.
4. Battaglia P, Turri-Zanoni M, De Bernardi F, et al. Septal flip flap per la ricostruzione del basicranio anteriore dopo resezione di tumori nasosinusali: risultati preliminari. *Acta Otorhinolaryngol Ital*. 2016;36:194-198.
5. Strober WA, Valappil B, Snyderman CH. Impact of reverse septal flap on morbidity of nasoseptal flap reconstruction of skull base defects. *Am J Rhinol Allergy*. 2023;37:470-475.

How to cite this article: Dalfino G, Ronchi A, Sileo G, Volpi L, Bignami M. Modified reverse septal flap: a surgical hint. *World J Otorhinolaryngol Head Neck Surg*. 2024;1-5.
[doi:10.1002/wjo2.173](https://doi.org/10.1002/wjo2.173)