

Review

From post-mortem practice to forensic insight. A review of craniotomy studies

Arianna Vanni^{a,b}, Roberta Fusco^{a,*}, Nicol Rossetti^a, Marta Licata^a

^a Department of Biotechnology and Life Science, University of Insubria, Via Jean Henry Dunant, 3, 21100, Varese, VA, Italy

^b Ph.D. Student in Clinical and Experimental Medicine and Medical Humanities, Department of Medicine and Surgery, University of Insubria, Via Guicciardini, 9, 21100, Varese, VA, Italy



ARTICLE INFO

Keywords:

Cut marks
Tool marks
Saw marks
Postmortem practices
Craniotomy
Skeletal remains

ABSTRACT

Craniotomies have played a significant role in both historical and contemporary post-mortem practices, including autopsy, anatomical dissection, embalming and surgical training. The differentiation of these procedures in osteoarchaeological contexts remains a complex challenge due to the overlap in techniques and the varying conditions of skeletal remains.

This review presents studies analyzing craniotomies on osteological material, focusing on cut mark morphology, tool mark characteristics and contextual evidence to distinguish post-mortem interventions.

The findings highlight the advancements in forensic methodologies applied to archaeological remains, emphasizing the integration of historical records and modern analytical techniques.

Future research should aim to incorporate experimental archaeology and interdisciplinary approaches to enhance interpretations of past medical procedures.

1. Introduction

Anatomical dissection and autopsy have historically been at the heart of medical practice, providing essential insights into human anatomy and pathology. While both practices share techniques such as craniotomies, their purposes diverge: in dissection, craniotomies serve educational and research purposes, offering a detailed understanding of the brain for medical training and scientific study.^{1–4} In forensic autopsy, they are indispensable for determining the cause of death, particularly in cases involving trauma or neurological conditions.^{3,4}

The forensic relevance of craniotomies extends beyond contemporary practice. Historical post-mortem examinations, including craniotomies performed in contexts of autopsy, dissection, embalming and surgical training, can provide unique insights into the evolution of medico-legal practices and medical education. Differentiating these practices poses a significant challenge due to the overlap in techniques and the contexts of discovery, which often present additional obstacles or challenges in interpreting the nature of the osteological material itself.

1.1. Historical overview

While the primary focus often falls on autopsy and dissection, various other post-mortem practices involving craniotomies have contributed to medical and forensic developments. These include embalming, surgical exercises on cadavers and the preparation of anatomical specimens for educational and museum purposes.³

Autopsy, as a medico-legal practice, emerged in antiquity⁵ but gained prominence during the Renaissance, when the systematic study of human anatomy began to flourish.^{1,3,6–9} Physicians performed autopsies not only to determine the cause of death but also to refine their understanding of pathology and anatomy.

During the 14th and 15th centuries, **anatomical dissections** became increasingly common in European universities, laying the groundwork for modern anatomical studies.^{1,3,5,7–9} These practices often required access to human cadavers, sometimes obtained under ethically questionable circumstances, such as grave robbing or the exploitation of marginalized individuals.^{7,10–12}

Embalming, rooted in ancient civilizations, was practiced to preserve the deceased.^{2,13} In European history, embalming became closely associated with the elite, serving both as a means of preserving the body for

* Corresponding author.

E-mail addresses: avanni@uninsubria.it (A. Vanni), roberta.fusco@uninsubria.it (R. Fusco), nicol.rossetti@uninsubria.it (N. Rossetti), marta.licata@uninsubria.it (M. Licata).

<https://doi.org/10.1016/j.jflm.2025.102894>

Received 6 March 2025; Received in revised form 7 May 2025; Accepted 9 May 2025

Available online 12 May 2025

1752-928X/© 2025 The Authors. Published by Elsevier Ltd. This is an open access article under the CC BY-NC-ND license (<http://creativecommons.org/licenses/by-nc-nd/4.0/>).

display during funerals and as a symbol of wealth and status.²

Surgical exercises on cadavers played a pivotal role in the professional development of surgeons, offering an opportunity to refine techniques critical for live patients.^{3,14}

Anatomical preparations created for schools of medicine, museums and other educational institutions served as a bridge between medical research and public education, preserving knowledge through meticulously crafted specimens.^{3,10,11}

1.2. Objective

This work is a structured narrative literature review. Its purpose is to synthesize current knowledge and methodologies used in the analysis of craniotomies on osteological material, with particular attention to how these have been interpreted in light of different post-mortem practices.

While other interventions, such as trepanations, are occasionally included, the focus is on evaluating how craniotomies have been analysed to differentiate post-mortem and peri-mortem practices, including autopsy, anatomical dissection, surgical exercises, embalming and the preparation of anatomical specimens.

By exploring the historical, methodological and scientific aspects of these practices, this review highlights the significant progress made in studying craniotomies, emphasizing their pivotal role in shaping our understanding of human anatomy and medical practices across history. Moreover, it underscores how this topic remains relevant and open to further investigation, driven by increasingly advanced techniques, larger osteological samples and the integration of historical sources and medico-legal studies to deepen interpretations.

2. Search methodology

For this review, articles were retrieved using five databases: PubMed, Scopus, ResearchGate, Academia and Google Scholar. These databases were selected because, when used in combination, they enable the identification of articles relevant to the topic by combining specific keywords and applying certain filters to refine the results (e.g., selecting only articles published in journals, articles in English, etc.).

Keyword combinations used for the searches are presented in Table 1. Below, the specific search strategies employed for each database are detailed.

- **PubMed:** the search was conducted using the “Advanced” section without applying thematic filters (“All Fields”). Keywords were entered separated by the operator “AND”.
- **Scopus:** the search was performed in the “Documents” section, within the “Search within Article title, Abstract, Keywords” field. Keywords were entered in quotation marks and separated by the operator “AND”, with no restrictions on the research field.
- **ResearchGate:** keywords were entered in quotation marks and separated by the operator “AND”. Exclusion criteria were then applied (see Section 2.1). The “Sort by relevance” filter was activated, and the first 10 results pages were reviewed.
- **Academia:** keywords were entered in quotation marks, separated by the operator “AND”. The “Sort by relevance” filter was applied, and the first 10 results pages were reviewed.
- **Google Scholar:** keywords were entered in quotation marks, separated by the operator “AND”. The default options, “Sort by relevance” and “Any type”, were retained and the first 10 pages of results were evaluated.

Titles and abstracts were reviewed as an initial screening step for each search. Relevant articles identified through this process were read in full and are presented in Table 1.

2.1. Inclusion and exclusion criteria

This literature review focuses exclusively on journal articles, with no restrictions on the publication date. Only articles written in English were included, provided they offered descriptive, comprehensive and detailed discussions, particularly on cases of craniotomies.

The selected studies emphasized the potential differentiation between post-mortem practices such as autopsy, dissection, medical training exercises and the preparation of anatomical specimens for study or museum purposes.

Articles were excluded if they did not meet the technical inclusion criteria outlined above, lacked references to the differentiation of post-mortem practices, or focused solely on a single technique for purposes unrelated to the scope of this review.

3. Search results

The search and screening process across the databases yielded 9 articles relevant to this review. The selection process followed the PRISMA 2020 guidelines for reviews based on database and register searches. A detailed flow diagram of the screening and selection process is shown in Fig. 1, which illustrates the number of records identified, screened, assessed for eligibility and included in the final review. This visualization is adapted from the “PRISMA 2020 flow diagram for new systematic reviews which included searches of databases and registers only” (available at: <https://www.prisma-statement.org/prisma-2020-flow-diagram>).

Table 1 presents the details of the selected articles and the searches conducted in each database. Fig. 2 provides a graphical summary of the search results, showing: (A) the number of relevant results for each keyword combination, further broken down by search platform, and (B) the total frequency of each article’s appearance across the databases, also categorized by platform.

4. Review

4.1. Brief Communication: Skeletal Evidence of Operations on Cadavers from Sens (Yonne, France) at the End of the XVth century. Frederique Valentin and Francesco d’Errico, 1995. American Journal of Physical Anthropology¹³

4.1.1. Results

The results were divided into cut marks (referring to those left by a thin blade during scalping) and saw marks (referring to those left by the blade of the instrument used for craniotomy).

The cut marks’ morphology and direction were described by cranial region. For the saw marks, the morphology of the incisions and cutting planes was first described, providing a general overview of the progression of these transverse cutting planes and their respective inclinations. The presence of flaking on the cranial plates, fractures in the occipital region and false starts were noted. The directionality of the cuts was then analysed, using indicators such as the “*variation of the orientation*” and the “*obliteration of a part of the anterior striae*”, which enabled the identification of three craniotomies performed clockwise and three counterclockwise. Lastly, the starting points of the craniotomies were discussed, noting that they were “*abundant on the occipital, present on the temporal, but rarely found on the frontal and the parietal*”.

The sequence of actions performed by the operator during the craniotomies was also reconstructed. It began with the removal of the scalp from the frontal to the occipital region, followed by the detachment of the epicranial muscles and concluded with the craniotomy itself. It is suggested that the head was likely positioned on its side at the beginning of the incision and then rotated as the cut progressed, ending in the occipital region. In some cases, the circumference was left incomplete, requiring a lever or percussion. Numerous changes in direction were also noted, likely intended to minimize damage to the brain during the

Table 1

Overview of the articles analyses, including site information, dating, material examined, and methodological approaches applied.

Articles	Citation frequency in databases	Site	Chronology	Aim/Scope	Osteological material	Analysis	Differentiation
<i>Valentin and d'Errico, 1995</i> ¹³	4 (1 PubMed, 2 Scopus, 1 Google Scholar)	Crypt of the chapel of the former Franciscan (or Cordelier) convent, Sens. France.	XIVth-XVIth century (archaeological dating)	To understand how post-mortem procedures were performed and to uncover their intended purpose.	13 cranial fragments with saw and cut marks were analysed, representing a minimum number of 9 individuals.	Sex, age, paleopathology. An experimental autopsy was performed, with the incisions analysed using transmitted light microscopy on nitrocellulose varnish replicas and scanning electron microscopy on resin replicas.	Embalment, autopsy, anatomical studies
<i>Dittmar and Mitchell, 2015</i> ¹	12 (5 Scopus, 7 Google Scholar)	Dissecting room in the Anatomy Department at the University of Cambridge. England.	1) Unpublished catalogue of the Anatomical Museum collections at the University of Cambridge. 2) The Duckworth Catalogue. Many crania in this sample have precise records of when they were added to the collection, all dating to before 1913.	The article aims to propose a set of criteria to assist in differentiating "investigative procedures" (primarily dissection and autopsy) when applied to osteoarchaeological material.	A total of 140 crania were selected for analysis from the preserved dissected human skeletal remains housed in the dissecting room of the Anatomy Department at the University of Cambridge. These specimens belong to a documented collection.	1) Historical manuals and surgical instruction texts consultation. 2) Study of a documented skeletal collection. Age (with the aid of historical records). The crania were examined macroscopically, with the locations of knife and saw marks recorded and digitized. Tool mark types were identified using techniques described by Symes et al. (2010). Additionally, the presence of coloured dyes applied to anatomical features on the bone surface and wax injections into hollow structures was documented.	Dissection, autopsy, teaching and museum specimens
<i>Giuffra et al., 2016</i> ²	6 (2 PubMed, 1 Scopus, 3 Google Scholar)	Crypt of the Basilica of San Lorenzo in Florence. Italy	16th–18th century	To study autopsy practices from an osteoarchaeological perspective, as documented within an aristocratic family.	25 individuals: 14 adults (10 males and 4 females), and in 11 non-adults; 13/25 have signs of autopsy and/or embalming practices	1) Macroscopic analysis of the subject, where possible, otherwise, radiological and palynological analysis. 2) Comparison with the historical-medical documentation of the Medici family.	Embalment, autopsy, dissection
<i>Flies et al., 2017</i> ³	1 (1 Google Scholar)	Street of Upsalagade, Copenhagen, intercepting a temporary cemetery from the Copenhagen Hospital for the Poor (CHP). Denmark	Written documents date the cemetery from 1842 to 1858	To present the material from this site exhibiting cut marks, and attempting to distinguish the specific practices to which these marks may be attributed.	Out of a total of 299 individuals, 52 (comprising complete skeletons or single bones) exhibited cut or sawn marks. The skeletal material consisted of both complete individuals and isolated or fragmented bones. 4 subjects with tool marks	Age, sex, paleopathology. Regarding the cuts, they were macroscopically analysed to identify signs of healing, then categorized based on 'post mortem surgical interventions', and finally assigned to specific tool categories.	Autopsy, dissection, anatomical specimens and surgical practice
<i>Scalise et al., 2018</i> ¹⁵	5 (1 Scopus, 4 Google Scholar)	Excavation related to the hospital of Forlì Campus. Italy	XVIIth-XVIIIth century (archaeological dating)	The aim is to study osteoarchaeological remains using forensic methodologies to interpret the cuts, in order to correlate them with specific practices.		Sex, age. Macroscopic observation of the cuts ('kerf walls and floors, breakaway spurs and notches, false starts, tooth hop, exit chipping, and orientation of striations'). Stereomicroscopic and SEM analysis of 9 casts of the cutting surfaces.	Dissection, preparation of anatomical specimens, surgical intervention
<i>Scheelen-Nováček et al., 2019</i> ¹⁶	8 (3 PubMed, 3 Scopus, 2 Google Scholar)	Blumenbach Skull Collection of the University of Göttingen, particularly the specimen donated by Baron Georg Thomas von Asch	The collection of Baron von Asch was donated between 1771 and 1806	Reassessment and scientific review of part of the cranial collection, with particular attention to signs of surgical and autopsy procedures, presenting in this article the most interesting aspects of the investigation.	63 skulls of the Baron von Asch donation	Age, sex, paleopathology, evaluation of taphonomic changes. Macroscopic techniques were employed, along with stereomicroscopic, endoscopic, and radiological investigations (X-rays). Additionally, forensic and medico-historical sources were consulted.	Surgical practices, autopsy

(continued on next page)

Table 1 (continued)

Articles	Citation frequency in databases	Site	Chronology	Aim/Scope	Osteological material	Analysis	Differentiation
Scianò et al., 2020 ¹⁷	28 (5 PubMed, 5 Scopus, 5 ResearchGate, 5 Academia, 8 Google Scholar)	Cemetery of the church of San Biagio, Ravenna, Italy	XVIIIth-XIXth century	Study of craniotomy, aiming to interpret and differentiate the origin and purpose of the cut.	Individual US-217	Sex, age, height (including osteometric measurements of the skull), paleopathology (using morphological and microscopic techniques).	Autopsy and surgical practice
Crozier et al., 2021 ¹⁸	17 (5 Scopus, 4 ResearchGate, 8 Google Scholar)	Canal Street, Aberdeen, Scotland.	1760 - 1860 (radiocarbon dating), Terminus ante quem: early 19th century (lead pipe - archaeological dating)	Study and interpret the bone sample, as well as examine its context of origin in order to place it within the history of the study and teaching of anatomy in Scotland.	84 fragments (MNI: 5 individuals (3 adults and 2 non-adults, possibly a total of 7 with 2 other non-adults)	Sex, age. Macroscopically: palaeopathological and taphonomic evaluation.	Autopsy, dissection, surgery, surgical training/practice
Vanni et al., 2024 ⁹	14 (5 Scopus, 3 ResearchGate, 6 Google Scholar)	Hypogeal cemetery of the church of Santa Maria Maggiore, Vercelli, Italy.	XVIIIth-XIXth century	Macroscopically study and use high-magnification photographs to examine the signs of craniotomies and cut marks, considering the context of the finds, in order to differentiate the post-mortem practices used and place these specimens within the historical context.	4 crania and 1 complete individual	Sex, age, evaluation of cut marks/false starts features as dips on the kerf floor, shape of kerf walls, bone islands, breakaway spurs, detachment of superficial bone lamellae, continuity of the cutting plane, colour of margins and presence of colour spots	Anatomical dissection, autopsy and preparation of educational specimen.

procedure.

Based on the morphology of the cuts, the instrument was identified as a saw with widely spaced teeth. A reassembled sample, which revealed a significant gap between the two cutting surfaces, further supported this conclusion.

4.1.2. Differentiation

Historical texts from the 14th to 15th centuries were consulted.

The hypothesis of embalming was considered first but partially refuted due to the following reasons.

- Craniotomies are present in women and young adolescents as well.
- All craniotomies display signs of scalping starting from the frontal bone, leaving visible marks. This would have been noticeable if the body was returned for a wake or funeral, although the use of head coverings suggested by historical sources cannot be ruled out.
- Historical sources do not mention specific care in preserving the brain during the cuts made for embalming.
- Macroscopically, no evidence of substances typically used for embalming was identified.

It has been suggested that autopsies should not be considered distinct from embalming, as it is impossible to differentiate between them based on the “operating technique or the burial context”.

Lastly, “*Anatomical studies*” were considered because there are records of physicians who were practicing. It is therefore plausible that dissections for scientific purposes were carried out privately. Notably, all the craniotomies show careful incisions aimed at avoiding damage to the brain, which aligns with behaviours or practices consistent with anatomical dissections.

4.1.3. Final hypothesis

Since all the skulls exhibit the same “*method of cutting and sawing*”, it has been suggested that these craniotomies could originate from a single operator or a specific “school”. Furthermore, these remains together may potentially be dated to the same period.

The practice most consistent with these cuts, the context and the nature of the remains appears to align with anatomical dissections conducted for study purposes.

4.1.4. Future perspectives

There is room for further investigation, including more precise dating and comparison with other collections.

4.2. A new method for identifying and differentiating human dissection and autopsy in archaeological human skeletal remains. Jenna M. Dittmar and Piers D. Mitchell, 2015. *Journal of Archaeological Science: Reports*¹

4.2.1. Results

For the “*historical literature analysis*” regarding craniotomies, manuals described similar procedures. However, to study the skull more comprehensively, craniotomies with cutting planes other than the horizontal one were reported, along with additional incisions (e.g., around the orbits), which are not typically performed in autopsies.

Various methodologies were described for colouring and preparation for museum purposes, including the resection of the mandible (e.g., to access the carotid artery).

The results of the cut marks were categorized into saw marks, knife marks and tool marks (the latter defined as “*made by either saws or knives*”) and further analysed by age groups.

- Tool marks: adult skulls 72/73; juvenile skulls (ages 1–20 years) 13/13; foetal skulls (premature–3 months) 29/54.

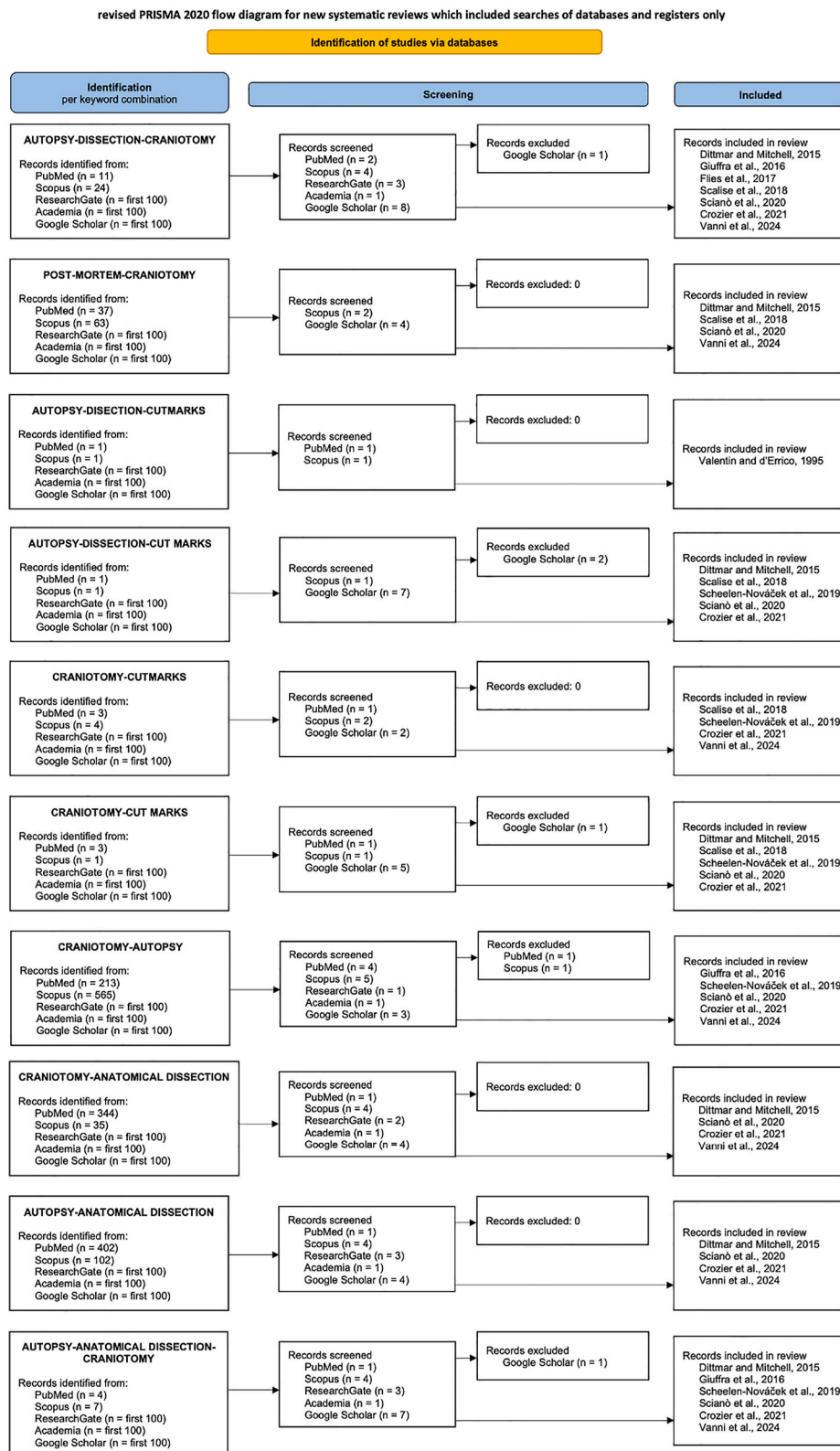


Fig. 1. Revised PRISMA 2020 flow diagram showing the identification, screening and inclusion process of the articles selected for this review (from <https://www.prisma-statement.org/prisma-2020-flow-diagram>).

- i. Craniotomies were found in 77/140 individuals. Among these, 62/77 were circumferential, 8/77 were cut along the sagittal plane, 1/77 along the coronal plane and 6/77 (all juveniles) displayed cuts across multiple planes.
- ii. Skulls without craniotomy: 63/140 individuals. Of these, 38/63 exhibited knife marks.
- iii. Coloured dyes were found on 21 skulls. Evidence of wax was identified on another 8.

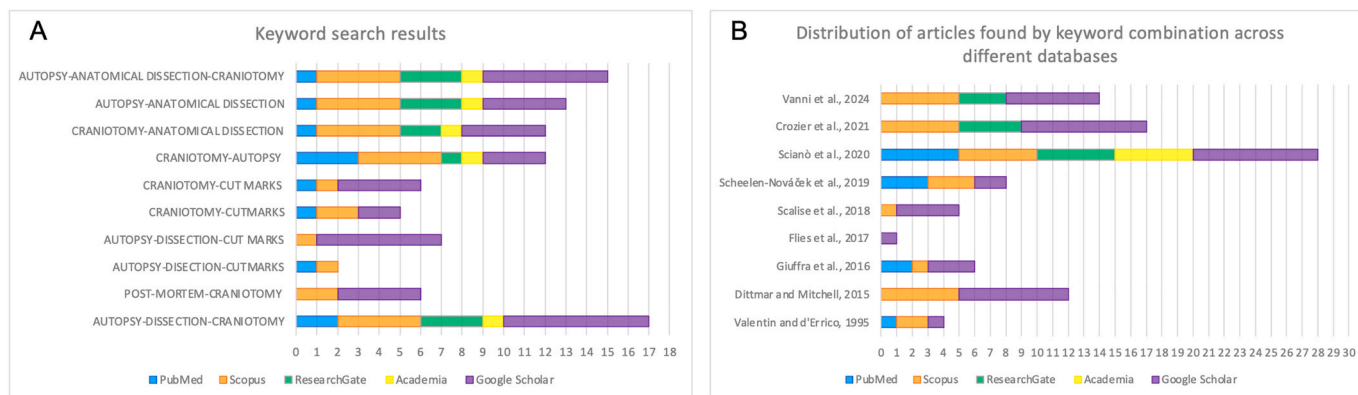


Fig. 2. Distribution of results by platform: (A) number of articles found for each keyword combination, categorized by database; (B) frequency of each article's appearance in the searches, broken down by database.

4.2.2. Differentiation

The practices of autopsy, dissection and the preparation of museum specimens can be differentiated as follows.

- i. The burial context is the first element that can guide the interpretation and differentiation of sharp-force trauma.
- ii. The presence of knife marks on skulls that were not subjected to craniotomy is a key criterion for identifying dissection aimed at preserving specimens for museum or educational purposes. In the discussion, attention was drawn to the presence of these dissected skulls lacking craniotomies, contrary to the standard protocols described in historical sources on medical practices. These specimens would not have been recognized as having undergone post-mortem procedures using standard differentiation methods.
- iii. The presence of wax casts and colour stains on the remains within the burial context is consistent with anatomical preparations deliberately placed in the grave.
- iv. According to historical sources, bodies used for dissections were exploited to the fullest extent for study and practice. This often led to the preservation of less perishable parts for later study, with a preference for dissecting areas prone to rapid decomposition. This practice may have resulted in the delayed burial of various body parts or the burial of non-matching parts in a single grave. This is another aspect to consider when differentiating dissection practices.
- v. The presence of animal bones in the same burial context has been identified as a differentiation criterion, as these bones were often used for comparative anatomy studies.

In addition to these criteria, [Table 1](#) presents other distinguishing features. The presence of circumferential craniotomy, sternotomy, or thoracotomy is common to both autopsy and dissection practices. However, craniotomies performed on planes other than the transverse, such as sagittal or coronal and the presence of knife marks without associated craniotomy, as well as the sawing of bodies into sections, have been identified as specific to dissection practices.

Regarding foetal skulls, only a minimal portion displayed evidence of craniotomy. The hypothesis for this category is that such practices were avoided due to the fragility of foetal bone tissue and the importance of these remains for study purposes. It has therefore been suggested that foetal remains underwent different treatment to preserve them as anatomical preparations.

4.2.3. Future perspectives

The authors ultimately urge caution when interpreting tool marks as evidence of dissection practices. Even though the marks they observed are not compatible with these interpretations, they recommend

including in the differential diagnosis factors such as “*trauma from warfare or interpersonal violence*” and “*taphonomic damage*”, particularly caused by rodent activity, root growth, or excavation-related disturbances to the burial context.

They also propose using microscopic techniques to conduct a detailed analysis of the blade's features and the instrument's characteristics to study tool marks.

4.3. Autoptic practices in 16th–18th century Florence: Skeletal evidences from the Medici family. Valentina Giuffra, Antonio Fornaciari, Simona Minozzi, Angelica Vitiello and Gino Fornaciari, 2016. *International Journal of Paleopathology*²

4.3.1. Results

This section is organized by family and presents the results of osteoarchaeological analyses. These include whether subjects exhibited macroscopic or radiographic evidence of cut marks related to craniotomies or thoracotomies and a comparison with historical sources.

In the family of Cosimo I, Giovanni delle Bande Nere and Garcia did not display any signs of autopsy practices, nor do written sources mention any such procedures. Maria Salviati, Eleonora of Toledo and Giovanni showed no evidence of autopsy, but historical sources indicate that the two women underwent autopsies, while Giovanni underwent an internal organ examination. Cosimo I, on the other hand, displayed evidence of craniotomy, which is confirmed by historical accounts documenting an autopsy to investigate his cause of death.

In the family of Francesco I, himself, Giovanna of Austria, and Don Filippino exhibited macroscopic evidence of autopsy. Francesco I and Giovanna showed signs of thoracotomy alone, confirmed by historical sources, while Don Filippino displayed only craniotomy, also supported by the records. Conversely, Princess Anna and an unidentified non-adult, referred to as Med 9, did not present any evidence of autopsy practices.

In the family of Ferdinando I, himself, Francesco, and Filippo were subjected to autopsy. Ferdinando exhibited only craniotomy, although historical sources generically mention autopsy practices. Prince Francesco displayed evidence of both thoracotomy and craniotomy, which is consistent with historical accounts, while Filippo exhibited thoracotomy, with sources referring to embalming practices corroborated by palynological analyses. Cristina of Lorraine and Cardinal Carlo both showed evidence of thoracotomy, though no mention of autopsy is made in the historical records for either.

Giangastone exhibited evidence of craniotomy, but the presence of soft tissues prevented confirmation of thoracotomy macroscopically. Historical records, however, indicate that he underwent both procedures. Additionally, two illegitimate sons of the family were found in the crypt. Anton Francesco Maria presented evidence of both craniotomy

and thoracotomy, while Gian Francesco Maria exhibited only craniotomy. Historical sources make no mention of necroscopic investigations for either individual. Among the other eight non-adult individuals examined, one displayed evidence of embalming practices.

4.3.2. Differentiation

In this case as well, the connection between autopsy practices and embalming is emphasized. The reasoning considers several factors. The first point considered was the noble status of the family, as historical sources indicate that wealthy families were known to be willing to pay for a medico-legal investigation into the cause of death. Second, it is noted that the physicians responsible for embalming procedures might have been interested in studying anatomy during the process. This overlap implies that autopsies were often conducted in parallel with embalming, making it difficult to draw a clear distinction between craniotomies and thoracotomies performed for one practice or the other.

4.3.3. Final hypothesis

While signs of autopsy practices were found in 13 individuals out of the 25 discovered, only 8 displayed signs of craniotomies, all of whom were male. This makes craniotomy appear to be an exclusive practice for males within the studied sample.

For non-adults (infants), no cuts were needed due to the non-fusion of cranial bones at that age and traces of chemicals used for embalming were found in the endocranium.

Finally, the different investigative or treatment methods applied to the subjects are attributed to the use of varying techniques by different court physicians who succeeded one another over time.

4.4. Skeletal material from the Cemetery of the 19th Century Copenhagen Hospital for the Poor: Autopsies, Surgical Training and Anatomical Specimens. M.J. Flies, S.D. Winther, N. Lynnerup, 2017. International Journal of Osteoarchaeology³

4.4.1. Results

Of the 52 individuals, 50 were adults (>18 years) and 2 were non-adults, aged 4 and 8 years. Among all 52 individuals, 30 exhibited tool marks (which in this case include not only saw and knife marks, but also drill marks) on the skull, and 20 of these (including the two non-adults) displayed craniotomy (not limited to the transverse plane).

No signs of healing or related pathologies were present in any of the remains. Additionally, there were no significant differences in cutting patterns based on sex.

Next, examples are presented for the categories of post-mortem practices. Regarding craniotomies, examples are provided for dissection, with one craniotomy along the coronal plane (also involving the mandible) and for the creation of anatomical preparations an example of a subject whose maxilla was removed from the rest of the skull.

4.4.2. Differentiation

Although it is emphasized that differentiating practices in archaeology is complicated, if not impossible, further criteria are suggested for consideration. In addition to those proposed by Dittmar and Mitchell (2015), the level of district fragmentation is also added as an important factor.

Regarding autopsy and dissection, it is concluded that it is impossible to differentiate between the two, since, although they serve different purposes, both are used for the study of anatomy and are therefore intrinsically indistinguishable.

Anatomical preparations are derived from dissections.

As for surgical experimentation, in the absence of signs of healing, it is impossible to determine whether cuts (such as amputations or trepanations) occurred before or after death. However, when remains show multiple signs, they should be considered as surgical exercises on the corpse, due to the unnecessary nature of those additional incisions and the fact that operations prior to the advent of anaesthesia had to be quick

and effective.

4.4.3. Final hypothesis

The article provides an overview of the osteological material from the cemetery site associated with the Copenhagen Hospital for the Poor. While no conclusions are drawn regarding the differences in the practices, cases corresponding to the four practices considered are presented.

4.4.4. Future perspectives

The cemetery has not been fully excavated, so it cannot be ruled out that matching parts of those studied so far may be in the remaining unexplored area of the site.

4.5. Saw Mark Analysis of Three Cases of Amputation and a Craniotomy from the Seventeenth and Eighteenth Centuries Hospital Necropolis of Forlì Campus (Forlì, Italy). Lucia M. Scalise, Antonino Vazzana, Mirko Traversari, Giorgio Gruppioni, Carla Figus, Eugenio Bortolini, Salvatore A. Apicella, Flavia Fiorillo, Federico Taverni, Stefano De Carolis, Flora Fiorini, Thomas Böni, Frank J Rühli, Stefano Benazzi and Francesco M. Galassi, 2018. Collegium Antropologicum.¹⁵

4.5.1. Results

The excavation revealed 271 single burials and six ossuaries, but in this article are presented in detail some cases with evidence of cut marks.

Cases 1–3 refer to amputations.

Case 4, on the other hand, is a horizontal craniotomy involving the frontal and parietal bones. The striae are described as continuously changing direction to follow the natural curvature of the skull. False starts and marked porosity on the frontal bone near the bregma were also noted.

4.5.2. Differentiation

Amputations. From the direction of the cuts and the presence of spurs and notches, the direction of the cut and the position of the operator were reconstructed. To determine the instrument used, the characteristics of the cuts were analysed. Case 2 showed no pathological signs indicative of the cut, but it was incomplete/fractured. Case 3, on the other hand, displays a perimortem fracture across the entire diameter of the ulna, linked to an osteotomy of the humerus.

Regarding the craniotomy, it is reiterated that the cut follows the natural curvature of the skull, changing direction to avoid damaging the brain. The occipital bone was not severed, but it is possible that the opening of the lambdoid suture was used for scalp removal. The analysis of the cuts also led to the hypothesis that a linear hand-powered saw was used.

4.5.3. Final hypothesis

The article presents four cases of osteoarchaeological findings that showed signs of cuts/osteotomies.

For the first case of amputation, the spurs resulting from the osteotomy were not cut, and there were no associated pathologies. Therefore, it was hypothesized that the subject may have died during the procedure or that the body was used for medical practice.

In case 2, since it is not a complete district, it is not excluded that the missing part was preserved as an anatomical specimen, possibly resulting from dissection.

Case 3 is likely to have undergone a surgical operation.

Regarding the craniotomy in case 4, it is hypothesized that the porotic reaction on the frontal bone could have been the reason for the anatomical investigation and autopsy.

4.6. *Vestiges of autopsies and surgical procedures in the “Baron von Asch” skulls of the Blumenbach Skull Collection in Göttingen. Kristina Scheelen-Nováček, Katharina Stötzel and Michael Schultz, 2019. Anthropologischer Anzeiger. Journal of Biological and Clinical Anthropology*¹⁶

4.6.1. Results

All 63 skulls in the collection were positively identified, with the majority belonging to male subjects (mainly in the 20–29.9 age range) and most were not from burial contexts (only a few specimens showed surface deterioration and discoloration).

16 out of the 63 skulls exhibited striations consistent with what is referred to as “incision” on the ectocranium. 10/63 skulls showed signs of craniotomy (8 males and 2 females). Of these, 8/10 exhibited a craniotomy that could be described as transverse (6 out of 8 had an oblique cut, while 2 out of 8 had a more horizontal cut). 6/10 had a relatively low cutting plane (just above the supraorbital margin), 2/10 had a cutting plane a few centimeters higher, and the remaining 2/10 showed craniotomy along the median sagittal plane.

The results also present two skulls with signs of perforations. In the first case, incision marks were visible on the external table, porosity was seen on the internal table and the cutting edges showed no remodelling. The second skull displayed signs of remodelling and had a surface described as “highly irregular, scarred and bulgy”.

The cutting surfaces allowed the authors to observe that the direction of the cuts was modified to follow the cranial curvature.

7/63 skulls retained soft tissue fragments adhered to the bone surface.

4.6.2. Differentiation

The skulls that retained soft tissue fragments were hypothesized to be anatomical specimens, although it was not possible to determine whether this treatment occurred before or after they became part of the collection. However, the authors do not exclude the possibility that these fragments are remnants of defleshing in areas that are particularly difficult to dissect.

The cut marks (from thin and superficial blades) in this sample were not found only on skulls that had undergone craniotomy, so they were not attributed specifically to practices like dissection or autopsy, but rather more generally to defleshing.

The authors hypothesized that a hand saw and frequently a metal rim were used for the cuts, although they report two cases where the cuts were made freehand.

The “skull of a Turk (collection no. 516)” features a craniotomy that started from the occipital and was adjusted after the circumference was completed. This case is considered a craniotomy for autopsy purposes due to the skill in aligning the cutting planes.

Regarding trepanations, the following cases are reported.

- *Tatar (collection no. 577)*. This skull shows a trepanation corresponding to the middle meningeal artery, with four thin striations on the ectocranium, probably caused by the displacement of soft tissues. The endocranial surface shows “new bone formations”, which the authors associate with scurvy and “increased brain pressure”. The individual does not appear to have survived the procedure, which the authors speculate was a surgical intervention.
- *Russian (collection no. 460)*. This skull shows trepanation margins that had begun to heal. In addition to signs of this surgical procedure, the individual exhibited “severe, extended inflammation of the scalp”, which was not directly related to the surgical procedure. Near the holes, there were also depressions/scars consistent with blunt force trauma of a violent origin.

4.6.3. Final hypothesis

The disproportion between male and female subjects in the collection led to two considerations: 1) that it might reflect the nature of the

collection, not originating from a single burial site or specific population and 2) that this male predominance might be linked to a military context, a connection that aligns with the military surgeon role of the Baron. However, the authors remain cautious, stating that it is not possible to determine whether this gender imbalance was intentional for the purpose of the collection.

The skulls in the collection that exhibit craniotomies might have been used as anatomical study specimens, given that the cuts with changes in direction and the specific planes of incision could have facilitated the removal of the brain without causing damage. However, it is important to also consider historical sources and the morphologies of these cuts, as discrepancies were found between the initial cataloguing and the remains that have come down to us, showing instances where craniotomies were performed after the skull was already part of the collection.

The collection also includes individuals who underwent surgery, such as those with trepanations, highlighting the surgeon’s skill in operating along the sagittal suture (as seen in Russian case no. 460).

4.6.4. Future perspectives

The completion of the analysis of the correspondence between von Asch and Blumenbach is planned for the future, which could provide new insights and clarifications regarding the remains.

4.7. *Autopsy or anatomical dissection: evidence of a craniotomy in a 17th–eighteenth century burial site (Ravenna, Italy). Filippo Scianò, Nicoletta Zedda, Jessica Mongillo, Emanuela Gualdi-Russo and Barbara Bramanti, 2021. Forensic Science, Medicine and Pathology*¹⁷

4.7.1. Results

The individual was a woman aged between 35 and 50 years old who exhibited active cribra orbitalia, a transverse craniotomy, an injury to the frontal region and an osteolytic lesion also in the frontal area.

Microscopic observations, based on the morphological characteristics of the cuts—including false starts, break-away spurs and chipping—led to the conclusion that the tool used for the craniotomy was a rip saw. As for the injury to the frontal region, the tool responsible could not be determined, but it showed no signs of remodelling, suggesting it was peri-mortem (“at or around the time of death”).

4.7.2. Differentiation

The craniotomy was classified as part of a “scalping procedure of a surgical nature” performed with a surgical saw and other tools such as scalpels and surgical blades.

Following the criteria proposed by Dittmar and Mitchell (2015), it was hypothesized that autopsy was the post-mortem procedure performed on the woman.

4.7.3. Final hypothesis

It is not ruled out that the injury to the frontal region could be related to a surgical decompression operation, suggesting the woman may have died during the operation and then been subjected to an autopsy as part of an “anatomic-pathological investigation”.

4.8. *Osteoarchaeological evidence for medical dissection in 18th to 19th century Aberdeen, Scotland. Rebecca Crozier, Alison Cameron, Bruce Mann, Elizabeth Ashcroft and Rachel Wood, 2021. Post-Medieval Archaeology*¹⁸

4.8.1. Results

This section is divided into three paragraphs: the first addresses the calculation of the Number of Identified Specimens (NISIP) and the Minimum Number of Individuals (MNI), the second discusses pathologies and traumas, and the third presents the results from chemical analyses.

Regarding “pathological lesions and trauma”, the difficulty in

identifying pathologies is highlighted due to the fragmentary nature of the material, but three specimens showed some distinctive features. Briefly, Cranium A exhibited signs of mastoiditis on the right temporal bone, and Individual 6 (a non-adult) showed cribra orbitalia along with a “doughnut-shaped” injury on the frontal region, which was also associated with more superficial striations. Regarding Individual 2, an adult, it consisted of the reconstruction of six cranial fragments that displayed both taphonomic damage, such as substance loss, and a transverse cut from the occipital to the frontal, once again associated with additional cut marks on the surface.

4.8.2. Differentiation

The observations concluded that both Individual 2 and Individual 6 had undergone “*perimortem* [...] *damage*”.

Starting with Individual 2, this individual exhibited a circumferential craniotomy and, based on historical sources, it may have undergone an autopsy or dissection. However, this procedure on the skull was not documented in surgical manuals. Thus, once again, we face the challenge of differentiating between autopsy and dissection, a task complicated by the fact that during times of cadaver shortages for practice, families were persuaded to allow the autopsy of their loved ones, which often had the purpose of dissection. As a result, these two practices could have been intertwined.

Individual 6, on the other hand, had undergone manual trepanation and soft tissue displacement around the trepanation site. The procedure was incomplete, leading to doubts about whether it was a surgical operation in which the patient died or a surgical practice on a cadaver.

4.8.3. Final hypothesis

For Individual 2, no definitive hypothesis is proposed between autopsy and dissection due to the fragmentary nature of the remains, which may be missing segments or fragments that could provide additional striations or saw marks to support a conclusion.

Given the incomplete trepanation morphology of Individual 6, the hypothesis is that it was a cadaveric practice exercise. Considering other contexts with osteological material showing cut marks, it is also speculated that the individual was lying supine on the table during the procedure.

The historical context highlights how the early to mid-19th century was a period of scientific excitement but also controversy, such as the practice of resurrectionists. The hypotheses raised regarding the collection of remains, and which cannot be definitively concluded, suggest that they could have resulted from the disaggregation of bodies following dissections, one or more private clandestine collections, or even from a student who illegally obtained cadavers for practice. However, all of this points to dissection as the most plausible hypothesis.

Finally, historical sources reveal a scarcity of “official” bodies sent to Aberdeen, making it plausible that these remains could have come from the “work” of resurrectionists.

4.9. *Autopsy or anatomical dissection? Comparative analysis of an osteoarchaeological sample from an 18-19th century hypogeal cemetery (northern Italy). Arianna Vanni, Roberta Fusco, Chiara Tesi and Marta Licata, 2024. Journal of Archaeological Science: Reports*⁹

4.9.1. Results

First, a table showing the features used to distinguish autopsy, dissection and the preparation of museum or educational specimens, as deduced from literature research, is presented. Subsequently, the results of the macroscopic observation of the cuts and their characteristics are presented.

From FU11, the skull of Individual 1 belonged to an adult male and exhibited a transverse craniotomy, for which only a few casts were made due to the fragility of the specimen. Observations of the cuts revealed a near-total absence of striations, eburnated surfaces and a colour different from the rest of the circumferential cut surface. Additionally,

the absence of cut marks on the surface of the cranial ovoid was assessed. Regarding Individual 2, the skull belonged to an adult female and also exhibited a horizontal craniotomy with smooth surfaces, lacking noticeable striations and showing a colour distinct from the rest of the specimen. Both of these skulls displayed pencil and/or pastel marks and brownish-red stains.

From FU12, Individual 1 was an adult male, and multiple casts were made from the skull, showing the profiles of the walls and floor of the cuts. The craniotomy was transverse and the cut surface in this case displayed striation marks and a colour consistent with the rest of the specimen. Skull 23 belonged to an adult male, and although few areas were preserved, a transverse craniotomy was noted, with surfaces matching the colour of the others.

V-FU17-1 is an adult male, and the entire skeleton is preserved. Regarding the skull, it shows signs of a transverse craniotomy with an imprecise circumference, featuring continuous changes in direction and spurs. The surface displays striations and a uniform colour consistent with the rest of the skull. This individual also had an elongated styloid process on the left temporal bone.

4.9.2. Differentiation

For II-FU11-1, the osteotomy was likely performed using an electric saw with an alternating blade and a guide may have been used for the cut. The cut appears to have been made in a counterclockwise direction, after the skull had already been skeletonized, as suggested by the colour and the absence of cut marks on the cranial ovoid for skinning.

Skull II-FU11-2 also exhibited modern cutting characteristics, with the use of an electric saw suggested based on the surface of the cut and the ectocranium, as well as the detachment of part of the inner table. In this case, it is hypothesized that the craniotomy was performed following a previously drawn pencil line as a guide. The cutting motion in this instance likely followed a counterclockwise direction.

For III-FU12-23, only the cutting direction (counterclockwise) and the peri-mortem chronology of the cut were hypothesized, while for III-FU12-1, a more detailed investigation was possible. The craniotomy on this specimen was likely performed with a manual saw with alternating blades (a conclusion that required consultation of period medical tool research and consideration of the possible chronology of the specimen, predating the use of electric instruments). In this case, the movement was both counterclockwise and clockwise in different strokes and repetitions. Based on the study of the cutting surfaces and the visible cut marks on the ectocranium, a peri-mortem cut is also hypothesized for this individual.

The craniotomy of V-FU17-1 was likely performed with a handsaw, and the movement and orientation were modified several times, possibly to avoid damaging the brain. The line of the cut is imprecise, suggesting that no metal guide was used, and again, both clockwise and counterclockwise cutting motions are hypothesized. Based on the cut marks on the ectocranium and the colour of the cutting surfaces, the hypothesis is that the cut occurred peri-mortem.

4.9.3. Final hypothesis

After morphological analysis, the osteological sample was divided into three categories, also considering the context in which each specimen was found.

- i. Specimens for education. The two skulls from FU11 were categorized here due to the modern nature of the cuts, their chronology and the presence of pencil marks, writing and colours. The context of their discovery, although disturbed by anthropogenic activities, suggests they were used for study purposes.
- ii. Anatomical dissection. The specimens from FU12 were hypothesized to belong to this category, not only because of the study of the cuts but also due to the manner in which the skulls were deposited and arranged in the ossuary box where they were found.

- iii. Autopsy. V-FU17-1 may have undergone this post-mortem procedure, as no further tool marks were found on the post-cranial skeleton and the elongation of the styloid process of the left temporal bone was considered a possible reason for the craniotomy.

4.9.4. Future perspectives

Future research will aim to refine the chronological framework of the osteological material, considering the complexity introduced by the transfer of burials from the old church.

5. Discussion

The articles included in this review were selected based on their adherence to the criteria of differentiation among primarily post-mortem practices involving craniotomies, focusing on the analysis of tool/cut marks and their implications for differentiation. While numerous studies on osteological material with evidence of craniotomy have been published (e.g., Signoli et al., 1997; Anderson, 2002; Bugaj et al., 2013; Kausmally, 2015; Dittmar and Mitchell, 2018),^{11,19-22} this review has focused on a selection of articles that delve deeply into specific aspects aligned with the criteria of this research. Many other valuable works in the literature, though addressing related topics, primarily concentrate on cultural, historical, or anthropological dimensions rather than on advanced methods of differentiation or detailed technical analyses of craniotomies.

Additionally, some studies may not have been included due to their absence in the bibliographic search conducted across various platforms or the keywords utilized in this research. Although these works contribute valuable insights by reinforcing previously established studies, they fall outside the specific scope of this review.

Among the studies analysed, a clear distinction emerges between those primarily aimed at differentiating post-mortem practices and those that extended their focus to include the characteristics of cut marks and the tools used. Many articles focused more on the differentiation of practices, without studying or presenting results concerning the morphology of the cuts and, therefore, the study of the instruments used.^{1-3,16,18} In such cases, the morphology of the cuts, the type of blade and detailed morphological investigations of the tool marks were often omitted. While this aligns with the primary objectives of these studies, it leaves certain morphological/forensic aspects of the craniotomies underexplored or not evaluated as details useful to the article's purpose.

Conversely, other studies incorporated a comprehensive analysis of tool/cut marks, emphasizing their characteristics/morphology to identify the instruments used.^{9,13,15,17} The work of Symes et al. serves as a cornerstone in this regard, as it established methodologies for distinguishing tool marks and associating them with specific instruments.^{23,24} Subsequent studies have built on this foundation, with more recent research demonstrating the potential for integrating forensic approaches with archaeological contexts to achieve more precise interpretations of the techniques and tools employed.^{1,9,15,17}

An emerging avenue of exploration involves the comparison of cut marks in archaeological material with those produced by modern tools used in osteotomies and beyond, in both common and medical contexts (e.g., Jenna M. Dittmar 2015; Luísa Nogueira 2016; Caroline Bernardi 2021; Melissa Menschel 2021; Dupouy 2023).²⁵⁻²⁹ While promising, this approach presents a critical limitation: most current studies rely on modern instrumentation, which may not accurately reflect the tools available in historical contexts.⁹ This raises concerns about the reliability of such comparisons when used as standalone evidence. To overcome this limitation, it is essential to consider broader contextual parameters, such as the chronology of the remains, the surrounding burial context, and other associated tool marks.⁹ Factors like the colour and texture of the cut surfaces, which can reveal additional information about the timing and nature of the intervention, also warrant further attention.

The integration of historical sources and forensic methodologies presents a valuable opportunity for advancing the study of craniotomies on osteoarchaeological material, which is crucial for understanding medical and anatomical practices. By combining traditional methods with innovative approaches, such as experimental archaeology and comparative forensic analysis, future research can address existing gaps and refine our understanding of both the technical and cultural dimensions of these practices.

It is important to note that this review does not aim to assess or judge the individual works of the studies presented, as they cover a temporal span of 30 years during which methodologies and technologies have evolved. New research has emerged that has contributed to the differentiation and study of cut marks, such as the discovery of archaeological sites that have brought new finds to the literature. Therefore, the goal is not to suggest a specific best practice to follow when studying these contexts and craniotomies, but rather to present the evolution and current state of research in this field, which intertwines numerous disciplines such as archaeology, paleopathology, medical history, biological anthropology and forensic medicine.

6. Conclusion

This review has highlighted how different studies have contributed complementarily to improving methodologies for differentiating post-mortem practices in history, but it has also shown that the exploration of cut mark characteristics has not always been one of the features studied in all these works. Furthermore, an important limitation has emerged regarding the use of modern tools in comparison to historical practices. While promising, this approach needs a more contextualized method to overcome the risks of misinterpretation.

Despite progress, much remains to be done to fully integrate historical sources with modern forensic techniques to refine our understanding of surgical practices and the social dynamics surrounding them. This field of research, despite the uncertainties of the available evidence, continues to offer significant opportunities to enrich our knowledge of history of medicine, its techniques and the associated material culture.

Finally, it is important to emphasize that this review does not aim to judge individual studies, but rather to trace the evolution of methodologies and techniques applied to the study of craniotomies and the current state of the art in an ever-evolving field, which thrives on the interaction between various disciplinary and methodological domains.

CRedit authorship contribution statement

Arianna Vanni: Conceptualization, Investigation, Data curation, Formal analysis, Writing – original draft. **Roberta Fusco:** Conceptualization, Writing – review & editing. **Nicol Rossetti:** Data curation, Writing – review & editing. **Marta Licata:** Project administrator, Supervision, Writing – review & editing.

Funding

This research did not receive any specific grant from funding agencies in the public, commercial, or not-for-profit sectors.

Declaration of competing interest

The authors declare that they have no known competing financial interests or personal relationships that could have appeared to influence the work reported in this paper.

References

- Dittmar JM, Mitchell PD. A new method for identifying and differentiating human dissection and autopsy in archaeological human skeletal remains. *J Archaeol Sci Rep.* 2015;3:73-79. <https://doi.org/10.1016/J.JASREP.2015.05.019>.

2. Giuffra V, Fornaciari A, Minozzi S, Vitiello A, Fornaciari G. Autoptic practices in 16th–18th century Florence: skeletal evidences from the Medici family. *Int J Paleopathol.* 2016;15:21–30. <https://doi.org/10.1016/J.IJPP.2016.09.004>.
3. Flies MJ, Winther SD, Lynnerup N. Skeletal material from the cemetery of the 19th century Copenhagen hospital for the poor: autopsies, surgical training and anatomical specimens. *Int J Osteoarchaeol.* 2017;27(6):1012–1021. <https://doi.org/10.1002/OA.2612>.
4. Nystrom KC. Introduction. In: Nystrom KC, ed. *Bioarchaeology and Social Theory*. Berlin, DE: Springer; 2017:1–22. https://doi.org/10.1007/978-3-319-26836-1_1.
5. Cecchetto G, Bajanowski T, Cecchi R, et al. Back to the Future - Part I. The medico-legal autopsy from ancient civilization to the post-genomic era. *Int J Legal Med.* 2017;131(4):1069–1083. <https://doi.org/10.1007/s00414-017-1584-8/FIGURES/6>.
6. King LS, Meehan MC. A history of the autopsy. A review. *Am J Pathol.* 1973;73(2):514.
7. Park K. The criminal and the saintly body: autopsy and dissection in renaissance Italy. *Renaiss Q.* 1994;47(1):1–33. <https://doi.org/10.2307/2863109>.
8. Charlier P, Huynh-Charlier I, Poupon J, et al. Special report: anatomical pathology A glimpse into the early origins of medieval anatomy through the oldest conserved human dissection (Western Europe, 13th c. A.D.). *Arch Med Sci.* 2014;10(2):366–373. <https://doi.org/10.5114/AOMS.2013.33331>.
9. Vanni A, Fusco R, Tesi C, Licata M. Autopsy or anatomical dissection? Comparative analysis of an osteoarchaeological sample from an 18–19th century hypogeal cemetery (northern Italy). *J Archaeol Sci Rep.* 2024;54, 104418. <https://doi.org/10.1016/j.jasrep.2024.104418>.
10. Mitchell P. *Anatomical Dissection in Enlightenment England and beyond: Autopsy, Pathology and Display*. London, UK: Routledge; 2012.
11. Kausmally T. William Hewson (1739–1774) and the Craven Street Anatomy School – Anatomical teaching in the 18th century. , UCL (University College London) . *Doctoral thesis* Published online July 28, 2015. Available at: <https://discovery.ucl.ac.uk/id/eprint/1470030/>.
12. Brenna CTA. Post-mortem pedagogy: a brief history of the practice of anatomical dissection. *Rambam Maimonides Med J.* 2021;12(1), e0008. <https://doi.org/10.5041/RMMJ.10423>.
13. Valentin F, d'Errico F. Skeletal evidence of operations on cadavers from Sens (Yonne, France) at the end of the XVTH century. *Am J Phys Anthropol.* 1995;98(3):375–390. <https://doi.org/10.1002/AJPA.1330980310>.
14. Western AG, Bekvalac J. Digital radiography and historical contextualisation of the 19th century modified human skeletal remains from the Worcester Royal Infirmary, England. *Int J Paleopathol.* 2015;10:58–73. <https://doi.org/10.1016/J.IJPP.2015.05.002>.
15. Scalise LM, Vazzana A, Traversari M, et al. Sawmark analysis of three cases of amputation and a craniotomy from the seventeenth and eighteenth centuries hospital necropolis of forlì campus (forlì, Italy). *Coll Antropol.* 2018;42(3):211–222.
16. Scheelen-Nováček K, Stötzl K, Schultz M. Vestiges of autopsies and surgical procedures in the “Baron von Asch” skulls of the Blumenbach Skull Collection in Göttingen. *Anthropol Anzeiger.* 2019;76(3):259–273. <https://doi.org/10.1127/ANTHRANZ/2019/0886>.
17. Scianò F, Zedda N, Mongillo J, Gualdi-Russo E, Bramanti B. Autopsy or anatomical dissection: evidence of a craniotomy in a 17th–eighteenth century burial site (Ravenna, Italy). *Forensic Sci Med Pathol.* 2021;17(1):157–160. <https://doi.org/10.1007/s12024-020-00285-6/TABLES/1>.
18. Crozier R, Cameron A, Mann B, Ashcroft E, Wood R. Osteoarchaeological evidence for medical dissection in 18th to 19th century Aberdeen, Scotland. *Postmediev Archaeol.* 2021;55(2):159–175. <https://doi.org/10.1080/00794236.2021.1972584>.
19. Signoli M, Léonetti G, Champsaur P, Brunet C, Dutour O. Mise en évidence d'une autopsie crânienne réalisée pendant la Grande Peste de Marseille (1720–1722). *Compt Rendus Acad Sci III Sci Vie.* 1997;320(7):575–580. [https://doi.org/10.1016/S0764-4469\(97\)84713-0](https://doi.org/10.1016/S0764-4469(97)84713-0).
20. Anderson T. A 19th century post-mortem specimen from Deal, Kent. *Int J Osteoarchaeol.* 2002;12(3):216–219. <https://doi.org/10.1002/OA.597>.
21. Bugaj U, Novak M, Trzeciński M. Skeletal evidence of a post-mortem examination from the 18th/19th century Radom, central Poland. *Int J Paleopathol.* 2013;3(4):310–314. <https://doi.org/10.1016/J.IJPP.2013.06.002>.
22. Dittmar JM, Mitchell PD. Equality after death: the dissection of the female body for anatomical education in nineteenth-century england. *Bioarchaeol Int.* 2018;2(4):283–294. <https://doi.org/10.5744/BI.2019.1002>.
23. Symes S. Morphology of saw marks in Human Bone: identification of class characteristics. Doctoral Dissertation, University of Tennessee. Published online May 1, 1992. Available at: https://trace.tennessee.edu/utk_graddiss/1253.
24. Symes SA, Chapman EN, Rainwater CW, Cabo LL, Myster SMT. Knife and saw toolmark analysis in bone: a manual designed for the examination of criminal mutilation and dismemberment. Published online 2010. Available at: <https://www.ojp.gov/pdffiles1/nij/grants/232227.pdf>.
25. Dittmar JM, Erickson D, Caffell A. The comparison and application of silicone casting material for trauma analysis on well preserved archaeological skeletal remains. *J Archaeol Sci Rep.* 2015;4:559–564. <https://doi.org/10.1016/J.JASREP.2015.10.008>.
26. Nogueira L, Quatrehomme G, Rallon C, Adalian P, Alunni V. Saw marks in bones: a study of 170 experimental false start lesions. *Forensic Sci Int.* 2016;268:123–130. <https://doi.org/10.1016/J.FORSIINT.2016.09.018>.
27. Bernardi C, Nogueira L, Orange F, Carle GF, Alunni V, Quatrehomme G. The stereomicroscope and scanning electron microscope comparison of false starts bones produced by an oscillating autopsy saw. *Forensic Sci Int.* 2021;324, 110816. <https://doi.org/10.1016/J.FORSIINT.2021.110816>.
28. Menschel M, Pokines JT, Reinecke G. Correlation between saw blade width and kerf width. *J Forensic Sci.* 2021;66(1):25–43. <https://doi.org/10.1111/1556-4029.14556>.
29. Dupouy DLM, Bolton MS, Berry TP, Raymond J, Meakin GE. Saw marks in bone: a preliminary empirical study to inform decision making and best practice. *Forensic Sci Int.* 2023;353, 111857. <https://doi.org/10.1016/J.FORSIINT.2023.111857>.