

LETTER TO THE EDITOR

Tirbanibulin 1% real-world use in 679 actinic keratoses patients during warm season (SUMM-AK study)

Dear Editor,

Tirbanibulin 1% ointment is a topical field therapy approved for actinic keratoses (AKs) of the face and scalp, administered through a concise 5-day regimen with minimal local skin reactions (LSRs).¹ Although field therapies are often deferred during warmer months, concerns regarding ultraviolet (UV) exposure and treatment tolerability lack systematic validation in real-world settings. We conducted a retrospective multicenter study across 33 dermatology units in Italy, including 679 adult patients treated with tirbanibulin between April and September 2024. The study aimed to evaluate efficacy, tolerability and patient acceptability under conditions of increased ambient UV exposure. Efficacy outcomes included clearance rates and the Actinic Keratosis Area and Severity Index (AKASI).² The rationale for this investigation stemmed from current European recommendations supporting field-directed therapy and from the field-cancerization concept, which recognizes that lesion-targeted treatments may miss subclinical disease at risk of malignant transformation.^{3,4} Managing AKs requires the balance of efficacy and tolerability, which

becomes more challenging during summer months when higher UV exposure may exacerbate LSRs and reduce adherence.^{3,4} Several topical AK therapies induce local inflammation, photosensitivity or irritation, limiting their applicability during sunny periods.⁵ Phase 3 clinical trials established tirbanibulin's efficacy and safety under controlled conditions,¹ while independent real-world studies have confirmed significant reductions in AKASI scores and high patient acceptability.⁶⁻⁹ The feasibility of tirbanibulin treatment during warmer months is further supported by its lack of photoallergic or phototoxic potential.¹⁰

In our cohort, the mean patient age was 74.9 ± 9.7 years, with men representing 70.8% of cases and 77.6% reporting long-standing AK (>1 year). Lesions were predominantly located on the face (61.8%) and scalp (31.8%), with a smaller proportion affecting the upper chest and hands, confirming the treatment's versatility across sun-exposed areas. Adherence was complete (100%), suggesting that the short, well-tolerated regimen is easily manageable even under conditions of elevated temperature and UV exposure. Treatment outcomes were favourable (Figure 1a; Table 1). In our cohort

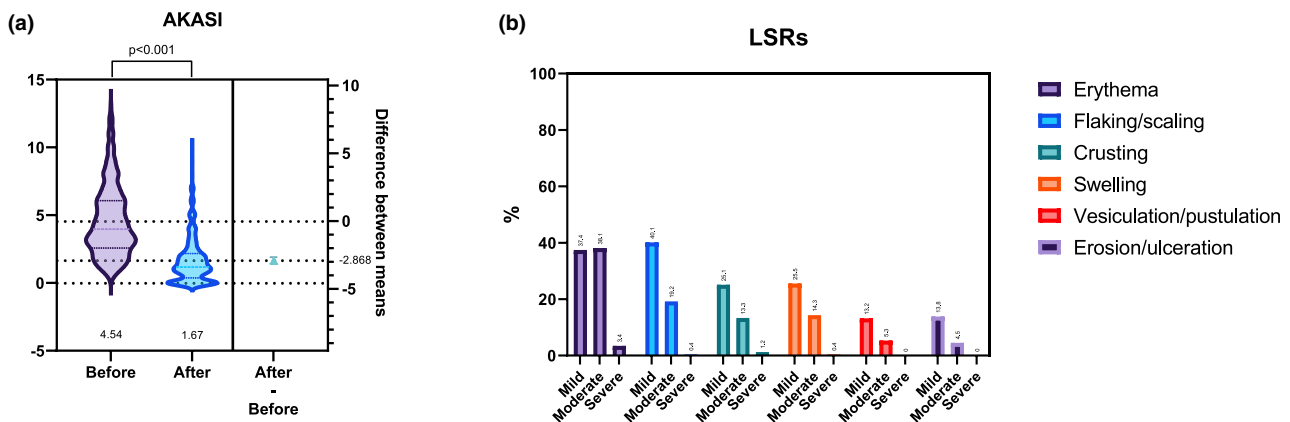


FIGURE 1 Clinical efficacy and local skin reactions (LSRs) following tirbanibulin 1% ointment for the treatment of actinic keratoses (AKs) during the warm season (SUMM-AK Study). (a) Violin plots showing AKASI (Actinic Keratosis Area and Severity Index) scores before and after treatment, with a significant mean decrease of -2.869 points ($p < 0.001$), indicating marked clinical improvement. (b) Frequency of mild LSRs, moderate LSRs, and severe LSRs, shown for the total population. The most frequent reactions were mild erythema, flaking/scaling and crusting. Moderate events were less common, and severe LSRs were rare across all subtypes, with no cases of severe flaking/scaling, swelling, vesication/pustulation or erosion/ulceration observed.

This is an open access article under the terms of the [Creative Commons Attribution-NonCommercial-NoDerivs](https://creativecommons.org/licenses/by/4.0/) License, which permits use and distribution in any medium, provided the original work is properly cited, the use is non-commercial and no modifications or adaptations are made.

© 2025 The Author(s). *Journal of the European Academy of Dermatology and Venereology* published by John Wiley & Sons Ltd on behalf of European Academy of Dermatology and Venereology.

TABLE 1 Clinical efficacy, photodamage improvement and satisfaction outcomes after tirbanibulin 1% treatment.

Outcome	Total (n = 679)	p-Value
	198 (29.2%)	-
≥75% response	474 (69.7%)	-
Mean ΔAKASI (%)	-2.87 (-63.2%)	<0.001
Photodamage improvement	206 (30.5%)	-
Patient satisfaction ≥3/4	539 (79.4%)	-
Clinician satisfaction ≥3/4	564 (83.1%)	-

69.7% of patients attained at least a 75% reduction in lesion burden. The mean AKASI score decreased from 4.54 to 1.67 ($\Delta -2.87$; -63.2% , $p < 0.001$), and visible photodamage improved in 30.5% of cases. Because AKASI is a head-specific measure and can be influenced by untreated areas, complete clearance within the 25 cm² treated zone may not correspond to an AKASI of 0.² Tolerability remained favourable despite summer exposure (Figure 1b). Most LSRs were mild or moderate; grade ≥3 reactions occurred in 11.9% of patients, with no grade 4 events or treatment discontinuations. Erythema was the most frequent reaction, followed by scaling and crusting. Patient and clinician satisfaction were high, 79.4% and 83.1%, respectively, rated ≥3 out of 4; and satisfaction scores correlated positively with clinical response and inversely, though weakly, with LSR severity. These results, derived from the largest real-world series conducted during the warm season, are consistent with pivotal trials¹ and independent studies demonstrating meaningful AKASI improvements and the practicality of the five-day regimen.⁶⁻⁸ The absence of photoallergic or phototoxic effects, coupled with a reassuring safety profile under maximal-use conditions, supports both the pharmacologic and biophysical rationale for summertime application.⁵⁻¹⁰ Limitations include the retrospective design, non-standardized follow-up and variable UV exposure. Nevertheless, the consistency of findings across endpoints reinforces their external validity.

In conclusion, tirbanibulin 1% ointment represents an effective, well-tolerated and innovative field therapy for AK, with a short regimen that fosters adherence and maintains safety even during periods of high UV exposure. These results endorse tirbanibulin as a compelling therapeutic option throughout the year, including the warmer months. Future prospective studies should further refine follow-up protocols and evaluate the long-term durability of clinical response.

KEYWORDS

actinic keratosis, effectiveness, real-world, safety, tirbanibulin, warm season

FUNDING INFORMATION

None.

CONFLICT OF INTEREST STATEMENT

M. Ardigo has received consulting fees from Pierre Fabre and has participated in lectures, presentations and advisory

boards for Almirall, Kyowa Kirin, Pierre Fabre, Recordati Rare Diseases and Cantabria Labs. L. Atzori has participated in advisory boards, lectures, presentations and received support for attending meetings from AbbVie, Amgen, Sanofi, LEO Pharma, Pfizer, Eli Lilly, J&J, BMS, Novartis and UCB. R. Balestri has received support for attending meetings from Lilly, AbbVie, Amgen and Novartis. S. Barruscotti has participated in presentations/lectures for L'Oreal. M. Bruni has participated in presentations/lectures for Almirall, AbbVie and Novartis. S. Caccavale has received consulting fees from Boehringer Ingelheim, and has participated in lectures/presentations for AbbVie, Novartis, Pfizer, J&J, Almirall and LEO Pharma, and received support for attending meetings from Galderma and Eli Lilly. A. Carugno has received payment or honoraria for lectures/presentations from Almirall, UCB, J&J and Novartis, and has participated in advisory boards for Almirall, AbbVie, BMS, Sanofi, LEO Pharma, UCB and Boehringer Ingelheim; he has also received support for attending meetings from Almirall, Sanofi, AbbVie and Novartis. G. Ciccarese has received consulting fees from Almirall and support for attending meetings from Pierre Fabre. G. Dal Bello has participated in presentations/lectures for Almirall. P. Danese has received grants or contracts from Sanofi, LEO Pharma and Almirall and support for attending meetings from Sanofi, LEO Pharma, Almirall and AbbVie. L. Germi has received consulting fees from LEO Pharma and AbbVie and has participated in lectures and presentations for Novartis and advisory boards for AbbVie and Almirall. S. Giacalone has received payment or honoraria for lectures from LEO Pharma, AbbVie, Almirall, Sanofi, UCB and Novartis, and has participated in advisory boards for Almirall. R. Giuffrida has received payment or honoraria for lectures and presentations from Pierre Fabre. G. Nazzaro has received payment or honoraria for lectures from Novartis, Giuliani Pharma, L'Oreal, IDI Farmaceutici and Almirall. M. Valenti has received payment or honoraria for lectures and presentations from Sanofi, Sun Pharma, Almirall, AbbVie, Novartis, UCB, Boehringer Ingelheim, LEO Pharma, Eli Lilly, Difa Cooper and Janssen, support for attending meetings from Sanofi, Almirall, AbbVie, Novartis, Janssen, LEO Pharma, UCB and Eli Lilly, and has participated in advisory boards for Almirall and UCB. E. Zavattaro has received consulting fees from Active Pharma Group and support for attending meetings from the Ganassini Institute and Sanofi-Regeneron. All other authors declare no conflicts of interest.

DATA AVAILABILITY STATEMENT





















The data that support the findings of this study are available from the corresponding author upon reasonable request.

ETHICAL APPROVAL

The commencement of the study was formally notified to the Institutional Ethics Committee of Varese (notification n° 82/2025). The study was conducted according to the ethical principles outlined in the Declaration of Helsinki and in compliance with applicable privacy regulations, including Regulation (EU) 2016/679 (GDPR).

ETHICS STATEMENT

The patients in this manuscript have given written informed consent for the publication of their case details.

A. Carugno¹ 
 G. Nazzaro^{2,3}
 L. Argnani⁴
 F. Bellinato⁵ 
 E. Zappia⁶
 M. V. Masala⁷
 G. Dal Bello⁸
 M. Valenti^{9,10}
 G. Addari¹¹
 G. Ciccicarese¹² 
 M. Bruni¹³
 E. Trovato¹⁴ 
 G. Paolino¹⁵ 
 R. Balestri¹⁶
 A. D'Arino¹⁷
 C. Magnoni¹⁸
 E. Zavattaro¹⁹ 
 G. Toni²⁰
 R. Giuffrida²¹ 
 A. Verdelli²² 
 S. Caccavale²³ 
 A. Villani²⁴
 S. Giacalone²⁵ 
 S. Recalcati²⁶ 
 S. Barruscotti^{27,28} 
 S. Bighetti²⁹ 
 L. Bettolini²⁹ 
 G. Fiorillo³⁰
 L. Germi³¹
 S. Fazio³²
 S. D. Infusino¹⁶
 L. Eibenschutz¹⁷
 A. Cesari³³
 M. Dragotto¹⁴ 
 G. B. M. Zolo³⁴
 P. Savoia¹⁹ 
 I. Zalaudek³⁵
 E. Sala³⁵
 E. Errichetti³⁶
 S. R. Mercuri¹⁵
 M. Esposito¹³
 C. Foti³⁷
 L. Atzori¹¹ 
 M. Ardigo^{9,10}
 P. Danese⁸
 S. Ribero⁶ 
 P. Gisondi⁵ 
 A. V. Marzano^{2,3} 
 N. Zerbinati³⁸

¹Department of Medicine and Surgery, University of Insubria, Varese, Italy












- ²SC Dermatologia, Fondazione IRCCS Ca' Granda Ospedale Maggiore Policlinico, Milan, Italy
³Dipartimento di Fisiopatologia e Dei Trapianti, Università degli Studi di Milano, Milan, Italy
⁴Dipartimento di Scienze Mediche e Chirurgiche, Università di Bologna, Bologna, Italy
⁵Section of Dermatology and Venereology, Department of Medicine, University of Verona, Verona, Italy
⁶Department of Medical Sciences, Clinic of Dermatology, University of Turin, Turin, Italy
⁷Dermatology Unit, Poliambulatorio ASL Nuoro, Nuoro, Italy
⁸Section of Dermatology, Department of Medicine, ASST di Mantova, Mantova, Italy
⁹Dermatology Unit, IRCCS Humanitas Research Hospital, Milan, Italy
¹⁰Department of Biomedical Sciences, Humanitas University, Milan, Italy
¹¹Dermatology Clinic, Department of Medical Sciences and Public Health, University of Cagliari, Cagliari, Italy
¹²Section of Dermatology, Department of Medical and Surgical Sciences, University of Foggia, Foggia, Italy
¹³Department of Biotechnological and Applied Clinical Sciences, University of LAquila, LAquila, Italy
¹⁴Dermatology Unit, Department of Medical, Surgical and Neurological Sciences, University of Siena, Siena, Italy
¹⁵Unit of Dermatology, IRCCS Ospedale San Raffaele, Milan, Italy
¹⁶Division of Dermatology, APSS – Unità Operativa Multizonale – Trento e Rovereto, Trento e Rovereto, Italy
¹⁷Oncologic and Preventive Dermatology Unit, San Gallicano Dermatological Institute-IRCCS, Rome, Italy
¹⁸Dipartimento di Scienze Mediche e Chirurgiche Materno-Infantili e Dell'adulto, Università Degli Studi di Modena e Reggio Emilia, Modena, Italy
¹⁹Dermatology Unit, Department of Health Sciences (DiSS), School of Medicine, Università del Piemonte Orientale (UPO), Novara, Italy
²⁰Section of Dermatology and Infectious Diseases, Department of Medical Sciences, University of Ferrara, Ferrara, Italy
²¹Department of Clinical and Experimental Medicine, Dermatology, University of Messina, Messina, Italy
²²Department of Health Sciences, Rare Skin Diseases Unit, P.O. Piero Palagi, Azienda USL Toscana Centro, ERN-SKIN Member, University of Florence, Florence, Italy
²³Dermatology Unit, University of Campania L. Vanvitelli, Naples, Italy
²⁴Section of Dermatology – Department of Clinical Medicine and Surgery, University of Naples Federico II, Naples, Italy
²⁵Institute of Dermatology, ASST Valle Olona, Ospedale Sant'Antonio Abate, Gallarate, Italy










- ²⁶Dermatology Unit, ASST Lecco, Alessandro Manzoni Hospital, Lecco, Italy
- ²⁷Department of Clinical-Surgical, Diagnostic and Pediatric Sciences, University of Pavia, Pavia, Italy
- ²⁸Dermatology Clinic, Fondazione IRCCS Policlinico San Matteo, Pavia, Italy
- ²⁹Dermatology Department, University of Brescia, ASST Spedali Civili di Brescia, Brescia, Italy
- ³⁰Dermatology Unit, St. Anna Hospital, ASST Lariana, Como, Italy
- ³¹Department of Dermatology, San Bortolo Hospital, Vicenza, Italy
- ³²Azienda Sanitaria Ligure 5 Spezzino, La Spezia, Italy
- ³³Struttura Complessa di Dermatologia, Azienda Ospedaliera Universitaria Policlinico di Modena, Modena, Italy
- ³⁴Dermatology Unit, Poliambulatorio ASL Sassari, Sassari, Italy
- ³⁵Department of Dermatology and Venereology, University of Trieste, Trieste, Italy
- ³⁶Institute of Dermatology, Department of Medicine, University of Udine, Udine, Italy
- ³⁷Department of Precision and Regenerative Medicine and Ionian Area, Unit of Dermatology, University of Bari Aldo Moro, Bari, Italy
- ³⁸Department of Medicine and Technology Innovation (DiMIT), University of Insubria, Varese, Italy

Correspondence

A. Carugno, Department of Medicine and Surgery, University of Insubria, 21100 Varese, Italy.
Email: andrea.carugno@uninsubria.it

ORCID

A. Carugno  <https://orcid.org/0000-0002-8231-2205>
 F. Bellinato  <https://orcid.org/0000-0002-6163-6921>
 G. Ciccarese  <https://orcid.org/0000-0001-8363-0195>
 E. Trovato  <https://orcid.org/0000-0001-8301-9206>
 G. Paolino  <https://orcid.org/0000-0002-3032-2217>
 E. Zavattaro  <https://orcid.org/0000-0003-4537-3014>
 R. Giuffrida  <https://orcid.org/0000-0002-5492-3033>
 A. Verdelli  <https://orcid.org/0000-0003-1982-888X>
 S. Caccavale  <https://orcid.org/0000-0001-7433-9283>
 S. Giacalone  <https://orcid.org/0000-0003-0464-3356>
 S. Recalcati  <https://orcid.org/0000-0001-5709-6689>

S. Barruscotti  <https://orcid.org/0000-0002-9572-4575>
 S. Bighetti  <https://orcid.org/0009-0006-2781-6909>
 L. Bettolini  <https://orcid.org/0000-0003-4374-802X>
 M. Dragotto  <https://orcid.org/0009-0006-9441-3923>
 P. Savoia  <https://orcid.org/0000-0002-1636-8411>
 L. Atzori  <https://orcid.org/0000-0002-8105-1402>
 S. Ribero  <https://orcid.org/0000-0002-0098-1406>
 P. Gisondi  <https://orcid.org/0000-0002-1777-9001>
 A. V. Marzano  <https://orcid.org/0000-0002-8160-4169>

REFERENCES

1. Blauvelt A, Kempers S, Lain E, Schlesinger T, Tyring S, Forman S, et al. Phase 3 trials of tirbanibulin ointment for actinic keratosis. *N Engl J Med*. 2021;384(6):512–20.
2. Dirschka T, Pellacani G, Micali G, Malvey J, Stratigos AJ, Casari A, et al. A proposed scoring system for assessing the severity of actinic keratosis on the head: actinic keratosis area and severity index. *J Eur Acad Dermatol Venereol*. 2017;31(8):1295–302.
3. Willenbrink TJ, Ruiz ES, Cornejo CM, Schmults CD, Arron ST, Jambusaria-Pahlajani A. Field cancerization: definition, epidemiology, risk factors, and outcomes. *J Am Acad Dermatol*. 2020;83(3):709–17.
4. Christensen SR. Recent advances in field cancerization and management of multiple cutaneous squamous cell carcinomas. *F1000Res*. 2018;7:F1000 Faculty Rev-690.
5. Kandolf L, Peris K, Malvey J, Mosterd K, Heppt MV, Fargnoli MC, et al. European consensus-based interdisciplinary guideline for diagnosis, treatment and prevention of actinic keratoses, epithelial UV-induced dysplasia and field cancerization on behalf of European Association of Dermato-Oncology, European dermatology forum, European academy of dermatology and venereology and Union of Medical Specialists (union Européenne des Médecins Spécialistes). *J Eur Acad Dermatol Venereol*. 2024;38(6):1024–47.
6. Kirchberger MC, Gfesser M, Erdmann M, Schliep S, Berking C, Heppt MV. Tirbanibulin 1% ointment significantly reduces the actinic keratosis area and severity index in patients with actinic keratosis: results from a real-world study. *J Clin Med*. 2023;12(14):4837.
7. Nazzaro G, Carugno A, Bortoluzzi P, Buffon S, Astrua C, Zappia E, et al. Efficacy and tolerability of tirbanibulin 1% ointment in the treatment of cancerization field: a real-life Italian multicenter observational study of 250 patients. *Int J Dermatol*. 2024;63(11):1566–74.
8. Li Pomi F, Vaccaro M, Pallio G, Rottura M, Irrera N, Borgia F. Tirbanibulin 1% ointment for actinic keratosis: results from a real-life study. *Medicina (Kaunas)*. 2024;60(2):225.
9. Campione E, Riviaccio A, Gaeta Shumak R, Costanza G, Cosio T, Lambiase S, et al. Preliminary evidence of efficacy, safety, and treatment satisfaction with Tirbanibulin 1% ointment: a clinical perspective on actinic Keratoses. *Pharmaceuticals (Basel)*. 2023;16(12):1686.
10. Dosik J, Cutler DL, Fang J, Padullés L. Contact sensitization and phototoxic and photoallergic potential of tirbanibulin 1% ointment in healthy volunteers. *JID Innov*. 2022;3(2):100170.