

Letter to the Editor

Letters to the Editor will be published, if suitable, as space permits. They should not exceed 1000 words (typed double-spaced) in length and may be subject to editing or abridgment.

Hypertension and Intrapericardial Paraganglioma: An Exceptional Presentation of Multiple Endocrine Neoplasia Type IIA Syndrome

To the Editor:

Paracardiac paragangliomas are very rare. A catecholamine-producing intrapericardial paraganglioma has never been described previously in the context of multiple endocrine neoplasia (MEN) IIA syndrome.^{1,2} We report the case of a patient with MEN IIA syndrome and secondary hypertension caused by functioning paraganglioma exceptionally located intrapericardially.

A 34-year-old woman presented with recent episodes of headache, palpitation, and flushing. For several months she had arterial hypertension controlled by ramipril; however, she reported high blood pressure spikes (180/90 mm Hg). Moreover, her sister was diagnosed with medullary thyroid cancer. Examination of the patient's neck demonstrated a small lump in the left thyroid lobe. Aspiration cytology of the nodule (1 cm) revealed a medullary thyroid carcinoma cell pattern. Thyrocalcitonin serum level was high (217.6 pg/mL; normal: <18 pg/mL), whereas calcium, thyroid-stimulating hormone, T₃, and T₄ levels were normal. A MEN syndrome was suspected, and additional exams were performed. Very high 24-hour urine normetanephrine level (4132 μ g/24 hours; normal: 162–527 μ g/24 hours) and vanilmandelic acid level (16.2 mg/24 hours; normal: 1–6.7 mg/24 hours) were found. Imaging studies were done to localize the suspected catecholamine-secreting tumor. Computed tomography scan of the chest demonstrated a contrast-enhanced 55-mm intrapericardial mass below the left atrium roof (Figure A and B). Intense ¹²³I-metaiodobenzylguanidine uptake concentrated solely in the thoracic mass (Figure C), supporting the diagnosis

of intrapericardial functioning paraganglioma without metastases. Mutation of the proto-oncogene RET C618S was documented in the patient and in 5 of her family members (2 children, 1 sister, 1 uncle, and 1 cousin), confirming the diagnosis of MEN type IIA syndrome. Surgical resection of the intrapericardial tumor was carried out. At induction of general anesthesia, the patient had a hypertensive crisis (blood pressure: 210/100 mm Hg) and intraoperatively required multiple doses of phentolamine and labetalol. The tumor was approached by right thoracotomy and was resected without cardiopulmonary bypass. The resected specimen presented as a 45×55-mm pseudocapsulated oval mass, with cut surface showing multiple gray-tan nodules and hemorrhagic areas (Figure D). Pathology revealed a paraganglioma with a nesting pattern. Immunohistochemistry was positive for chromogranin A and protein S-100, as well as for tyrosine-hydroxylase, dopamine β -hydroxylase, and met-enkephalin. The tumor was negative for calcitonin and phenylethanolamine *N*-methyl transferase.

The patient became rapidly well after surgery and no longer had hypertension. On postoperative day 4 her urine normetanephrine level was normal (167 μ g/24 hours). After recovery from thoracotomy, total thyroidectomy was performed, and histology documented medullary thyroid carcinoma positive for calcitonin and chromogranin A, confirming the MEN II A syndrome. At follow-up after 9 months from paraganglioma resection the patient is well, without symptoms.

Extra-adrenal tumors producing catecholamines are called paragangliomas. Two histological types are described, chromaffin paragangliomas, usually producing catecholamines and causing hypertension, and nonchromaffin tumors, which are called chemodectomas.³

Extra-adrenal pheochromocytomas most commonly originate in the abdominal superior para-aortic region, between the dia-

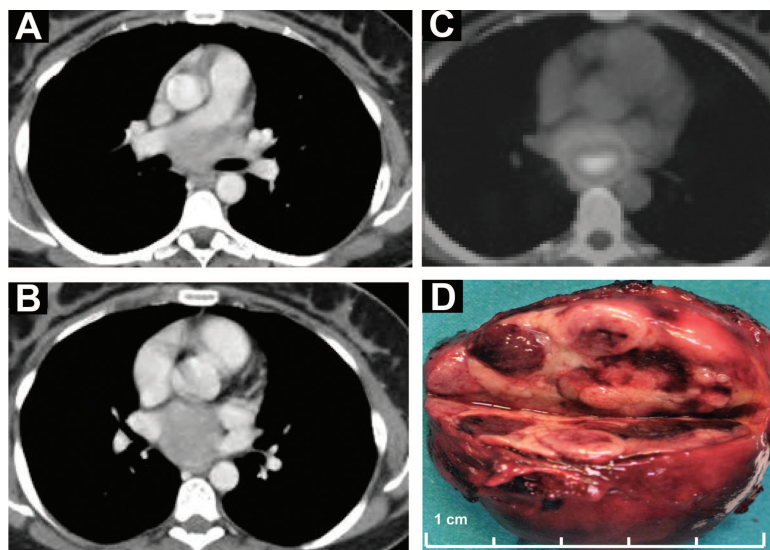


Figure. A and B, Chest computed tomography, showing a contrast-enhanced 55-mm mass located between the pulmonary artery and the roof of the left atrium. C, ¹²³I-metaiodobenzylguanidine chest scan, with evidence of high tracer uptake at middle mediastinum level. D, Cut surface of resected specimen (45×55 mm pseudocapsulated oval mass) showing multiple nodules and hemorrhagic areas.

phragm and the lower renal poles, frequently in the organ of Zuckerkindl.⁴ Only ≈2% of paragangliomas are located within the chest, more frequently in the posterior mediastinum and less frequently within the lungs or in the esophageal wall. Intrapericardial and intracardiac paragangliomas are very rare, usually arising from the left atrial wall or from the interatrial septum,⁵ and approximately half of them have been associated with signs or symptoms of excess catecholamine secretion.

Catecholamine-secreting tumors in the MEN IIA syndrome are usually located in the adrenal glands. They have never been described previously within the pericardium.

Disclosures

None.

Andrea Imperatori

Lavinia De Monte

Nicola Rotolo

*Center for Thoracic Surgery
Department of Surgical Sciences
University of Insubria
Ospedale di Circolo
Varese, Italy*

Gianlorenzo Dionigi

*Endocrine Surgery Research Center
Department of Surgical Sciences
University of Insubria
Varese, Italy*

Silvia Uccella

*Department of Human Morphology
University of Insubria
Varese, Italy*

Giovanni Mariscalco

*Cardiac Surgery Unit
Department of Surgical Sciences
University of Insubria
Ospedale di Circolo
Varese, Italy*

Lorenzo Dominioni

*Center for Thoracic Surgery
Department of Surgical Sciences
University of Insubria
Ospedale di Circolo
Varese, Italy*

1. Hamilton BH, Francis IR, Gross BH, Korobkin M, Shapiro B, Shulkin BL, Deeb CM, Orringer MB. Intrapericardial paragangliomas (pheochromocytomas): imaging features. *AJR Am J Roentgenol.* 1997;168:109–113.
2. Brown ML, Zayas GE, Abel MD, Young WF Jr, Schaff HV. Mediastinal paragangliomas: the Mayo Clinic experience. *Ann Thorac Surg.* 2008;86:946–951.
3. Dunn GD, Brown MJ, Sapsford RN, Mansfield AO, Hemingway AP, Sever PS, Allison DJ. Functioning middle mediastinal paraganglioma (phaeochromocytoma) associated with intercarotid paragangliomas. *Lancet.* 1986;1:1061–1064.
4. Disick GI, Palese MA. Extra-adrenal pheochromocytoma: diagnosis and management. *Curr Urol Rep.* 2007;8:83–88.
5. Gopalakrishnan R, Ticzon AR, Cruz PA, Kennedy FB, Duffy FC, Barmada B, Giacobine JW. Cardiac paraganglioma (chemodectoma). *J Thorac Cardiovasc Surg.* 1978;76:183–189.