



Treatment of Severe Post-traumatic Bone Defects With Autologous Stem Cells Loaded on Allogeneic Scaffolds

ETTORE VULCANO, MD
ORTHOPEDIC SURGERY RESIDENT
DEPARTMENT OF TRAUMA AND ORTHOPAEDIC SURGERY

DANIELE A. FALVO, MD
ORTHOPEDIC SURGERY RESIDENT
DEPARTMENT OF TRAUMA AND ORTHOPAEDIC SURGERY

LUIGI MURENA, MD
ASSISTANT PROFESSOR OF ORTHOPEDICS
DEPARTMENT OF TRAUMA AND ORTHOPAEDIC SURGERY

ANTONIO ROSSI, MD, PhD
MICROBIOLOGIST
THE LABORATORY OF MEDICAL MICROBIOLOGY

PAOLO CHERUBINO, MD
CHIEF AND PROFESSOR OF ORTHOPEDICS
DEPARTMENT OF TRAUMA AND ORTHOPAEDIC SURGERY

ANDREINA BAJ, PhD
MICROBIOLOGIST
THE LABORATORY OF MEDICAL MICROBIOLOGY

ANTONIO TONIOLO, MD
CHIEF AND PROFESSOR OF MEDICAL MICROBIOLOGY

UNIVERSITY OF INSUBRIA MEDICAL SCHOOL AND OSPEDALE DI CIRCOLO E FONDAZIONE MACCHI
VARESE, ITALY

ABSTRACT

Mesenchymal stem cells may differentiate into angiogenic and osteoprogenitor cells. The effectiveness of autologous pluripotent mesenchymal cells for treating bone defects has not been investigated in humans. We present a case series to evaluate the rationale of using nucleated cells from autologous bone marrow aspirates in the treatment of severe bone defects that failed to respond to traditional treatments.

Ten adult patients (mean age, 49.6-years-old) with severe bone defects were included in this study. Lower limb bone defects were $\geq 5 \text{ cm}^3$ in size, and upper limb defects $\geq 2 \text{ cm}^3$. Before surgery, patients were tested for antibodies to common pathogens. Treatment consisted of bone allogeneic scaffold enriched with bone marrow nucleated cells harvested from the iliac crest and concentrated using an FDA-approved device. Post-surgery clinical and radiographic follow-up was performed at 1, 3, 6, and 12 months. To assess viability, morphology, and immunophenotype, bone marrow nucleated cells were cultured in vitro, tested for sterility,

and assayed for the possible replication of adventitious (contaminating) viruses.

In 9 of 10 patients, both clinical and radiographic healing of the bone defect along with bone graft integration were observed (mean time, 5.6 months); one patient failed to respond. No post-operative complications were observed. Bone marrow nucleated cells were enriched 4.49-fold by a single concentration step, and these enriched cells were free of microbial contamination. The immunophenotype of adherent cells was compatible with that of mesenchymal stem cells. We detected the replication of Epstein-Barr virus in 2/10 bone marrow cell cultures tested. Hepatitis B virus, cytomegalovirus, parvovirus B19, and endogenous retrovirus HERV-K replication were not detected. Overall, 470 to 1,150 million nucleated cells were grafted into each patient.

This case series, with a mean follow-up of almost 2 years, demonstrates that an allogeneic bone scaffold enriched with concentrated autologous bone marrow cells obtained from the iliac crest provides orthopedic surgeons a novel option for treating important bone defects that are unresponsive to traditional therapies.

INTRODUCTION

Bone defects that do not respond to conventional medical/surgical treatments represent a major challenge for orthopedic surgeons. Cell-based therapies aim at regenerating damaged tissues that fail to heal after traditional treatment. In orthopedic surgery, platelet-derived growth factors (PDGFs) and bone morphogenetic proteins (BMPs) have been used to stimulate bone regeneration in a variety of clinical conditions, including long bone non-unions, spinal fusion surgery, and repair of symptomatic posterolateral lumbar spine non-unions.^{1,2} While stem cells of different origin (eg, bone marrow, peripheral blood, skeletal muscle myoblasts) have been widely investigated in other medical specialties, mainly cardiology, cell therapy has been utilized to a lesser degree in orthopedic surgery.³⁻⁹

In small animals, bone marrow stem cells favor healing or fractures and repair of tendons.^{10,11} Bone marrow mesenchymal stem cells (MSCs) are multipotent cells that reside in the bone marrow in proximity to hematopoietic stem cell niches, and are involved in bone marrow homeostasis and in regulating the maturation of both hematopoietic and non-hematopoietic cells.^{12,13} The MSCs have the potential to proliferate and differentiate into osteoblasts, chondroblasts, odonto-

blasts, and adipocytes.¹⁴ Because they can be easily obtained from bone marrow aspirates in adults, and either directly implanted *in vivo* or expanded *in vitro* before implantation, MSCs have great potential for clinical applications. Thus, when matrix and osteoprogenitors are scarce—as in the case of large bone defects—cell-based therapies might provide novel treatment options.⁸

Bone healing requires implanted cells to differentiate into osteoblasts, secrete matrix constituents, and ultimately differentiate into osteocytes. Differentiation requires several genes to be turned on (and off) in a growth- and differentiation-specific manner. For instance, in mice, Notch signaling inhibits osteoblast differentiation through the Hes/Hey proteins that reduce Runx2 transcriptional activity.¹⁵ These studies suggest that MSCs could be expanded *in vitro* by activating the Notch pathway, whereas *in vivo* differentiation and bone formation would require suppressing this pathway. In the same cell line, overexpression of the dentin matrix protein 1 in MSCs induced their differentiation into odontoblast-like cells.¹⁶ The process requires the regulated activation of transcription factors (eg, core binding factor 1), expression of BMP2 and BMP4, genes associated with extracellular matrix (ECM) deposition (eg, alkaline phosphatase, osteopontin, osteonectin, osteocalcin), and late genes like DMP2 and dentin sialoprotein.¹⁶ Although much experimental knowl-

edge exists in the literature, the clinical application of adult MSCs for treating large bone defects is still in its infancy.^{12,17-22}

Differentiation of stem cells into bone tissue is influenced by environmental factors, including the interaction of cells with an adequate extracellular scaffold, the supply of oxygen and growth factors, and mechanical properties of the microenvironment.²²⁻²⁴ These studies indicated that substantial numbers of cells and an adequate scaffold were essential for bone formation. In principle, cell-based therapies for bone regeneration should include isolating, expanding *in vitro*, and inducing the differentiation of progenitor cells before re-implantation within an adequate ECM. However, there are numerous ethical and legal considerations inherent with these procedures.^{9,25-30} In this context, utilizing sufficient numbers of autologous MSCs during immediate implantation is an attractive approach. This approach would eliminate culture-derived problems, including cell aging, cell reprogramming, and contamination/infection by microbes and/or non-autologous culture components.³¹ Recently, the U.S. Pharmacopeia, which establishes written and physical standards for medicines, food ingredients, dietary supplement products, and ingredients addressed the safety aspects of cell therapy by recommending simple procedures whenever applicable.²⁷

The current case series presents a

novel approach based on the use of autologous MSCs and allogeneic bone graft as a scaffold for treating large bone defects that failed to respond to traditional medical and surgical therapies.

MATERIALS AND METHODS

From November 2008 to September 2011, 10 patients (7 males [70%] and 3 females [30%]) suffering from severe bone defects were recruited into the study. Inclusion criteria comprised: 1) bone defects and altered bone-consolidations unresponsive to previous surgical treatments, 2) minimum defect size ≥ 5 cm³ (lower limb) or ≥ 2 cm³ (upper limb), and 3) in the case of non-union or delayed consolidation, a minimum of 2 months was required from the last surgery. Exclusion criteria included: 1) local or systemic infection, 2) radiographic evidence of epiphyseal growth cartilage, 3) severe soft tissue alterations that could not allow proper bone covering at the implantation site, 4) pathologic fractures or neoplastic lesions, 5) severe metabolic and autoimmune disease, 6) anti-neoplastic therapy, and 7) pregnancy.

Patients were treated at the Department of Orthopaedic Surgery and Traumatology, University of Insubria, Varese, Italy. Approval of the Hospital Ethics Committee and the written, informed consent of patients were obtained for all patients. The mean age of patients was 49.6-years-old (range, 17-84). Different pathologies were treated: 6 cases of femur non-unions (60%), 1 tibial shaft non-union (10%), 1 humerus non-union (10%), 1 very severe bone loss secondary to complex exposed leg fracture (10%), and 1 proximal humerus cyst (10%) which required 3 humeral shaft fractures to be treated conservatively. As shown in Table I, patients were tested for serum antibodies to common pathogens (*Treponema pallidum*, human immunodeficiency virus (HIV), hepatitis B virus (HBV), hepatitis C virus (HCV), cytomegalovirus (CMV), Epstein-Barr virus (EBV), and parvovirus B19) prior to surgery.

Harvest and processing of bone marrow cells.

In these studies, we utilized the SmartPREP-2 Bone Marrow Aspirate Concentrate System (Harvest Technologies GmbH, Munich, Germany)—a dedi-

cated, FDA-approved, CE-marked device consisting of a centrifuge system for producing autologous bone marrow aspirate concentrate (BMAC). Fresh bone marrow aspirate (BMA; 60-120 ml.) was introduced in a disposable dual chamber of the table-top centrifuge system; the first chamber contained a floating layer of a specific density. During centrifugation, red blood cells (RBCs) were separated from nucleated cells, platelets and plasma, then cellular elements and plasma automatically decanted into the second chamber and concentrated by centrifugation. A portion of plasma was removed, and cellular elements were re-suspended in approximately 12 ml. of plasma. (The concentration step was accomplished in 15 minutes.) The BMAC contained unchanged proportions of myelocytes, granulocytes, lymphocytes, monocytes, proerythroblasts, and erythroblasts as compared to the initial bone marrow aspirate.³² Bone marrow aspirate was obtained from the posterior iliac crest using a 6 lumen Jamshidi type trocar needle and 20-ml. syringes pre-flushed with Na-heparin (1,000 units/ml.). The trocar was initially directed at a 30° angle to the horizontal plane, and parallel to the plane of the crest. It was then inserted 5 cm. toward the anterior cortex. At least 60 ml. of BMA were extracted while rotating and slowly withdrawing the needle toward the cortex. The BMA was then concentrated using the SmartPREP-2 system in the operating suite, and BMAC (≥ 10 ml) was then transferred under sterile conditions to the surgical field, together with an appropriate amount of homologous bone graft obtained from the local bone bank.

Surgical methods.

The surgical technique required exposure of the bone defect, tissue swabbing for microbiologic cultures, debridement of the bony surface until viable tissue was visible, and subsequent grafting of allogeneic bone (Bone Bank, Istituto Ortopedico Gaetano Pini, Milan, Italy) enriched with BMAC. Mechanical stability was thoroughly evaluated and accounted for. At the end of surgery, 2 ml. of BMA and approximately 0.5 ml of BMAC were submitted to the Microbiology laboratory for the following assessments: 1) pre- and post-concentration cell counts, 2) sterility tests, 3) culture of nucleated cells to assess cell morphology, replication, and

differentiation, and 4) assessment of virus-induced CPE and of adventitious viruses.

Pre-operative serologic status of patients.

Pre-operative serum specimens from patients were tested for multiple pathogens, in which antibodies to HIV, HBV, HCV, CMV, EBV, and parvovirus B19 were utilized in enzyme-linked immunosorbent assays (ELISA; DiaSorin S.p.A., Saluggia (Vercelli), Italy; Biotrin International, Dublin, Ireland). Antibodies to *T. pallidum* were assayed against recombinant antigens (DiaSorin S.p.A.).

Bone marrow cell cultures.

Two samples of bone marrow (pre- and post-concentration) were obtained in heparin tubes from each patient. Blood cell counts were obtained using routine analyzers (Sysmex Europe GmbH, Norderstedt, Germany). Nucleated cells were isolated by centrifugation on two different Ficoll-Histopaque gradients (1.077 and 1.199 g/ml.). Cell viability was evaluated by trypan-blue exclusion. Cell suspensions were plated in 75-cm² tissue culture flasks using Mesenchymal Stem Cell Growth Medium (Lonza, Basel, Switzerland) with added basic fibroblast growth factor (bFGF; 5 ng/ml.) and incubated at 37°C in air with 5% CO₂. Stromal cells adhered to plastic within 48 hours after plating, with cell replication initiating after adhesion. Upon reaching confluency in 5-7 days, adherent cells were harvested using trypsin-EDTA and re-plated for subsequent in vitro passage. We collected supernatant from each culture at different times, clarified them by low-speed centrifugation, aliquoted the supernatants, and froze them at -70°C in liquid nitrogen before processing.

Cell cultures were observed at 3-day intervals using a phase-contrast microscope with a digital camera to evaluate cell morphology and the possible development of CPE. Images were acquired with a 10X, 20X, and 40X objective and recorded using a computerized image analysis system (Image DB, Amplimedical, Mira, Italy).

Sterility tests and Mycoplasma detection.

Aliquots of BMA, BMAC, and bone marrow cells that were cultured for 2-4 weeks were inoculated into both aero-

bic and anaerobic blood culture vials (BACTEC™ Plus Aerobic/F medium and Plus Anaerobic/F Vials; Becton Dickinson and Company, Franklin Lakes, New Jersey) and incubated for 14 days. Cell culture supernatants were also tested for *Mycoplasma* spp. using a commercial kit (MycoAlert® Mycoplasma Detection Kit, Lonza, Rockland, Maine), which employs measurements of enzymatic ATP-conversion combined with luminescence. The test can detect a wide range of *Mycoplasma* species, including the more common *M. fermentans*, *M. hyorhinitis*, *M. arginini*, *M. orale*, and *M. salivarium*.

Detection of adventitious viruses in cultured bone marrow cells.

At the end of the 4-week culture period, cell cultures were tested for adventitious (contaminating) viruses by polymerase chain reaction (PCR). The DNA was extracted from cell pellets (each consisting of 10^6 cells) using QIAamp DNA Blood Midi Kit (QIAGEN GmbH, Hilden, Germany); the QIAamp DNA Mini Kit (QIAGEN GmbH) was used for supernatants. The RNA was extracted from supernatants using the QIAamp Viral RNA Mini Kit (QIAGEN GmbH). Both DNA and RNA were eluted in 50 μ L of buffer AE, and RNA was extracted from cultured cells using the acid guanidinium thiocyanate and phenol chloroform method (TRIzol®, Invitrogen, Carlsbad, California). Samples were mixed with 2 volumes of RNAzol and extracted with 200 μ L chloroform. The RNA-containing aqueous phase was then precipitated with 500 μ L isopropanol, and the centrifuged RNA pellet was washed with 75% ethanol and resuspended in 50 μ L sterile water. Viral genomes were detected using amplification methods specific to HBV, CMV, EBV, herpes simplex virus-1 and -2 (HSV-1 and -2), parvovirus B19 (diagnostic kits from QIAGEN and QIAGEN-artus GmbH, Hilden, Germany). Viral RNA was retro-transcribed with the SuperScript® VILO™ cDNA synthesis kit (Invitrogen) and random hexamer primers. The cDNA product was then amplified using specific methods to detect HCV and HIV (QIAGEN-artus GmbH), as well as in-house test assays for the endogenous retrovirus K.³³

Characterization of cultured bone marrow cells.

The surface expression of differentiation markers was evaluated by flow

cytometry (FACSCalibur,™ Becton Dickinson Biosciences, Franklin Lakes, New Jersey) and immunofluorescence assays. Mouse-derived monoclonal antibodies were used to detect CD105, CD73, CD90 (expected expression by MSCs), CD45, CD34, and CD14 (expected lack of expression by MSCs) in our assays. Cultured adherent cells were washed with PBS, detached by scraping, and counted. Cell suspensions (approximately 10^6 /ml. in FACS buffer) were dispensed in sterile tubes (0.3 ml./tube) and incubated on ice with antibodies directed against different markers; FITC-labeled goat anti-mouse was used as the secondary antibody. Two negative controls were stained with FITC-conjugated antibody: unstained cells and cells incubated with a non-relevant mAb (anti-HIV p24).

Patient follow-up.

According to the routine protocol used at our Department of Trauma and Orthopaedic Surgery, each patient was evaluated clinically and radiographically (2 plane x-rays) at five pre-determined time points: 1) pre-operative, 2) 1 month post-operative, 3) 3 months post-operative, 4) 6 months post-operative, 5) 12 months post-operative. The patients' adverse events (AEs) that occurred while on study were recorded and reported, and results analyzed using observational statistics.

RESULTS

Serologic evaluation before surgery.

As shown in Table I, no positive reactions against *T. pallidum*, HIV, and HCV were detected. Anti-HBc antibody was found in 5 of 10 patients (50%), but none was HBsAg-positive. Antibody IgG to parvovirus B19 was detected in 6 of 8 patients (75%), and IgG against EBV and CMV was present in all patients (100%). Note that these data corroborated the possible risk for surgeons by accidental infections by HBV, EBV, CMV, and parvovirus B19.

Ability of the SmartPreP-2 to concentrate nucleated cells in bone marrow aspirates.

As shown in Table II, cell counts performed before and after the concentration step showed that the procedure strongly reduced RBC numbers, and concentrated nucleated cells by mean

4.49 fold. Thus, the concentration step allowed each patient to receive cell suspensions containing 470-1,000 $\times 10^6$ nucleated cells plus 2-10 $\times 10^9$ platelets.

Cell culture of bone marrow aspirates: sterility tests and phenotypic characterization of adherent cells.

Nucleated cells from BMAs were cultured for 4 weeks. Two days after plating, a mixture of fibroblast-like and hemispherical adherent cells began growing and forming distinct colonies that progressively transformed into monolayers of adherent fibroblast-like cells with rare hemispherical adherent cells (Figs. 1a-1d).

Sterility tests performed on cultures incubated for 4 weeks detected no bacterial or fungal contamination; *Mycoplasma* contamination was also absent (Table III). Cell viability was 93-99%. Cytofluorimetry and immunofluorescence assays showed that adherent bone marrow cells from all patients were negative for the CD45 hematopoietic marker, negative for CD34 endothelial marker, and substantially negative for the CD14 monocyte marker. Cultured cells from all patients expressed one or more of the surface markers CD73, CD90, and CD105. The antigen-profile results are in agreement with the criteria of the International Society for Cellular Therapy that define multipotent mesenchymal stromal cells.³⁴ Thus, considerable numbers of mesenchymal stromal cells were present in all of the patients' concentrated BMAs.

Detection of adventitious viruses in bone marrow cultures.

Adventitious viruses were evaluated by observing the development of cytopathogenic effect (CPE) in cell cultures and by amplification of viral genomes (Table IV). After 2-4 weeks of incubation, 2 of 10 (20%) bone marrow cultures developed CPE in fibroblast-like cells that were characterized by multiple cytoplasmic vacuoles and cell fusion (Fig. 1e and 1f). Cells from both patients continued to grow, but showed reduced viability (88-93%). These cultures were positive for EBV (assessed by PCR), and cultures from Patient PM contained 1,600 genome copies/ 10^5 cells, whereas those from Patient PA had only 10 genome copies/ 10^5 cells. While the latter value is normal for an EBV-positive individual, the prior indi-

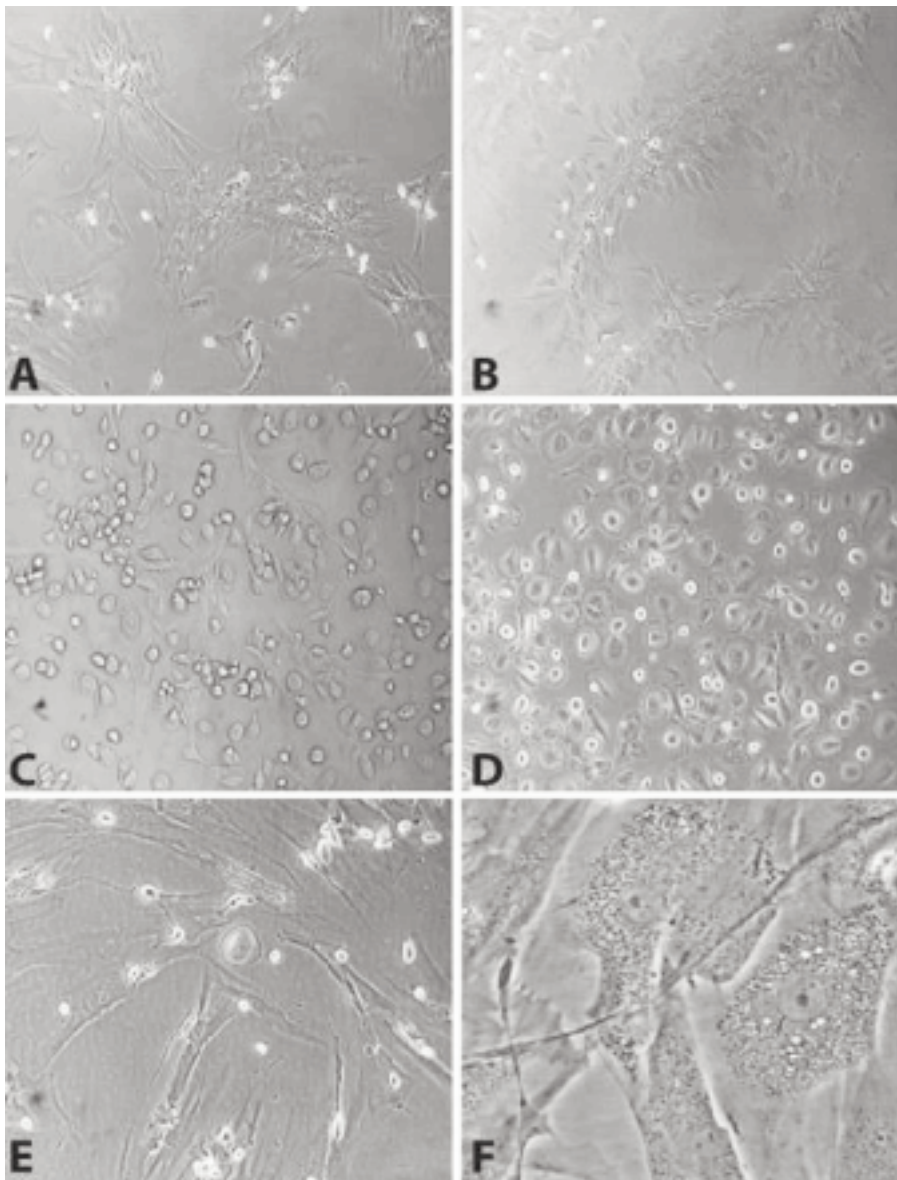
Table I. Serological evaluation of patients before surgery.

Patient	Age	Gender	<i>Treponema pallidum</i>	HIV	HCV	HBV		Parvovirus B19		EBV			CMV	
			Total Ig	Total Ig	IgG	HB-sAg	Anti-HBc	IgG	IgM	IgG VCA	IgG EBNA	IgM VCA	IgG	IgM
01ZL	38	M	-	-	-	-	-	ND	ND	+	+	-	+	-
02AG	35	M	-	-	-	-	+	+	-	+	+	-	+	-
03PM	71	M	-	-	-	-	+	+	-	+	+	-	+	-
04FG	47	M	-	-	-	-	-	+	-	+	+	-	+	-
05TD	17	M	-	-	-	-	-	+	-	+	+	-	+	-
06GA	52	F	-	-	-	-	-	+	-	+(weak)	+	-	+	-
07MLD	84	F	-	-	-	-	+	+	-	+	+	-	+	-
08PA	50	M	-	-	-	-	-	-	-	+	+	-	+	-
09DA	59	M	-	-	-	-	+	ND	ND	+	+	-	+	-
10PG	43	F	-	-	-	-	+	-	-	+	+	-	+	-
No. Positive / No. tested			0/10	0/10	0/10	0/10	5/10	6/8	0/8	10/10	10/10	0/10	10/10	0/10

Table II. Bone marrow aspirates from patients. Cell counts before and after the concentration step in the SmartPREP-2 platform.

Patient	RBC (x10 ⁶ /µl)			Nucleated Cells (x10 ³ /µl)			PLT (x10 ³ /µl)			
	Pre-	Post-	Concentration factor	Pre-	Post-	Concentration factor	Pre-	Post-	Concentration factor	
	concentration			concentration			concentration			
01ZL	4,50	2,10	0,47	15,63	68,20	4,36	159,00	581,00	3,65	
02AG	4,42	1,95	0,44	20,11	64,06	3,19	76,00	303,00	3,99	
03PM	4,23	2,53	0,60	14,97	74,12	4,95	111,00	496,00	4,47	
04FG	4,59	3,41	0,74	30,50	115,00	3,77	131,00	481,00	3,67	
05TD	4,02	1,85	0,46	15,70	63,99	4,08	143,00	509,00	3,56	
06GA	3,53	1,46	0,41	15,14	68,58	4,53	115,00	436,00	3,79	
07MLD	3,13	0,96	0,31	15,48	49,21	3,18	128,00	290,00	2,27	
08PA	3,80	2,21	0,58	8,58	53,50	6,24	167,00	691,00	4,14	
09DA	3,90	1,70	0,44	9,10	54,20	5,96	178,00	702,00	3,94	
10PG	4,35	1,91	0,44	16,54	76,71	4,64	137,000	523,000	3,82	
Mean			0,49				4,49			
Standard deviation			0,12				1,03			

RBC :red blood cells; PLT: platelets



Figures 1A and 1B. Cultures of adherent bone marrow cells 5 days post-plating. In both cases, most cells show fibroblast-like morphology (case 04AG, A; case 10BA, B. Original magnification 100x).

1C and 1D. Cultures of adherent bone marrow cells 12 days post-plating. In both cases, mixtures of fibroblast-like and hemispherical adherent cells are present (case 01ZL, C; case 07MLD, D. Original magnification 200x).

1E and 1F. Cultures of adherent bone marrow cells 12 days post-plating. Cytopathic effect associated to Epstein-Barr virus infection is seen as multiple cytoplasmic vacuoles in fibroblast-like cells (case 03PM. Original magnification: 200x, E; 400x, F).

cates that EBV replicated in Patient PM's cells in vitro. Given the oncogenic potential of EBV, cell-based therapies utilizing bone marrow cells that had been expanded in vitro from this individual might involve significant biologic risk from EBV. Notably, this case supports the indications of the U.S. Pharmacopeia that recently mandated virology controls for cells expanded in culture that are intended for therapeutic use in humans.²⁷ Although most patients were seropositive for CMV and parvovirus B19, these viruses did not reactivate in cultured bone marrow cells,

and there was no evidence of replication of the endogenous retrovirus HERV-K.

Clinical outcomes.

The clinical data, size of the bone defects, and number of implanted cells are summarized in Table V. The mean volume of bone defects, evaluated with standard 2 plane radiographs, was 52.9 cm³ (range, 33-85 cm³).^{7,26} Unfortunately, the precision of this x-ray imaging method was only $\pm 30\%$.³⁵ The mean number of previous surgical treatments was 3.3 (range, 1-15), with a mean duration of 11.2 months (range,

4-68). In two patients (20%) who presented with non-union defects, the rupture of previously positioned plates was observed. The mean follow-up time was 23.8 months (range, 14-36). During surgery, four patients (40%) underwent plate substitution to treat either plate failure or inadequate size.

At mean 5.6 months after surgical intervention (range, 2-12), 9 of 10 patients (90%) had full osteointegration of the bone graft and complete healing of bone defects, as observed on radiographs (Fig. 2-Fig. 4). In one (10%), neither clinical nor radiographic healing was achieved. The patient presented with an open leg fracture with significant loss of skin and bone, secondary to a penetrating trauma. Shortly after damage-control surgery consisting of irrigation and debridement, and fracture stabilization with an external fixator, the patient developed local infection by *Pseudomonas aeruginosa*, and was treated accordingly. After repeated negative microbiologic tests, the patient underwent plastic surgery to cover the soft-tissue defect. At four months post surgery, and in the absence of laboratory and clinical signs of infection, the patient underwent allogeneic bone graft and BMAC infusion. One month after surgery, a pus-secreting fistula appeared at the affected site, which we later confirmed as a reactivation of the *Pseudomonas aeruginosa* infection. Nevertheless, four months postoperatively, radiographic examination documented integration of approximately 50% of the bone graft at the proximal portion of the bone defect. The graft, however, was insufficient to guarantee mechanical stability.

DISCUSSION

In 2007, Giannoudis et al. described the key to bone restoration and regeneration in terms of the "diamond concept."²³ They provided evidence to support four parameters that positively influenced bone formation and overcame impaired healing of bone fractures: 1) utilization of growth factors, 2) incorporation of scaffolds, 3) mesenchymal stem cell use, and 4) stable mechanics.

Experimental and clinical studies have shown that autologous mononuclear cells from bone marrow used in combination with biocompatible scaffolds support osteogenesis in animals

Table III. Sterility tests and phenotypic characterization of adherent cells cultured from bone marrow aspirates of patients.

Pa-tient	Ste-ri-ly	Myco-plasma de-tection ²	Cell vi-ability (%) ³	Adhe-sion to plas-tic ⁴	Cell morphology ⁴	Surface markers of adherent cells ⁵					
						CD 34	CD 45	CD 14	CD 73	CD 90	CD 105
01ZL	+	-	97	+	50% fibroblast-like; 50% hemispherical adherent cells	-	-	-	+	+	ND
02AG	+	-	97	+	fibroblast-like	-	ND	-	+	+	+
03PM	+	-	92	+	fibroblast-like	-	-	-	+	+	+
04FG	+	-	98	+	90% fibroblast-like; 10% hemispherical adherent cells	-	-	-	ND	+	ND
05TD	+	-	97	+	90% fibroblast-like; 10% hemispherical adherent cells	-	-	-	+	+	+
06GA	+	-	95	+	fibroblast-like	-	-	-	+	+	+
07MLD	+	-	98	+	40% fibroblast-like; 60% hemispherical adherent cells	-	-	-	+	+	+
08PA	+	-	95	+	fibroblast-like	-	-	-	+	+	+
09DA	+	-	98	+	90% fibroblast-like; 10% hemispherical adherent cells	-	-	-	+	+	+
10PG	+	-	96w	+	90% fibroblast-like; 10% hemispherical adherent cells	-	-	-	+	+	+
No. Positive / No. Tested						0/10	0/9	0/10	8/9	10/10	8/8

ND not detected

1. Sterility tests according to criteria of the US Pharmacopeia (USP-2011). +, sterile; -, bacterial/mycotic contamination after 4-week culture).
2. *Mycoplasma* detection as in the Methods Section. +, positive; -, negative (after 4-week culture).
3. Cell viability evaluated by the Trypan blue exclusion assay (after 4-week culture).
4. Adhesion to plastic and cell morphology evaluated by phase-contrast microscopy.

Table IV. Detection of viral agents in cultures of bone marrow aspirates from each patient by observing the development of cytopathic effect and using gene amplification methods.

Patient	Cytopathic effect in cultured cells ¹	Parvovirus B19	Amplification of viral genomes ²				
			EBV	CMV	HSV-1/2	HBV	HERV-K
01ZL	-	-	-	-	-	-	-
02AG	-	-	-	-	-	-	-
03PM	Cytoplasmic vacuolation	-	1,600 (genome equivalents/10 ⁵ cells)	-	-	-	-
04FG	-	-	-	-	-	-	-
05TD	-	-	-	-	-	-	-
06GA	-	-	-	-	-	-	-
07MLD	-	ND	ND	ND	ND	ND	ND
08PA	Weak	-	10 (genome equivalents/10 ⁵ cells)	-	-	-	-
09DA	-	-	-	-	-	-	-
10PG	-	-	-	-	-	-	-
No. Positive/ No. Tested		2/10	0/9	2/9	0/9	0/9	0/9

ND not detected

1. Evaluation of cytopathic effect through serial examination by phase-contrast microscopy.
2. Detection of adventitious viruses by gene amplification (after 4-week culture). See the Methods Section.

and in humans, respectively.^{8-9, 36-40} Differentiation of osteoprogenitor cells is significantly dependent on the microenvironment, thus facilitating the use of BMAC as a viable option for therapeutic angiogenesis and bone regeneration.⁴¹⁻⁴⁴ The present study describes the com-

plete healing of bone defects that are refractory to traditional surgery within 3-12 months following treatment with BMAC in 9 of 10 patients (90%). The one failure was observed in a patient with a complex, severe leg injury, who was accrued on study as an extreme

measure to avoid limb amputation. While the cases investigated in our case series were heterogeneous and clinically complex, all had been unresponsive to conventional medical/surgical intervention. Hence, the complete healing that we observed in 9 patients was encouraging.

Table V. Characteristics of patients.

Patient	Age at surgery (years)	Sex	Affected site	Diagnosis	No. of previous surgeries	Size of bone defect (cm ³)	No. of implanted bone marrow nucleated cells (x10 ⁶)	Clinical and radiographic healing (months)
01ZL	38	M	Proximal metaphyseal femur	Non-union	2	47	680	12
02AG	35	M	Distal metaphyseal femur	Non-union	15	45	640	6
03PM	71	M	Mid-humerus shaft	Non-union	0	49	740	3
04FG	47	M	Femur proximal shaft	Non-union	6	33	1,150	9
05TD	17	M	Meta-diaphyseal proximal humerus	Bone cyst	1	85	640	3
06GA	52	F	Distal metaphyseal femur	Non-union	1	33	680	3
07MLD	84	F	Distal metaphyseal femur	Non-union	1	59	490	6
08PA	50	M	Mid 1/3 tibia shaft	Complex open leg fracture	4	74	530	failure
09DA	59	M	Distal metaphyseal femur	Non-union	1	53	540	4
10PG	43	F	Mid 1/3 tibia shaft	Non-union	2	51	570	4

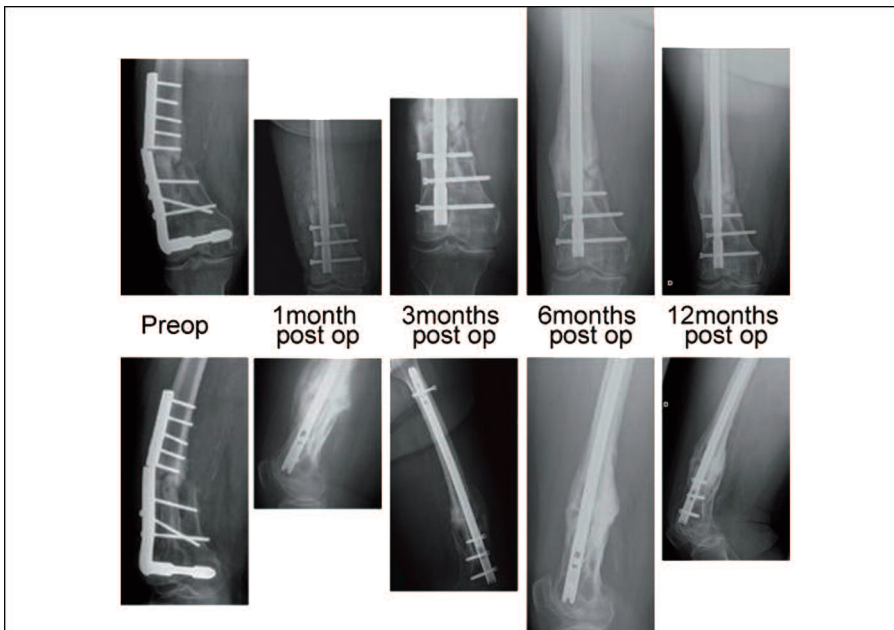

Figure 2. An 84 year-old female, with distal femur fracture treated with a plate in May 2008. Failure of the plate occurred in May 2009, with evident non-union. In May 2009, the patient underwent surgery, including removal of hardware, implantation of an intramedullary retrograde nail, and BMAC plus allogeneic bone grafting. The figure illustrates bone healing at 6 months.

Our study had three major inherent limitations: 1) the relatively small number of cases, 2) lack of a control group, and 3) heterogeneity of clinical diagnoses. Despite clinical and radiographic success in most cases, these data may not necessarily yield comparable results in patients with different diagnoses that lead to bone defects or those with larger defects. However, these data provide the rationale for a larger, prospective randomized controlled trial (RCT) of autologous stem cells loaded on allogeneic scaffolds.

Despite symptomatic improvement and significant bone formation in 9 of 10 patients (90%), our treatment failed to cure all of the bone defects. In this limited series, however, our protocol using autologous BMAC in combination with allogeneic bone grafts was safe and efficacious in both the short and long-term, without significant impact on total operating time, thus benefitting



clinical outcomes and resource utilization. Bone marrow samples (before and after concentration) remained consistently sterile, and the cost of the procedure was relatively inexpensive compared to alternative methods and more expensive drugs (eg, bone morphogenetic proteins) that are used to treat large bone defects. The BMAC Kit was purchased by our Institution at a significantly lower cost than the OP1 Bone Morphogenetic Protein (Stryker, Mahwah, New Jersey).

In addition, there was no morbidity associated with autologous bone graft transplantation (eg, infections, seromas, hematomas, herniation of abdominal contents, vascular injuries, neurologic injuries, iliac wing fractures), and no significant side effects were observed.⁴⁶ Further advantages of the one-stage isolation procedure in comparison to the ex-vivo expansion of autologous cells from bone marrow are the reduced cost and the absence of infections attributable to the complex procedures required for cellular expansion.⁸

Analysis of cell differentiation markers and virologic studies showed that considerable numbers of mesenchymal stem cells were readily obtainable from bone marrow aspirates of adult patients, and that virus reactivation was rarely detected in bone marrow cells. Another major advantage was the elevated platelet concentration (approximately 373%) that we reported in this study. When activated, platelets release granules that are rich in tissue (including bone) growth factors, cytokines and chemokines, such as platelet-derived growth factor (PDGF- $\alpha\alpha$, $\beta\beta$ and $\alpha\beta$ isomers), transforming growth factor (TGF- β , $\beta 1$ and $\beta 2$ isomers), platelet factor 4 (PF4), interleukin-1 (IL-1), platelet-derived angiogenesis factor (PDAF), VEGF, epidermal growth factor (EGF), platelet-derived endothelial growth factor (PDEGF), epithelial cell growth factor (ECGF), insulin-like growth factor (IGF), osteocalcin, osteonectin, fibrinogen, vitronectin, fibronectin, and thrombospondin.⁴⁷⁻⁵³

Adult mesenchymal stem cells, osteoblasts, fibroblasts, endothelial cells and epidermal cells respond to the abovementioned proteins in multiple pathways, and promote tissue/bone formation.^{51,54}

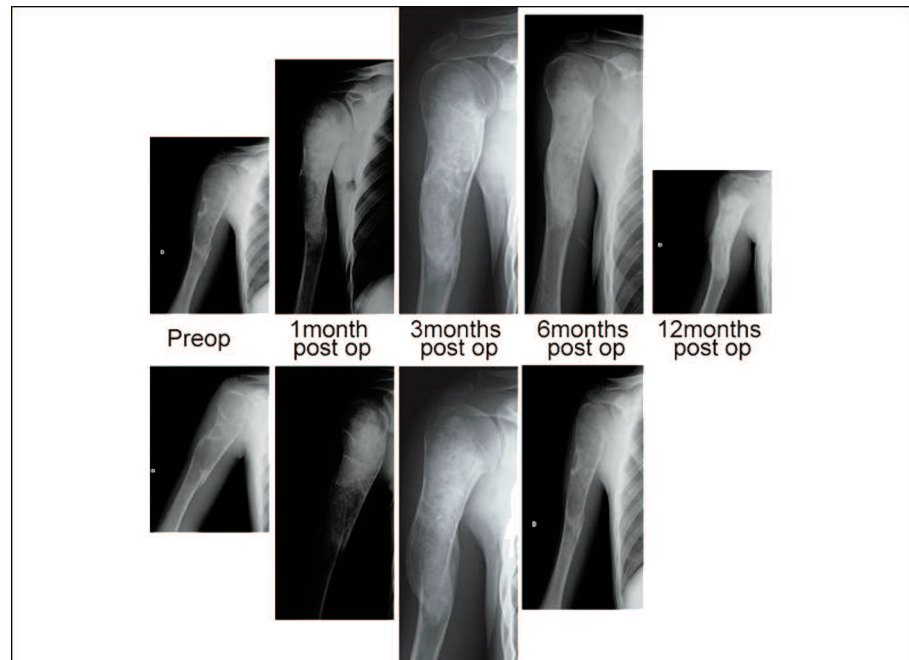


Figure 3. A 17 year-old male with a proximal humerus bone cyst that caused 3 fractures, who was treated with BMAC plus allogeneic bone grafting. The figure illustrates bone healing at 6 months.

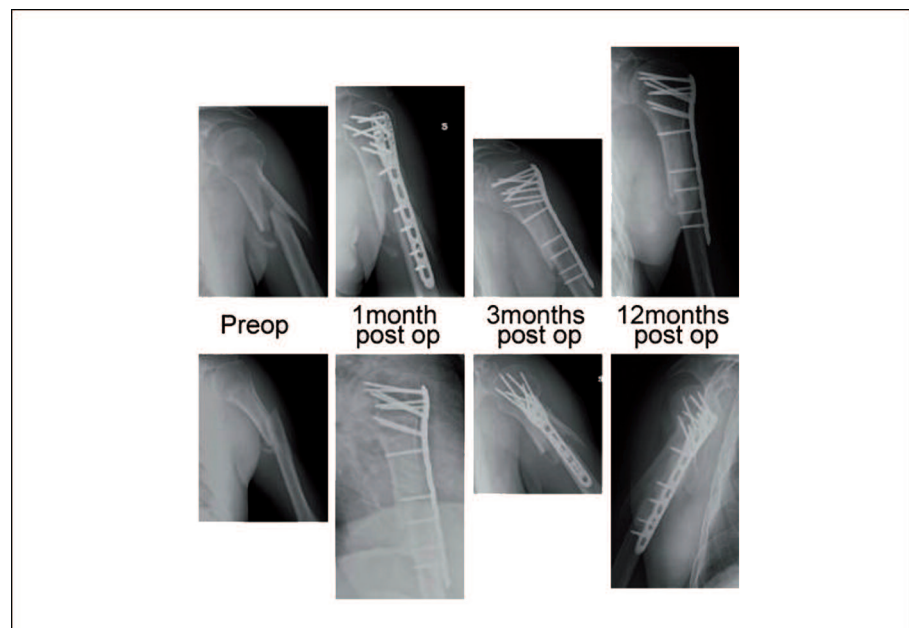


Figure 4. A 71 year-old male, with mid-humeral shaft fracture treated conservatively, developing non-union, who was treated with plate and BMAC plus allogeneic bone grafting. The figure illustrates bone healing at 3 months.

CONCLUSIONS

We presented a new technique to overcome impaired bone healing in patients who are affected by large bone defects that are unresponsive to traditional therapies. To further extend our promising results, we encourage investigators to conduct multicenter, prospective, RCTs to evaluate and understand better the efficacy of BMAC grafts in

treating complex bone defects. Based on our preliminary data, the procedure might well provide clinical outcomes that are comparable to those of current autologous bone graft transplantation, albeit with significantly less treatment-related morbidity.

Overall, BMAC supplemented with allogeneic bone delivered platelet-derived growth factors locally and mesenchymal stem cells, and mechanical stability was conferred by the bone scaffold.

fold—the elements that meet the “diamond concept” of Giannoudis *et al.*²³ Given the safety, efficacy, cost-effectiveness, and simplicity, we encourage the use of allogeneic bone grafts enriched with autologous concentrated bone marrow cells obtained from the iliac crest for treating large bone defects that are unresponsive to traditional therapies. Moreover, future investigation should assess how the overall “organismal state” of the patient influences those mechanisms that regulate the production and function of bone marrow precursor stem cells.⁵⁵ **STI**

ACKNOWLEDGEMENTS

This work was supported by Regione Lombardia (Grant “Piano Sangue-2009”). We are grateful to Franco Locatelli (Pavia, Italy) and Gianni Zatti (Monza, Italy) for their biological and clinical contributions.

AUTHORS' DISCLOSURES

The authors have no conflicts of interest or financial ties to disclose.

REFERENCES

1. Axelrad TW, Einhorn TA. Bone morphogenetic proteins in orthopaedic surgery. *Cytokine Growth Factor Rev.* 2009; 20(5-6):481-8.
2. Intini G. The use of platelet-rich plasma in bone reconstruction therapy. *Biomaterials* 2009;30(28):4956-66.
3. Wollert KC, Drexler H. Cell therapy for the treatment of coronary heart disease: a critical appraisal. *Nat Rev Cardiol.* 2010; 7(4):204-15.
4. Williams AR, Trachtenberg B, Velazquez DL, *et al.* Intramyocardial stem cells injection in patients with ischemic cardiomyopathy: functional recovery and reverse remodelling. *Circ Res* 2011;108(7):792-6.
5. Nyolczas N, Charwat S, Posa A, *et al.* Tracking the migration of cardially delivered therapeutic stem cells in vivo: state of the art. *Regen Med*;4(3):407-22.
6. Nyolczas N, Gyöngyösi M, Beran G, *et al.* Design and rationale for the Myocardial Stem Cell Administration After Acute Myocardial Infarction (MYSTAR) Study: a multicenter, prospective, randomized, single-blind trial comparing early and late intracoronary or combined (percutaneous intramyocardial and intracoronary) administration of nonselected autologous bone marrow cells to patients after acute myocardial infarction. *Am Heart J* 2007;153(2):212.e1-7.
7. Schmitt CA. Stem cells: injection during CABG surgery helps failing hearts. *Nature Rev Cardiol* 2011;8(8):424.
8. Jäger M, Herten M, Fochtmann U, *et al.* Bridging the gap: bone marrow aspiration concentrate reduces autologous bone grafting in osseous defects. *J Orthop Res* 2011; 29(2):173-80
9. Jäger M, Jelinek EM, Wess KM, *et al.* Bone marrow concentrate: a novel strategy for bone defect treatment. *Curr Stem Cell Res Ther* 2009;4(1):34-43.
10. Matsumoto T, Li M, Nishimura H, *et al.* Lnk-dependent axis of SCF-cKit signal for osteogenesis in bone fracture healing. *J Exp Med* 2010;207(10):2207-23.
11. Oe K, Kushida T, Okamoto N, *et al.* New strategies for anterior cruciate ligament partial rupture using bone marrow transplantation in rats. *Stem Cells Dev* 2011;20(4):671-9.
12. Gómez-Barrena E, Rosset P, Müller I, *et al.* Bone regeneration: stem cell therapies and clinical studies in orthopaedics and traumatology. *J Cell Mol Med* 2011;15(6):1266-86.
13. Hematti P. Human embryonic stem cell-derived mesenchymal progenitors: an overview. *Methods Mol Biol* 2011;690:163-74.
14. Hwang NS, Zhang C, Hwang YS, *et al.* Mesenchymal stem cell differentiation and roles in regenerative medicine. *Wiley Interdiscip Rev Syst Biol Med* 2009;1(1):97-106.
15. Hilton MJ, Tu X, Wu X, *et al.* Notch signaling maintains bone marrow mesenchymal progenitors by suppressing osteoblast differentiation. *Nat Med* 2008;14(3):306-14.
16. Eapen A, Ramachandran A, Pratap J, *et al.* Activation of the ERK1/2 mitogen-activated protein kinase cascade by dentin matrix protein 1 promotes osteoblast differentiation. *Cells Tissues Organs* 2011;194(2-4):255-60.
17. Arvidson K, Abdallah BM, Applegate LA, *et al.* Bone regeneration and stem cells. *J Cell Mol Med* 2011;15(4):718-46.
18. Ito H. Chemokines in mesenchymal stem cell therapy for bone repair: a novel concept of recruiting mesenchymal stem cells and the possible cell sources. *Mod Rheumatol* 2011; 21(2):113-21.
19. Bianco P, Riminucci M, Gronthos S, *et al.* Bone marrow stromal stem cells: nature, biology, and potential applications. *Stem Cells* 2001;19(3):180-92.
20. Ciapetti G, Ambrosio L, Marletta G, *et al.* Human bone marrow stromal cells: In vitro expansion and differentiation for bone engineering. *Biomaterials* 2006; 27(36):6150-60
21. Herzog EL, Chai L, Krause DS. Plasticity of marrow-derived stem cells. *Blood* 2003; 102(10):3483-93.
22. Körbling M, Katz RL, Khanna A, *et al.* Hepatocytes and epithelial cells of donor origin in recipients of peripheral-blood stem cells. *N Engl J Med* 2002;346(10):738-46.
23. Giannoudis PV, Einhorn TA, Marsh D. Fracture healing: the diamond concept. *Injury* 2007; 38 Suppl 4:S3-6.
24. North TE, Goessling W, Peeters M, *et al.* Haematopoietic stem cell development is dependent on blood flow. *Cell* 2009; 137(4):736-48.
25. Okazaki K, Maltepe E. Oxygen, epigenetics and stem cell fate. *Regen Med* 2006; 1(1):71-83.
26. Dallari D, Savarino L, Stagni C, *et al.* Enhanced tibial osteotomy healing with use of bone grafts supplemented with platelet gel or platelet gel and bone marrow stromal cells. *J Bone Joint Surg* 2007;89(11):2413-20.
27. United States Pharmacopeia. 2011. USP 34-NF 29.
28. Connolly J, Guse R, Lippiello L, *et al.* Development of an osteogenic bone-marrow preparation. *J Bone Joint Surg* 1989; 71(5):684-91.
29. Hernigou P, Mathieu G, Poignard A, *et al.* Percutaneous autologous bone-marrow grafting for non-unions. Surgical technique. *J Bone Joint Surg* 2006;88(Suppl 1)Pt 2:322-7.
30. Hernigou P, Poignard A, Beaujean F, *et al.* Percutaneous autologous bone-marrow grafting for non-unions. Influence of the number and concentration of progenitor cells. *J Bone Joint Surg* 2005;87(7):1430-7.
31. Song L, Tuan RS. Transdifferentiation potential of human mesenchymal stem cells derived from bone marrow. *FASEB J* 2004; 18(9):980-2.
32. Hermann PC, Huber SL, Herrler T, *et al.* Concentration of bone marrow total nucleated cells by a point-of-care device provides a high yield and preserves their functional activity. *Cell Transplant* 2008;16(10):1059-69.
33. Jeong BH, Lee YJ, Carp RI, *et al.* The prevalence of human endogenous retroviruses in cerebrospinal fluids from patients with sporadic Creutzfeldt-Jakob disease. *J Clin Virol* 2010;47(2):136-42.
34. Dominici M, Le Blanc K, Mueller I, *et al.* Minimal criteria for defining multipotent mesenchymal stromal cells. The International Society for Cellular Therapy position statement. *Cytotherapy* 2006;8(4):315-7.
35. Abdollahi K, Kumar PJ, Shepherd L, *et al.* Estimation of defect volume in segmental defects of the tibia and femur. *J Trauma* 1999; 46(3):413-6.
36. Becker S, Maissen O, Ponomarev I, *et al.* Osteopromotion by a beta-tricalcium phosphate/bone marrow hybrid implant for use in

- spine surgery. *Spine* 2006;31(1):11-7.
37. Malard O, Guicheux J, Bouler JM, *et al.* Calcium phosphate scaffold and bone marrow for bone reconstruction in irradiated area: a dog study. *Bone* 2005;36(2):323-30.
38. Hisatome T, Yasunaga Y, Yanada S, *et al.* Neovascularization and bone regeneration by implantation of autologous bone marrow mononuclear cells. *Biomaterials* 2005; 26(22):4550-6.
39. Dallari D, Fini M, Stagni C, *et al.* In vivo study on the healing of bone defects treated with bone marrow stromal cells, platelet-rich plasma, and freeze-dried bone allografts, alone and in combination. *J Orthop Res* 2006; 24(5):877-88.
40. Cancedda R, Mastrogiacomo M, Bianchi G, *et al.* Bone marrow stromal cells and their use in regenerating bone. *Novartis Found Symp* 2003;249:133-43.
41. Bartholomew A, Sturgeon C, Siatskas M, *et al.* Mesenchymal stem cells suppress lymphocyte proliferation in vitro and prolong skin graft survival in vivo. *Exp Hematol* 2002; 30(1):42-8.
42. Moosmann S, Hutter J, Moser C, *et al.* Milieu-adopted in vitro and in vivo differentiation of mesenchymal tissues derived from different adult human CD34-negative progenitor cell clones. *Cells Tissues Organs* 2005;179(3):91-101.
43. Pasquinelli G, Tazzari P, Ricci F, *et al.* Ultrastructural characteristics of human mesenchymal stromal (stem) cells derived from bone marrow and term placenta. *Ultrastruct Pathol* 2007;31(1):23-31.
44. Winer JP, Janmey PA, McCormick ME, *et al.* Bone marrow-derived human mesenchymal stem cells become quiescent on soft substrates but remain responsive to chemical or mechanical stimuli. *Tissue Eng Part A* 2009; 15(1):147-54.
45. Arrington ED, Smith WJ, Chambers HG, *et al.* Complications of iliac crest bone graft harvesting. *Clin Orthop Relat Res* 1996; (329):300-9.
46. Lucarelli E, Donati D, Cenacchi A, *et al.* Bone reconstruction of large defects using bone marrow derived autologous stem cells. *Transfus Apher Sci* 2004;30(2):169-74.
47. Man D, Plosket H, Winland-Brown JE. The use of autologous platelet-rich plasma (platelet gel) and autologous platelet-poor plasma (fibrin glue) in cosmetic surgery. *Plast Reconstr Surg* 2001;107(1):229-37.
48. Sanchez AR, Sheridan PJ, Kupp LI. Is platelet-rich plasma the perfect enhancement factor?: a current review. *Int J Oral Maxillofac Implants* 2003;18(1):93-103.
49. Marx RE, Carlson ER, Eichstaedt RM, *et al.* Platelet-rich plasma: growth factor enhancement for bone grafts. *Oral Surg Oral Med Oral Pathol Oral Radiol Endod* 1998; 85(6):638-46.
50. Harrison P, Cramer EM. Platelet alpha-granules. *Blood Rev* 1993;7(1):52-62.
51. Anitua E, Andia I, Ardanza B, *et al.* Autologous platelets as a source of proteins for healing and tissue regeneration. *Thromb Haemost* 2004;91(1):4-15.
52. Bucholz RW, Einhorn TA, Marsh JL. Bone and joint healing. In: Bucholz RW, Heckman JD, Court-Brown C (eds.), *Rockwood & Green's fractures in adults*. 6th ed., Riverwoods: Lippincott Williams & Wilkins; pp 300-11;2006.
53. Marx RE. Platelet-rich plasma (PRP): what is PRP and what is not PRP? *Implant Dent* 2001;10(4):225-8.
54. Whitman DH, Berry RL, Green DM. Platelet gel: an autologous alternative to fibrin glue with applications in oral and maxillofacial surgery. *J Oral Maxillofac Surg* 1997; 55(11): 1294-9.
55. Mercier FE, Ragu C, Scadden DT. The bone marrow at the crossroads of blood and immunity. *Nat Rev Immunol* 2011;12(1):49-60.