

Clinical Study

A New Algorithm for The Surgical Management of Defects of the Scalp

Mario Cherubino, Dominic Taibi, Stefano Scamoni, Francesca Maggiulli, Danilo Di Giovanna, Rita Dibartolo, Matteo Izzo, Igor Pellegatta, and Luigi Valdatta

Division of Plastic and Reconstructive Surgery, University of Insubria and Ospedale di Circolo e Fondazione Macchi, Viale Borri 57, 21100 Varese, Italy

Correspondence should be addressed to Francesca Maggiulli; francesca.maggiulli@live.it

Received 6 December 2012; Accepted 1 January 2013

Academic Editors: A. S. Halim and B. G. Ulusal

Copyright © 2013 Mario Cherubino et al. This is an open access article distributed under the Creative Commons Attribution License, which permits unrestricted use, distribution, and reproduction in any medium, provided the original work is properly cited.

Scalp reconstruction is a daily challenge for plastic surgeons. The authors propose their algorithm for reconstructive surgery after ablative surgery. They considered not only the size defect but also the anatomical defect and the clinical condition of the patient to achieve the best choice for reconstruction. During the two-year period, a total of 86 procedures were performed on 78 patients. We used five different techniques for reconstruction, including primary closure, graft, local or free flap, and a dermal regeneration template. No statistical difference of complication was observed in the different groups. We consider our algorithm a useful improvement in the management of the defect at the vertex.

1. Introduction

Scalp reconstruction is an “ordinary challenge” for the daily activity of the plastic surgeon and the skin surgeon. Due to high sun exposure and increased mean survival rates, the scalp is an anatomic region where skin cancers grow easily. Primary malignant tumors of the scalp are most frequently epithelial in origin; however, tumors from adnexal and connective tissue elements also occur [1]. Also, as first shield of the cranial bone, in domestic accidents it could be exposed in trauma more often comparing the real encephalic trauma. Burns, pressure sores, or malformation diseases occur quite often and give more easily destruction of the soft tissue cover than the cranial bone [2]. With this papers, the authors present a two-year experience and propose an algorithm of reconstruction of the scalp considering not only the size of the defect, but also the comorbidities, the anatomic structure involved, and the different clinical situation.

2. Patients and Methods

Our study is a retrospective review of all scalp reconstructions performed by the Plastic Surgery Unit of The University

of Insubria, (Varese, Italy) during a 2-year period ending December 2010: we reviewed 86 procedures performed in the treatment of 78 patients with scalp defects. 58 patients were men and 20 were women; the age of the patients ranged from 1-day-old to 84 years, with a mean age of 68 years. According to the type of reconstructive procedure, the patients were grouped into 5 reconstructive categories: A: primary closure; B: skin grafts; C: local scalp flaps; D: application of dermal regeneration template (Integra) with splint-thickness skin graft; and E: free flap reconstruction. We considered only defect of the soft tissue scalp due to the different etiology. All subcutaneous benign lesions and microsurgical replantation [3], as well as full thickness defects of the cranial bone (calvarial defect), were not included in this study. The indications for surgery are listed in Table 1.

Based on the collected data, we developed an algorithm consisting of five reconstructive categories as shown before. The clinical condition of every patient was collected and considered in the reconstruction algorithm. After data collection, a checklist gives the indication of the adequate reconstructive procedure. We consider age, sex, hair distribution on the scalp (Norwood Classification), the personal history of skin cancers, regress RT (radiotherapy) on the scalp, and the

TABLE 1

Clinical condition	Score			
	0	1	2	3
ASA	1	2	3	4
Sex	F	M		
BALDNESS	Norwood class I-II-III	Norwood class IV	Norwood class V-VI-VII	
Age	<50	50 < 65	65 > 80	>80
Regress RT	No		Yes	
History of skin cancers	<2		>2	

ASA score. Score values of more than 5 points give the final indication to reconstruction technique (Table 1). Final intraoperative measurement of the defect and the presence or the absence of *pericranium* layer will provide indications for the more indicated reconstruction strategies.

2.1. Small Defects (Area < 5 cm²). These defects are amenable to direct closure; the maxim diameter of this defect is usually less than 2,5 cm, and give the opportunity of a simple procedure with excellent functional and aesthetic results in most cases. If the diameter of the defect is more than 2,5 cm primary closure quickly becomes more challenging, in particular in the area where the skin is not smooth and elastic but rigid or atrophic as in frontal and parietal regions, and we have to use local flaps. This technique contemplates local tissue redistribution, and functional and aesthetic results are usually excellent.

2.2. Moderate Defects (5 cm² to 20 cm²). If the clinical condition value is less than 5, we performed a local or regional flaps reconstruction. In our experience, the modified double rotation flap (hatchet flap) [4] is the most used because the double effect of rotation and transposition allow distributing the scars in opposite directions. This reconstruction can achieve reconstruction of defects that are involving the galea and/or *pericranium* (periosteum plane). We used local flaps also if the defect is involving the external cortical of cranial bone defect. If the clinical condition value is more than 5, the skin graft is our choice for the defect of this size, when the *periosteum* or the *galea* are not involved in oncological procedures. We used full-thickness skin graft, if the size of the defect was less than 10 cm², otherwise a split-thickness skin graft was performed with a still acceptable aesthetic result. However, the use of the skin graft is not recommended if the patient still have an important hair growing, where the use of flap is more appropriate. In case of poor clinical condition (value >5) and the *pericranium* is involved in the defect, we use the acellular dermal matrix for temporally reconstruction after multiple drill holes placed in outer cortex. In our experience, due to intraoperative pathological examination, only a small amount of *pericranium* is involved comparing with the skin extension, allowing to cover a big area with the dermal regeneration template and achieve a good formation of granulation tissue, from the neighbored tissue.

2.3. Large Defects (>20 cm²). In large defect, if the clinical condition is considered good (value <5), we prefer a free

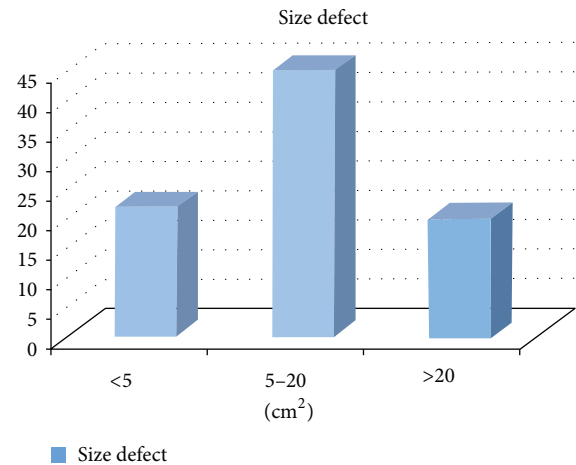


FIGURE 1: Subdivision of the size defect in 86 procedures.

tissue transfer. If the clinical condition has a value less than 5, we consider the presence of *pericranium* as discriminating. If present, direct reconstruction with a partial thickness skin graft is achieved, otherwise the use of acellular dermal matrix (Integra) gives the opportunity of an immediate cover of the defect and a following partial thickness graft application as much as in smaller defects.

3. Results

We present our algorithmic approach to scalp defects, considering not only the size but also the clinical condition and the anatomical structure present. We considered the age, the sex, the hair distribution on the scalp, the history of regress skin cancers or radiotherapy, and the ASA score. The score system that we used, we think, is reliable and useful. It can be planned before the surgery. The area defect can easily be calculated after the Mohs' surgery, as the presence or not of the *pericranium*. We considered 3 different size defects, small, medium, and large. Due this, the best of the 5 five different reconstruction techniques is achieved (Figure 1). In 2 years, we had 86 procedures of scalp reconstruction, with a case of 1-day-old baby to a 84-year-old man. According to our algorithm we divided to 5 different techniques of available reconstruction. In the 85% of the cases, we had "nonmelanoma" skin cancers: mainly BCC (basal cell cancer) 47,5% and SCC (Squamous Cell Cancer) 32,5%. Other pathologies were 15% (Figure 2), including pressures sores,

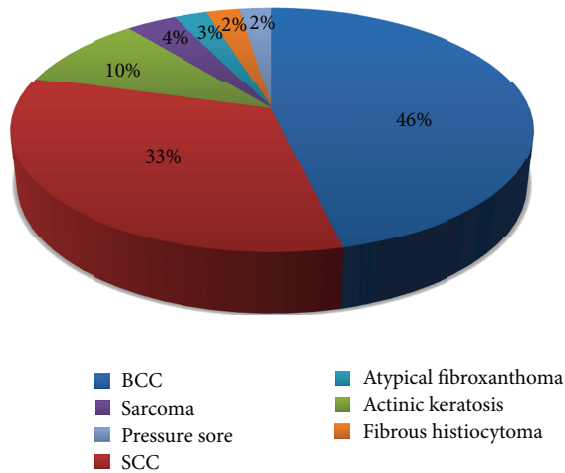


FIGURE 2: Etiology of scalp defect.

fibrous histiocytoma, aethiopic xanthoma, sarcomas, and a case of Aplasia Cutis Congenita (Figure 3). In our two-year experience of using the algorithmical reconstruction, we performed the primary closure technique in 17,5%, local flaps in 37,5% of the procedures, the use of skin graft alone are 35%, the use of the dermal regeneration template in 20% and free flap was used in 2 procedures. Mean followup was 17,5 months (median 20 months and range 10 to 36 months). 30% of the patients had already undergone irradiation in the past. We had 4 cases of tumors recurrence, (5,12%) and no metastases were observed after 2 years. We had a single case of multiply recidivate of SCC who died after 16 months from the first surgery. Counting this case, the overall survival rates at 2 years were 98,8%.

4. Discussion

The authors present an algorithmic approach to scalp defects, considering not only the size [5] but also the clinical condition and the anatomical structure present. In the past, statically difference in complication considering the different clinical conditions has been observed [6], so we decided to develop an algorithm to help the best choose of reconstruction technique. In 2 years, we had 86 procedures of scalp reconstruction, with a case of 1-day-old baby to a 84-year-old man. This big variety of age must be considered: in a baby of one day, the absolute value in square cm is different comparing to an old man of 86 year old. With our algorithm, we try to overcome this. In childhood, we use the burn pediatric scale (Lund and Browder chart) to consider the size of the scalp and then to convert the size defect in the 3 categories shown before. The clinical condition that we are used to consider are age, sex, hair distribution, personal history of skin cancer at the scalp (>2) regress radiotherapy, or the presence of major disease considering the ASA score. The Norwood classification of male baldness [7] is probably the most commonly used today. In our score system, we consider only if the lesion's surrounding tissue is in a baldness condition or not. Patients of Norwood classes V, VI, and VII

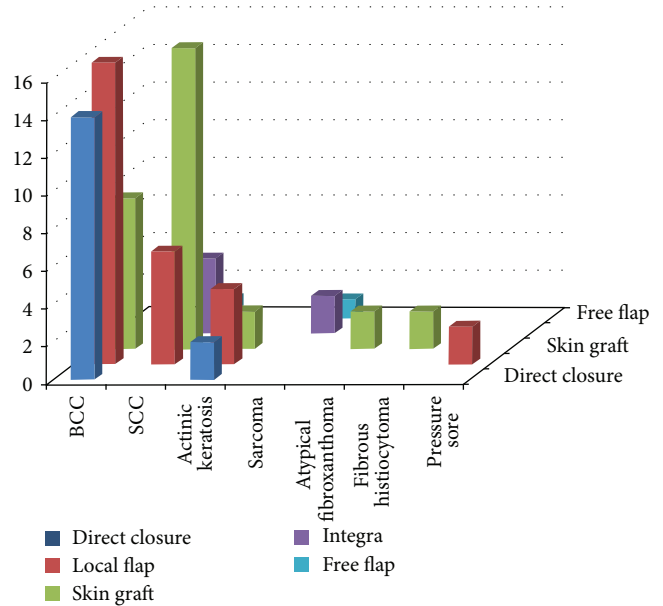


FIGURE 3: Correlation between etiology and reconstruction techniques.

usually have different expectation comparing to classes I, II, III, and IV that have a good hair distribution. Considering the characteristic of the scalp, the limited elasticity is primarily the result of the underlying *galea* and *pericranium* and is round shaped which limits options for primary closure except in relatively small defects. Thus, preparations of large rotation flaps are often required even for relatively small defects.

Primary closure with adjacent tissues may seem like an appropriate first choice for closure of small scalp defects. However, because of the limited elasticity of scalp tissues, usually defects less than 5 cm² (equivalent at less 2,5 cm of diameter) are amenable to direct closure. Local flaps are one of the mainstays of scalp reconstruction in our institution. These flaps can provide healthy, durable, and hair-bearing skin and may aid in healing in patients with compromised wounds. Obviously, the scar residual is always well covered from the hair and most of the patients. No residual of pain, inches, or hypertrophic scar has been observed. They may be performed in small and moderate defects, thanks to the good quality of the local tissue. The flap must be big enough to allow a good cover of the defect; usually the diameter of the rotation flap should be 5 times the defect diameter. The double Hacet flap, our first choice that is used in 17 cases (60,7% of total local flaps), required some lengthens. It is a useful flap, that allow to closure moderate large defect, with the distribution of the scar in two opposite directions from the defect, unlike the rotation flap which obliges to construct a big scar in only one direction.

Skin grafting is an excellent option if the defected does not involve the *pericranium* (periosteal) plane as demonstrated by Robison in 1908. Skin graft cannot be the choice in case of previous irradiated tissue, or if heavy irradiation has been expected in postsurgery treatment, considering the clinic suspect. This method of reconstruction can, however, result

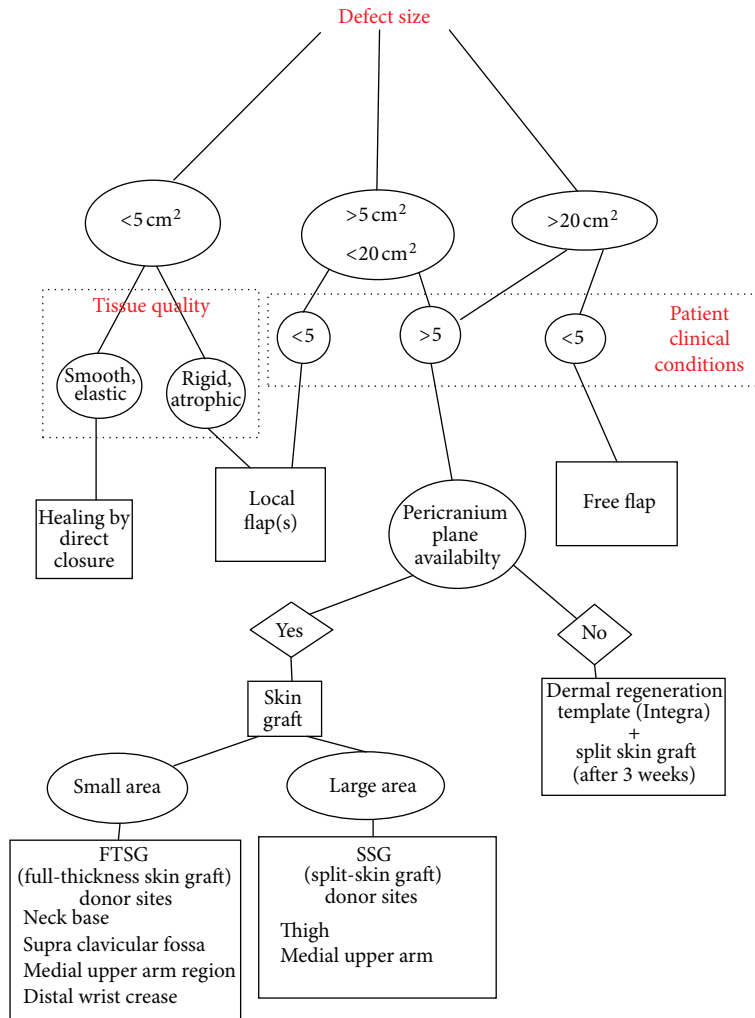


FIGURE 4: Proposed algorithm for scalp reconstruction.

in a suboptimal cosmetic outcome and may not be as durable as normal skin, in particular in a patient with normal scalp's hairs situation. Skin graft is a good choice if the clinical condition is poor (>5).

Full-thickness grafts retain more of the characteristics of normal skin, including color, texture, and thickness, when compared with split-thickness grafts. Our preferred donor sites, in elderly age, are the neck base, supraclavicular fossa, or medial upper arm region. Full-thickness grafts also undergo less contraction while healing. However, full-thickness skin grafts are limited to relatively small, uncontaminated, and well-vascularized wounds and thus do not have as wide a range of application as split-thickness grafts. Donor sites must be closed primarily or, more rarely, resurfaced with a split-thickness graft from another site.

Instead, split-thickness skin graft donor sites heal spontaneously with cells supplied by the remaining epidermal appendages, and these donor sites may be reharvested once healing is complete.

Integra is a acellular dermal regeneration template that became commercially available in 1996. It is a bilaminar

membrane consisting of a porous collagen layer (dermal analogue) bonded to a thin silicone layer. The dermal layer becomes re-vascularized and populated by cells from the patient's own underlying and adjacent tissue over 7–21 days. Once this process is complete, an ultrathin split-thickness skin graft, or epidermal autograft, must be placed over the new dermis after removal of the silicone layer from the new dermal layer.

The dermal substitutes have been applied for coverage of scalp defects when the local tissue is not appropriate for local flaps and when the patient cannot tolerate a flap procedure. Skin cancers defect has been covered too, with safe results [8]. In defect of medium and large size, Integra is a good alternative at free flap [9], we think that it is safer for elder patients, a faster procedure, and cheaper, considering the total amount of many for the entire period of hospitalization of a patient who is going to a major scalp defect reconstruction.

In our experience, the tissue expansion has not been more used except in the only selected cases (medium defect, young patient very motivated). Approximately up to 50% of the scalp

can be reconstructed with an expanded scalp tissue [10, 11]. In the last two years none of the patient accepts the idea of multiple operation. We think that expansion cannot be the first choice in the treatment of scalp defect, but it must be considered in highly motivated young patients also with the high complication rate of the expansion (6%–25%) [12].

The free flap procedure is a good option in large area defects. With a free flap, we are not given back hairs, but a good quality tissue in pliability and quantity give the best aesthetic reconstruction. Wide varieties of flap types have been described in the literature, each with its advantages and disadvantages. In our experience, for massive scalp reconstruction, we prefer *latissimus dorsi* flap with splint-thickness skin graft. We performed a reconstruction with muscle and an STSG, considering the debunking procedures that are reported in the literature for fasciocutaneous flap [13].

5. Conclusion

Successful reconstruction of the scalp requires deep knowledge of patient's clinical condition, precise intraoperative execution and adequate debridement, preservation of blood supply, and proper wound drainage. To achieve this, a careful preoperative planning is mandatory. The authors present their experience in scalp reconstruction, a new algorithm for indication that consider not only the defected size, but also the patient's health. Different studies in the past demonstrate not a statically difference in success between the different reconstruction techniques but a different clinical condition. The scalp, due to its inelasticity and spherical shape, is not an easy region to reconstruct. We divide the defect in base into (1) size, (2) involvement of the periosteum (*pericraneum*) plane, (3) clinical condition of the patient. Due to this, we chose the best reconstruction with classical (full-thickness graft, split thickness, or direct closure or local flap) or new technique (dermal regeneration substitute) or more complex strategy (free flap). We performed a total of 86 procedures with a recurrence rate of 5,12%. The followup of free disease mean period was 17,5 months (median 20 moths and range 10 to 36 months). We consider our algorithm far away from a revolution of scalp reconstructions but a useful improvement in the management of the defect at the vertex (Figure 4).

Conflict of Interests

The authors declare that they have no conflict of interests.

References

- [1] G. Frentz, J. L. Sorensen, and K. Flod, "Non melanoma skin cancer of the scalp. On the etiology," *Acta Dermato-Venereologica*, vol. 69, no. 2, pp. 142–146, 1989.
- [2] M. D. Wells, "Scalp reconstruction," in *Plastic Surgery, Volume 3*, S. J. Mathes, Ed., pp. 607–632, WB Saunders, Philadelphia, Pa, USA, 2nd edition, 2006.
- [3] G. D. H. Miller, E. J. Anstee, and J. A. Snell, "Successful replantation of an avulsed scalp by microvascular anastomoses," *Plastic and Reconstructive Surgery*, vol. 58, no. 2, pp. 133–136, 1976.
- [4] L. J. Sowerby, S. M. Taylor, and C. C. Moore, "The double hatchet flap a workhorse in head and neck local flap reconstruction," *Archives of Facial Plastic Surgery*, vol. 12, no. 3, pp. 198–201, 2010.
- [5] K. C. Shestak and S. S. Ramasastry, "Reconstruction of defects of the scalp and skull," in *Mastery of Plastic and Reconstructive Surgery*, M. Cohen, Ed., vol. 2, pp. 830–841, Lippincott, Philadelphia, Pa, USA, 1994.
- [6] M. I. Newman, M. M. Hanasono, J. J. Disa, P. G. Cordeiro, B. J. Mehrara, and J. M. Serletti, "Scalp reconstruction: a 15-year experience," *Annals of Plastic Surgery*, vol. 52, no. 5, pp. 501–506, 2004.
- [7] O. T. Norwood, "Male pattern baldness: classification and incidence," *Southern Medical Journal*, vol. 68, no. 11, pp. 1359–1365, 1975.
- [8] E. Komorowska-Timek, A. Gabriel, D. C. Bennett et al., "Artificial dermis as an alternative for coverage of complex scalp defects following excision of malignant tumors," *Plastic and Reconstructive Surgery*, vol. 115, no. 4, pp. 1010–1017, 2005.
- [9] E. K. Yeong, H. F. Huang, and M. T. Chen, "The use of artificial dermis for reconstruction of full thickness scalp burn involving the calvaria," *Burns*, vol. 32, no. 3, pp. 375–379, 2006.
- [10] E. R. Manders, M. J. Schenden, J. A. Furrey et al., "Skin expansion to eliminate large scalp defects," *Plastic and Reconstructive Surgery*, vol. 74, pp. 493–507, 1984.
- [11] S. E. MacLennan, J. F. Corcoran, and H. W. Neale, "Tissue expansion in head and neck burn reconstruction," *Clinics in Plastic Surgery*, vol. 27, no. 1, pp. 121–132, 2000.
- [12] L. C. Argenta, M. J. Watanabe, and W. C. Grabb, "The use of tissue expansion in head and neck reconstruction," *Annals of Plastic Surgery*, vol. 11, no. 1, pp. 31–37, 1983.
- [13] Z. N. Chicarilli, S. Ariyan, and C. B. Cuono, "Single-stage repair of complex scalp and cranial defects with the free radial forearm flap," *Plastic and Reconstructive Surgery*, vol. 77, no. 4, pp. 577–585, 1986.