

Clinical Study

Short-Term Effects of Radiotherapy Postquadrantectomy on Internal Mammary Artery and Vein

Mario Cherubino, Stefano Scamoni, Dominic Taibi, Francesca Maggiulli, Igor Pellegatta, Matteo Izzo, and Luigi Valdatta

Division of Plastic and Reconstructive Surgery, University of Insubria, Ospedale di Circolo e Fondazione Macchi, Viale Borri 57, 21100 Varese, Italy

Correspondence should be addressed to Francesca Maggiulli; francesca.maggiulli@live.it

Received 6 December 2012; Accepted 3 February 2013

Academic Editors: R. K. Chan, H. Fansa, M. Okazaki, and Z. Panthaki

Copyright © 2013 Mario Cherubino et al. This is an open access article distributed under the Creative Commons Attribution License, which permits unrestricted use, distribution, and reproduction in any medium, provided the original work is properly cited.

When a tumor local recurrence occurs a possible approach can be a mastectomy with simultaneous breast reconstruction with autologous tissue. The area involved by tangential radiation portals includes also the internal mammary artery and veins, considered by the most part of plastic surgeons to be the best recipient vessels for a free flap in breast reconstruction. Internal mammary vessels receives low but not necessary insignificant doses during whole breast irradiation; arteries and veins are traditionally considered quietly resistant to the irradiation but limited data on the flux in mammary vessels after radiotherapy are available. The goal of our study (37 patients from September 2011 to February 2012) was to evaluate modifications in vascular parameters of the flux at ultrasonography in the internal mammary chain after adjuvant radiotherapy that could influence the choice of the autologous surgical technique (free or pedicled flap) and the choice of the recipient vessels in breast reconstruction. Based on the results of our study, we would recommend avoiding an irradiated recipient site when no irradiated recipient vessels are available; a preoperative ultrasound evaluation is recommended in patients underwent whole breast irradiation.

1. Introduction

A breast conserving strategy in the treatment of breast carcinoma includes surgery, radiotherapy (RT), and/or chemotherapy and/or hormonal therapy. The possibility to achieve results in terms of overall survival is comparable to mastectomy [1–4], while providing cosmetic and psychological satisfaction to patients [5] makes this approach more and more popular. When a tumor local recurrence occurs a possible approach can be a mastectomy with simultaneous breast reconstruction.

The area involved by tangential radiation portals includes also the internal mammary artery and veins, considered by the most part of plastic surgeons to be the best recipient vessels for a free flap in breast reconstruction [6–8].

The complications associated with the use of radiation therapy (radiodermatitis, swelling and proliferation of the endothelium, cardiac and lung damage, lymphedema,

brachial plexopathy, impaired shoulder mobility, and second malignancies) are well known [9].

Internal mammary vessels receive low but not necessary insignificant doses during whole breast irradiation; arteries and veins are traditionally considered quietly resistant to the irradiation, but limited data on the flux in mammary vessels after radiotherapy are available.

Radiation dose to the breast could be detrimental for the mammary chain and compromise the use of these vessels as recipient for a free flap in breast reconstruction surgery. The success of a free flap depends on the reliability of blood vessels at the recipient site.

First Gasman in 1899 then Windholz [10] in 1937 described prominent intimal proliferation in irradiated arteries accompanied by partial obliteration of the lumen and complete obliteration of the vein. Subsequently several studies were done to evaluate radiation-induced arterial injuries [11–13].

The purpose of this study was to evaluate if there were modifications in some parameters of the internal mammary artery and vein at 3 and 6 months after adjuvant radiotherapy postquadrantectomy. According to the fact that hypertension, diet, smoke, and other factors may play an additive role in the development of the late degenerative changes following arterial irradiation [14, 15], we evaluated if parameters like age, smoke, and histological type of cancer could influence variations in the vascular internal mammary chain.

2. Material and Method

From September 2011 to February 2012, thirty-seven women underwent radiotherapy after breast conserving surgery for newly diagnosed invasive breast cancer. Patients' age ranged from 30 to 69 years old (average 54.7). Twenty-eight (75.70%) were nonsmokers or smokers of less than 5 cigarettes/die. Twenty-five (67.56%) had a ductal cancer, seven (18.91%) a lobular cancer, two (5.40%) an intraductal cancer, one (2.71%) a tubular, one (2.71%) a colloid, and one (2.71%) a papillary cancer (Figure 1).

Thirty patients (81.0%) had T1, six patients (16.2%) had T2 and one patient (2.8%) had T3 disease. Twenty-eight patients (75.7%) presented no nodal involvement, whereas seven patients (18.9%) had N1, and two patients (5.4%) had N2. Patient distribution according to tumor location is summarised in Table 1.

Thirty patients underwent axillary lymph node dissection and four patients underwent sentinel lymph node biopsy. Thirty-two patients received hormonal therapy; nine patients received chemotherapy.

In regard to radiotherapy, in all patients the whole breast was irradiated with 50 Gray (Gy) at 2 Gy per fraction using 2 tangential oblique opposed photon beams of 6 Megavolt (MeV). In all patients, a tumor bed boost was added of 10 Gy at 2 Gy per fraction using single en-face electron beam of energy ranging from 6 MeV to 16 MeV. In 5 patients electron boost was directed to tumor bed at the superior internal quadrant; in 9 patients tangential portals target internal mammary chain region. The radiation dose was assessed to the mammary vessels at the third intercostals space in all patients with a 3D-treatment planning system only for irradiation of whole breast; mean total dose was 1.9 Gy (range 1.1–3.4 Gy).

Evaluation of internal mammary arteries and veins was performed at the third intercostal space on the radiated side one week before surgery, after 3 and 6 months from the last application of radiation therapy. We used a color Doppler sonogram Philips ATL 5000, with probe frequencies of 7 and 12 MHz, and the Sequoia Siemens unit, with a probe of 8 MHz. Blood parameters were determined at the third intercostal space by the same radiologist. A test group of 20 patients (not used in the final statistic analysis) was used to standardize and establish consistency in the results. Radiation portals and explicative variables (smoker/nonsmoker, histological types and type of surgery) were not divulged to the two radiologists. Color Doppler and spectral analysis of the internal mammary chain were obtained. Measurement of

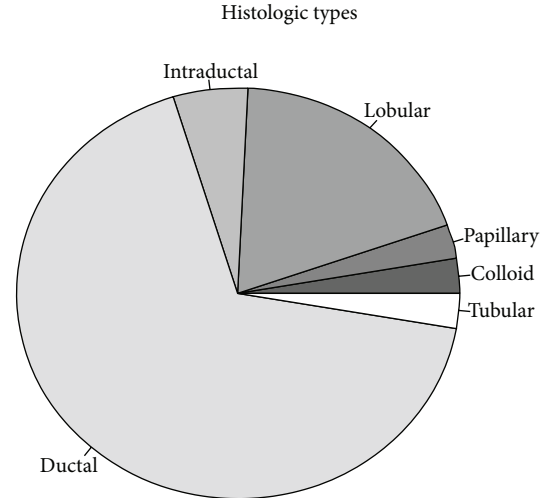


FIGURE 1: Breast cancer histological types.

TABLE 1: Patient distribution according to tumor location.

Tumor location	No. of location
Superior internal	5
Superior external	22
Central	4
Inferior internal	4
Inferior external	2

the vessel diameter, maximal and minimal velocity, and resistive index in the artery was recorded, while for the vein (the largest one found) we considered the diameter and the flow type (modulated/not modulated). Instantaneous arterial flow was calculated with the equation $Q = (D^2/4 \times \pi)V$ where Q is blood flow, D is vessel diameter, and V is maximal/minimal velocity. This was not possible for the vein because of the low velocity that is modulated also by the breath.

The analysis has been conducted using the freeware software (R, <http://www.r-project.org/>), an emulator of the commercial package S-Plus.

3. Results

The statistical analysis is about a series of quantitative response variables, monitored before radiotherapy following quadrantectomy and three and six months after. The explicative variables (Figures 2, 3, 4, 5, 6, 7, and 8; Table 2) on each patient are all qualitative except for age. The typical pattern we encounter shows an increase/decrease of the level of the variable at three months, while levels similar to the initial ones are approximately recorded six months after radiotherapy.

We used analysis of covariance to take into account patient age, while investigating differences among groups (smokers/nonsmokers and histological types) for each monitored variable. We found no differences in mean level among groups at 5% significance level for any investigated variable.

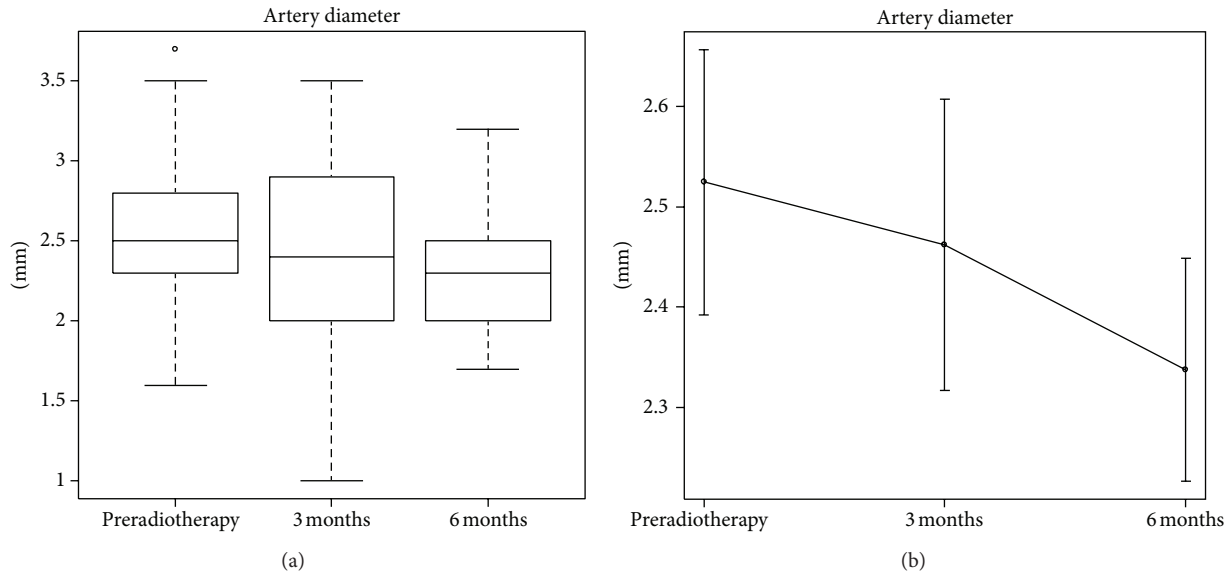


FIGURE 2: Artery diameter (mm).

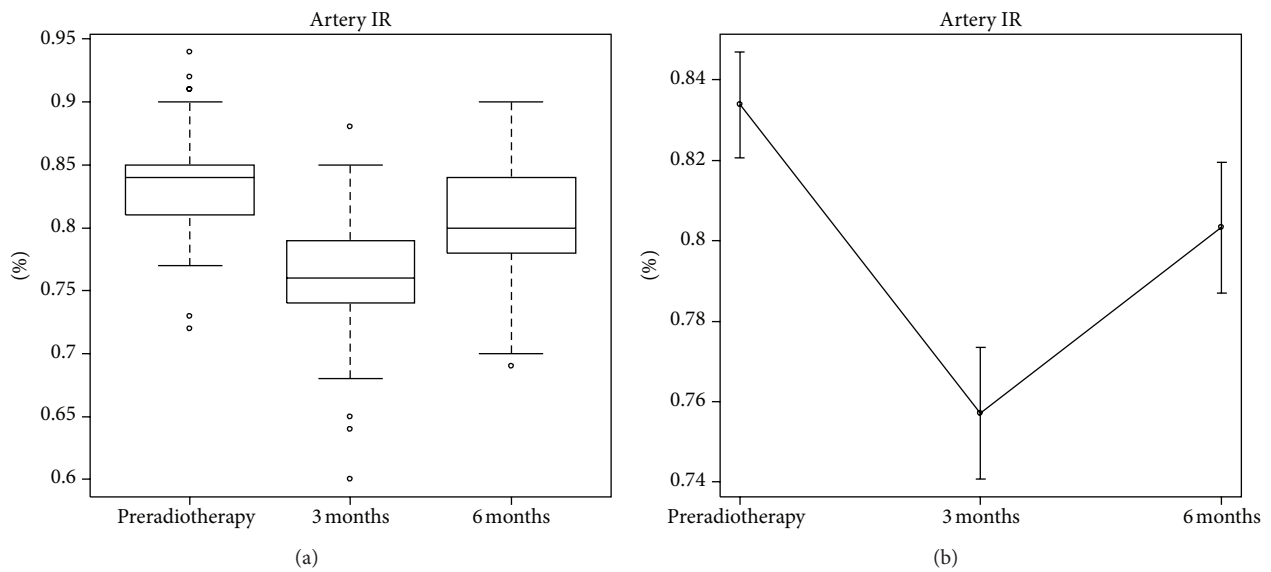


FIGURE 3: Artery resistive index (%).

We found a significant evolution of means of almost all variables over time. The pattern we found in minimum artery flow (P value = 0,001), maximum artery velocity (P value = 0.018), minimum artery velocity (P value \cong 0) shows an increase at 3 months after the operation, while after 6 months these variables return to preoperation levels (minimum artery flow P value = 0.382; maximum artery velocity P value = 0.167; minimum artery velocity P value = 0.509).

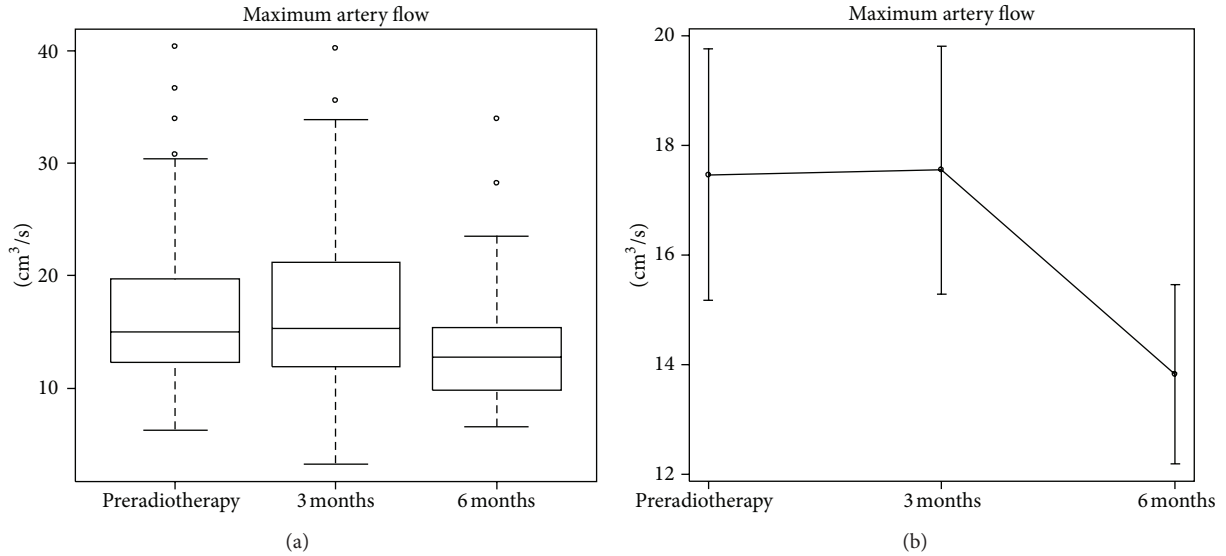
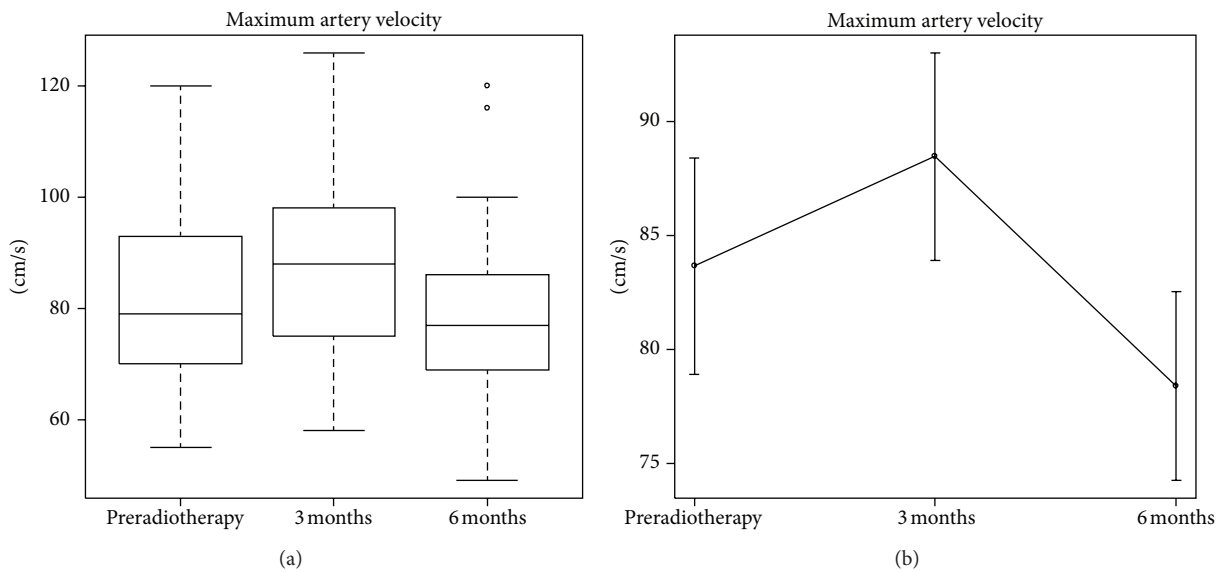
The other variables show different patterns among each other: artery diameter (P value = 0.027) and maximum artery flow (P value = 0.043) have a significant difference (decrease) six months after the operation; artery-IR after a decrease in its mean (P value \cong 0) has a recover not sufficient to reach its

initial mean (P value = 0,004), while vein diameter is the only variable that does not show any significant change in its mean level three (P value = 0.329) and six (P value = 0.328) months after the operation.

The vein blood flow was always modulated but in one case at three months.

4. Discussion and Conclusion

The possibility to diagnose breast cancer very early made the radiotherapy as adjunctive treatment after conservative surgery very popular. Unfortunately, women who underwent conservative surgery (quadrantectomy) and radiotherapy could have in future the oncologic necessity of a mastectomy.

FIGURE 4: Maximum artery flow (cm^3/s).FIGURE 5: Maximum artery velocity (cm/s).

The internal mammary and thoracodorsal vessels are the standard recipient vessels for the majority of surgeons performing free flap breast reconstruction [16–18].

Inadequate recipient vessels significantly contribute to flap thrombosis, requiring emergent operative exploration and flap failure.

In experimental studies in rabbit models, free-flap transfer using irradiated vessels has a higher failure rate, and the endothelium, the vessel wall, and perivascular tissue show histological radiation injury and fibrosis [19, 20].

Clinical studies demonstrated deleterious effects of radiation on muscle flaps: incidences of fat necrosis, fibrosis, and flap contracture were significantly higher in patients underwent pre- or postoperative radiotherapy [21–23].

The purpose of our study was to evaluate changes in the vascular internal mammary chain at the third intercostal space that could influence the choice of the autologous surgical technique (free or pedicled flap) and the recipient vessels in breast reconstruction. According to our results, we can record significant modifications in decrease after six months in artery diameter (-7.41%), IR (-3.61%), and maximum artery flow (-20.87%).

Using analysis of covariance, we can say that any prediction on the evolution of patient's conditions after breast operation and radiotherapy should be conducted irrespectively to the patient smoking habit and the histological type of cancer.

Clinical studies demonstrated that anastomotic failure and flap necrosis were significantly associated with delayed

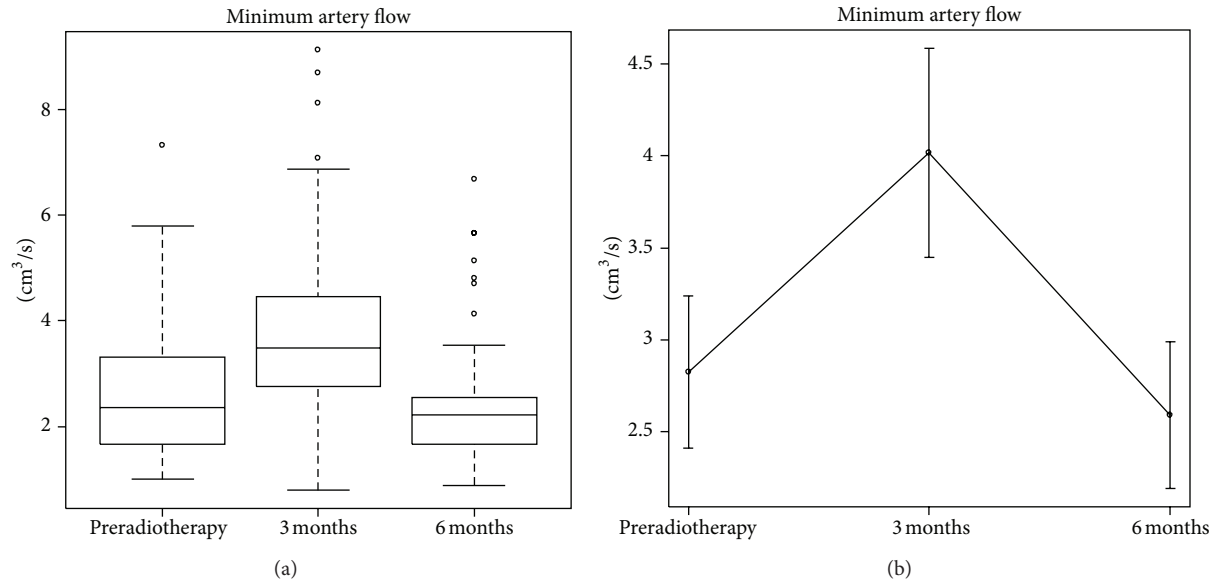


FIGURE 6: Minimum artery flow (cm^3/s).

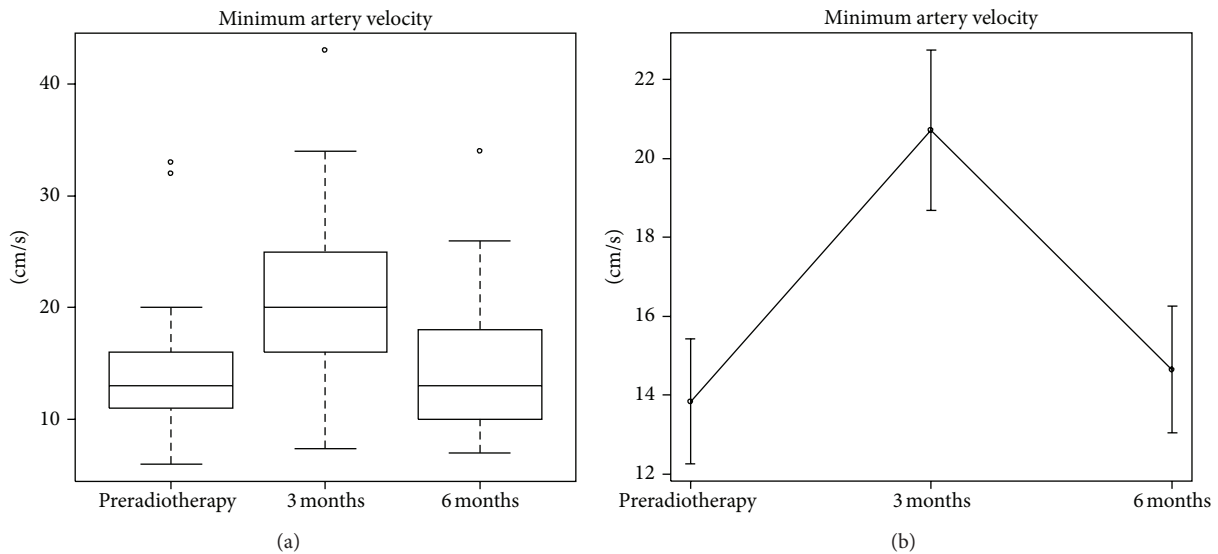


FIGURE 7: Minimum artery velocity (cm/s).

reconstruction, haematoma, previous lymph node dissection, and previous radiation therapy [24].

The internal mammary artery has a significant larger diameter and higher arterial flow rate than the thoracodorsal artery, while there is not a significant difference between the diameters of the internal mammary vein and the thoracodorsal vein. In spite of that the intake of blood in a free flaps supplied by the internal mammary artery is not greater than that in free flaps anastomosed to thoracodorsal vessels. The blood flow rate in the internal mammary artery is initially much higher in the thoracodorsal, but returned to the same level as initially in the deep inferior epigastric vessel, indicating that the internal mammary artery

does not guarantee better inflow to the flap than to the thoracodorsal.

The blood supply in a free flap is independent of the flow in the recipient artery, and thoracodorsal vessels are suitable for anastomosing a free flap as are internal mammary vessels. The intake of blood in a free flap is not dependent on the recipient artery flow but on the tissue components of the flap [25].

Complications related to radiations include radiodermatitis, poor wound healing, lymphedema, brachial plexopathy, cardiac and lung damage, swelling and proliferation of the endothelium, arteritis, fibrosis, and arterial and vein occlusive disease [9]. The morphologic and histological

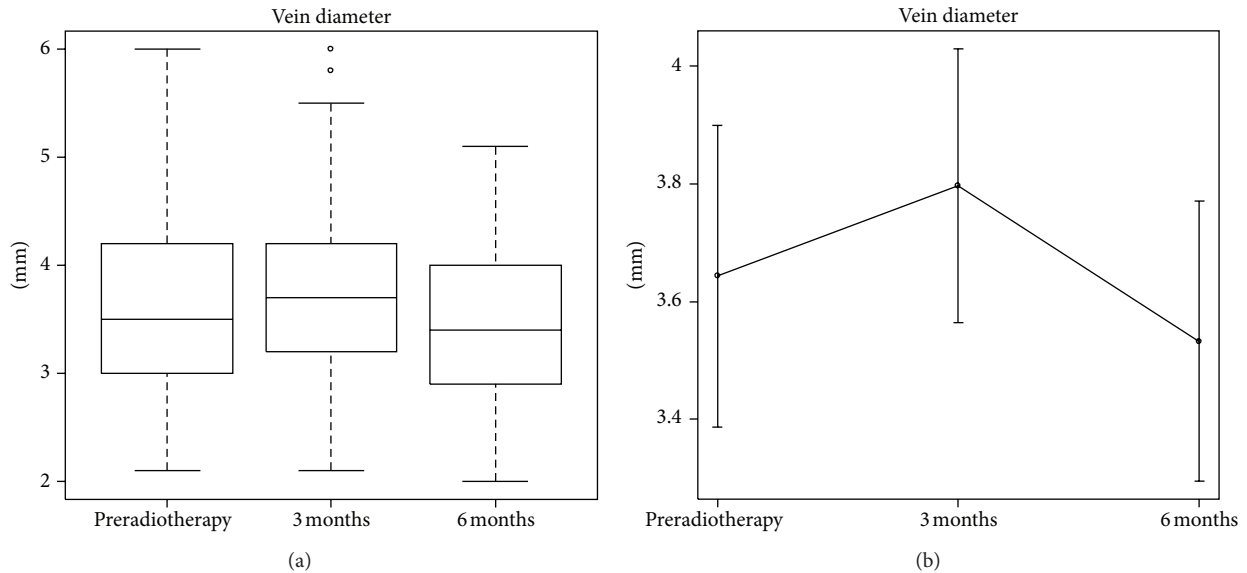


FIGURE 8: Vein diameter (mm).

TABLE 2: Temporal means.

Response variables	Preradiotherapy	3 months after	6 months after
Maximum artery flow (cm ³ /s)	17.46	17.55	13.82
Maximum artery velocity (cm/s)	83.65	88.46	78.38
Minimum artery flow (cm ³ /s)	2.83	4.02	2.59
Minimum artery velocity (cm/s)	13.83	20.72	14.65
Artery diameter (cm)	2.52	2.46	2.34
Vein diameter (cm)	3.64	3.80	3.53
Artery I.R.	0.83	0.76	0.80

effects of radiation injury to small and medium vessels are well known [10–12].

The availability and quality of recipient vessels are of particular importance concerning the reliability and success of reconstruction. The need for preoperative detection of suitable recipient vessels is evident to aid the surgical procedure and to avoid vascular complications, which are costly and time consuming in reconstructive efforts.

Based on the results of our study, we would recommend avoiding an irradiated recipient site when no irradiated recipient vessels are available.

In the delayed patients who previously received postoperative radiation therapy on the axilla, the internal mammary recipient site would be our first choice. These patients undergo preoperative inspection of vessels by color Doppler examination and by direct intraoperative dissection; in case of unusability of the internal mammary vessels for the anastomoses a pedicled flap should be performed [26].

In patients who previously received postoperative radiation therapy only on the internal mammary chain, the thoracodorsal recipient site would be preferred.

In patients who underwent quadrantectomy and postoperative radiation therapy on the whole breast, preoperative

color Doppler examination of any recipient vessel is mandatory; ultrasound imaging provides a noninvasive, repeatable, and practical method to investigate the suitability of recipient and donor vessels, with regard to topography and diameters, without any harm to the patients or the investigated vessels preoperatively [27].

References

- [1] M. M. Poggi, D. N. Danforth, L. C. Sciuto et al., "Eighteen-year results in the treatment of early breast carcinoma with mastectomy versus breast conservation therapy: the National Cancer Institute randomized trial," *Cancer*, vol. 98, no. 4, pp. 697–702, 2003.
- [2] B. Fisher, J. H. Jeong, S. Anderson, J. Bryant, E. R. Fisher, and N. Wolmark, "Twenty-five-year follow-up of a randomized trial comparing radical mastectomy, total mastectomy, and total mastectomy followed by irradiation," *New England Journal of Medicine*, vol. 347, no. 8, pp. 567–575, 2002.
- [3] U. Veronesi, N. Cascinelli, L. Mariani et al., "Twenty-year follow-up of a randomized study comparing breast-conserving surgery with radical mastectomy for early breast cancer," *New England Journal of Medicine*, vol. 347, no. 16, pp. 1227–1232, 2002.

- [4] R. Arriagada, M. G. Lê, F. Rochard, and G. Contesso, "Conservative treatment versus mastectomy in early breast cancer: patterns of failure with 15 years of follow-up data," *Journal of Clinical Oncology*, vol. 14, no. 5, pp. 1558–1564, 1996.
- [5] H. Bartelink, F. Van Dam, and J. Van Dongen, "Psychological effects of breast conserving therapy in comparison with radical mastectomy," *International Journal of Radiation Oncology Biology Physics*, vol. 11, no. 2, pp. 381–385, 1985.
- [6] O. Quaba, A. Brown, and H. Stevenson, "Internal mammary vessels, recipient vessels of choice for free tissue breast reconstruction?" *British Journal of Plastic Surgery*, vol. 58, no. 6, pp. 881–882, 2005.
- [7] L. J. Feng, "Recipient vessels in free-flap breast reconstruction: a study of the internal mammary and thoracodorsal vessels," *Plastic and Reconstructive Surgery*, vol. 99, no. 2, pp. 405–416, 1997.
- [8] M. Saint-Cyr, A. Youssef, H. W. Bae, G. L. Robb, and D. W. Chang, "Changing trends in recipient vessel selection for microvascular autologous breast reconstruction: an analysis of 1483 consecutive cases," *Plastic and Reconstructive Surgery*, vol. 119, no. 7, pp. 1993–2000, 2007.
- [9] E. Senkus-Konefka and J. Jassem, "Complications of breast-cancer radiotherapy," *Clinical Oncology*, vol. 18, no. 3, pp. 229–235, 2006.
- [10] R. Windholz, "Zur Kenntnis der Blutgefäßveränderungen in roentgenbestrahltem Gewebe," *Strahlentherapie*, vol. 59, pp. 662–665, 1937.
- [11] M. J. Butler, R. H. S. Lane, and J. H. H. Webster, "Irradiation injury to large arteries," *British Journal of Surgery*, vol. 67, no. 5, pp. 341–343, 1980.
- [12] T. Katras, U. Baltazar, K. Colvett, D. Rush, J. Dunn, and P. Stanton, "Radiation-related arterial disease," *American Surgeon*, vol. 65, no. 12, pp. 1176–1179, 1999.
- [13] E. W. Fonkalsrud, M. Sanchez, R. Zerubavel, and A. Mahoney, "Serial changes in arterial structure following radiation therapy," *Surgery Gynecology and Obstetrics*, vol. 145, no. 3, pp. 395–400, 1977.
- [14] C. Hanet, E. Marchand, and A. Keyeux, "Left internal mammary artery occlusion after mastectomy and radiotherapy," *American Journal of Cardiology*, vol. 65, no. 15, pp. 1044–1045, 1990.
- [15] G. R. D. Evans, C. L. David, E. M. Loyer et al., "The long-term effects of internal mammary chain irradiation and its role in the vascular supply of the pedicled transverse rectus abdominis musculocutaneous flap breast reconstruction," *Annals of Plastic Surgery*, vol. 35, no. 4, pp. 342–348, 1995.
- [16] Z. M. Arnež, L. Valdatta, M. P. Tyler, and F. Planinšek, "Anatomy of the internal mammary veins and their use in free TRAM flap breast reconstruction," *British Journal of Plastic Surgery*, vol. 48, no. 8, pp. 540–545, 1995.
- [17] S. L. Moran, G. Nava, A. H. Benham, and J. M. Serletti, "An outcome analysis comparing the thoracodorsal and internal mammary vessels as recipient sites for microvascular breast reconstruction: a prospective study of 100 patients," *Plastic and Reconstructive Surgery*, vol. 111, no. 6, pp. 1876–1882, 2003.
- [18] C. L. F. Temple, E. A. Strom, A. Youssef, and H. N. Langstein, "Choice of recipient vessels in delayed TRAM flap breast reconstruction after radiotherapy," *Plastic and Reconstructive Surgery*, vol. 115, no. 1, pp. 105–113, 2005.
- [19] J. S. Watson, "Experimental microvascular anastomoses in irradiated vessels. A study of the patency rate and the histopathology of healing," *Plastic and Reconstructive Surgery*, vol. 63, no. 4, pp. 525–533, 1979.
- [20] C. Krag, G. De Rose, and T. Lyczakowski, "Free flaps and irradiated recipient vessels: an experimental study in rabbits," *British Journal of Plastic Surgery*, vol. 35, no. 3, pp. 328–336, 1982.
- [21] N. E. Rogers and R. J. Allen, "Radiation effects on breast reconstruction with the deep inferior epigastric perforator flap," *Plastic and Reconstructive Surgery*, vol. 109, no. 6, pp. 1919–1924, 2002.
- [22] J. K. Williams, G. W. Carlson, J. Bostwick, J. T. Bried, and G. Mackay, "The effects of radiation treatment after TRAM flap breast reconstruction," *Plastic and Reconstructive Surgery*, vol. 100, no. 5, pp. 1153–1160, 1997.
- [23] N. V. Tran, G. R. D. Evans, S. S. Kroll et al., "Postoperative adjuvant irradiation: effects on transverse rectus abdominis muscle flap breast reconstruction," *Plastic and Reconstructive Surgery*, vol. 106, no. 2, pp. 318–320, 2000.
- [24] M. Y. Nahabedian, B. Momen, and P. N. Manson, "Factors associated with anastomotic failure after microvascular reconstruction of the breast," *Plastic and Reconstructive Surgery*, vol. 114, no. 1, pp. 74–82, 2004.
- [25] F. Lorenzetti, H. Kuokkanen, K. Von Smitten, and S. Asko-Seljavaara, "Intraoperative evaluation of blood flow in the internal mammary or thoracodorsal artery as a recipient vessel for a free TRAM flap," *Annals of Plastic Surgery*, vol. 46, no. 6, pp. 590–593, 2001.
- [26] G. R. D. Evans, C. L. David, E. M. Loyer et al., "The long-term effects of internal mammary chain irradiation and its role in the vascular supply of the pedicled transverse rectus abdominis musculocutaneous flap breast reconstruction," *Annals of Plastic Surgery*, vol. 35, no. 4, pp. 342–348, 1995.
- [27] A. H. Schwabegger, G. Bodner, M. Rieger, W. R. Jaschke, and M. M. Ninkovic, "Internal mammary vessels as a model for power Doppler imaging of recipient vessels in microsurgery," *Plastic and Reconstructive Surgery*, vol. 104, no. 6, pp. 1656–1661, 1999.