

Otolaryngology -- Head and Neck Surgery

<http://oto.sagepub.com/>

Supracricoid Partial Laryngectomy in the Management of T3 Laryngeal Cancer

Giuseppe Mercante, Alberto Grammatica, Paolo Battaglia, Giovanni Cristalli, Raul Pellini and Giuseppe Spriano

Otolaryngology -- Head and Neck Surgery 2013 149: 714 originally published online 6 August 2013

DOI: 10.1177/0194599813500018

The online version of this article can be found at:

<http://oto.sagepub.com/content/149/5/714>

Published by:



<http://www.sagepublications.com>

On behalf of:



[American Academy of Otolaryngology- Head and Neck Surgery](http://www.aao-hns.org)

Additional services and information for *Otolaryngology -- Head and Neck Surgery* can be found at:

Email Alerts: <http://oto.sagepub.com/cgi/alerts>

Subscriptions: <http://oto.sagepub.com/subscriptions>

Reprints: <http://www.sagepub.com/journalsReprints.nav>

Permissions: <http://www.sagepub.com/journalsPermissions.nav>

>> [Version of Record](#) - Nov 4, 2013

[OnlineFirst Version of Record](#) - Aug 6, 2013

[What is This?](#)

Supracricoid Partial Laryngectomy in the Management of T3 Laryngeal Cancer

Giuseppe Mercante, MD¹, Alberto Grammatica, MD¹,
 Paolo Battaglia, MD¹, Giovanni Cristalli, MD¹, Raul Pellini, MD¹,
 and Giuseppe Spriano, MD¹

Otolaryngology—
 Head and Neck Surgery
 149(5) 714–720
 © American Academy of
 Otolaryngology—Head and Neck
 Surgery Foundation 2013
 Reprints and permission:
sagepub.com/journalsPermissions.nav
 DOI: 10.1177/0194599813500018
<http://otojournal.org>



No sponsorships or competing interests have been disclosed for this article.

Abstract

Objective. To evaluate the oncologic results only in T3 glottic and supraglottic cancers regarding supracricoid partial laryngectomy (SCPL) not requiring total laryngectomy and to assess functional results by self-evaluation by the patient.

Study Design. Case series with medical record review.

Setting. Single tertiary care center.

Subjects and Methods. Thirty-two patients with laryngeal squamous cell carcinoma, previously untreated, who underwent SCPL with cricohyoidopexy or cricohyoidoepiglottopexy were reviewed.

Results. At 1, 3, and 5 years, the disease-free survival rates were 96.9%, 89.4%, and 78.2%; overall survival rates were 96.9%, 93.2%, and 87.3%; local control and locoregional control rates were 100%, 96.2%, and 96.2%; and distant metastasis-free survival rates were 100%, 100%, and 88.2%, respectively. Aspiration pneumonia was the most common complication observed. The 3 laryngeal functions (speech, swallowing, and breathing) were spared in 83.9% of patients.

Conclusion. Supracricoid partial laryngectomy for selected glottic and supraglottic T3 tumors has excellent oncologic and functional results.

Keywords

laryngeal cancer, supracricoid partial laryngectomy, glottic cancer, supraglottic cancer, T3

Received April 18, 2013; revised June 26, 2013; accepted July 12, 2013.

Supracricoid partial laryngectomies (SCPLs) were first used for T1-T2 glottic and glottic-supraglottic cancers.¹⁻⁵ In the past 20 years, SCPLs have been adopted less in T1-T2 cancers because several studies have reported good survival and functional results by transoral laser surgery (TLS) or radiotherapy (RT). Recently, TLS has been suggested for T3 laryngeal cancer as well.^{6,7} After the publication of a study by the Department of Veterans Affairs

Laryngeal Cancer Study Group (VA)⁸ and following the RTOG91-11 studies,⁹ total laryngectomy (TL) has been used less as a primary treatment for advanced laryngeal T3-T4 cancers because these studies showed that chemoradiotherapy (CRT) had a good laryngeal preservation rate. Nevertheless, some authors were concerned about the CRT strategy for advanced laryngeal cancers because of the global decrease in the survival rate compared with TL, especially in T3 cancers, and the impairment of function even in the presence of anatomical organ preservation.¹⁰⁻¹³

Therefore, in the large T3 “family,” these tumors may have different therapeutic solutions—TLS,^{6,7} RT,¹⁴ CRT,^{8,9} and TL—and SCPLs may deserve their own role within them. Functional results of SCPLs are well documented in the literature both as primary¹⁵⁻¹⁷ and salvage treatment,¹⁸⁻²¹ but few data have been reported on the oncologic results in T3 cancer after SCPLs.^{3,22-25}

The oncologic value of this procedure has been assessed by grouping different stages of the tumor. Conversely, it would be important to consider the outcome for patients with equivalent tumors using different treatment modalities. Radiotherapy associated or not with chemotherapy for organ preservation in a candidate for TL is preferably with category 1, in accordance with the recommendation cited in the National Comprehensive Cancer Network (NCCN) guidelines,²⁶ while the same option in a resectable tumor through conservative surgery merits discussion.

The aim of this study was to evaluate the oncologic results only in T3 glottic and supraglottic cancers regarding SCPL not requiring TL. The second aim of the study was to assess functional results by self-evaluation from the patient.

Patients and Methods

We retrospectively reviewed the medical records of consecutive patients with laryngeal squamous cell carcinoma,

¹Department of Otolaryngology–Head and Neck Surgery, Regina Elena National Cancer Institute, Rome, Italy

Corresponding Author:

Giuseppe Mercante, Department of Otolaryngology–Head and Neck Surgery, Regina Elena National Cancer Institute, Via Elio Chianesi 53, 00144, Rome, Italy.
 Email: mercante.giuseppe@gmail.com

previously untreated, cured with SCPL between 2003 and 2012 at the Regina-Elena National Cancer Institute in Rome, Italy. This study was approved by the National Cancer Institute Institutional Review Board.

Of 86 patients who underwent SCPL, we selected 32 affected by T3 laryngeal cancer. All cases were discussed with our disease management team. When alternative treatments were possible, we usually offered different options to patients who made the choice. The surgical technique was performed according to the technique originally described in the literature, using cricohyoidepiglottopexy (CHEP) or cricohyoidopexy (CHP) while considering tumor location and extension.^{1,2,4,5} All patients underwent spirometry for pulmonary evaluation. Adequate pulmonary reserve was considered mandatory to tolerate the increased postoperative aspiration. Patients with severe chronic obstructive pulmonary disease and impairment of the cough reflex were considered unsuitable for SCPL.

All patients underwent simultaneous monolateral/bilateral neck dissection, selective (II-IV) or modified radical (II-V), according to the site of T and the status of N. The demographic and clinical data of the patients are reported in **Table I**. The disease was reclassified in all patients according to the Union for International Cancer Control–TNM classification.²⁷

Nasogastric feeding tube (NGT) was always placed, and tracheostomy was always performed. The tracheostomy tube was removed and the stoma was closed if the patient tolerated it well without dyspnea. The NGT was removed after the patient regained swallow function of both solids and liquids without aspiration, under speech therapist supervision.

Postoperative RT was indicated for pT4a, a minimum of 2 positive nodes without extracapsular spread (ECS+), or both. Chemoradiotherapy was indicated for nodal ECS+.

The end points of the study were the relapses on T, N, and M affecting local control (LC), locoregional control (LRC), and distant metastasis (DM) rates, respectively, at years 1, 3, and 5. The survival was calculated as disease-free survival (DFS) and overall survival (OS) at years 1, 3, and 5. The complications that occurred after SCPL were also investigated and divided between intraoperative, early (≤ 30 postoperative days), and late (> 30 postoperative days) complications. For the functional outcome evaluation, the mean time of decannulation and NGT removal used breathing and swallowing recovery as indicators. Patient-related factors such as age and sex together with surgical-related factors (sparing 1 or both the arytenoids) were analyzed in relation to functional outcome. The early evaluation of speech was not done. The long-term results were assessed at least 6 months after surgery, interviewing each patient about his or her postoperative swallowing and evaluating the degree of postoperative aspiration according to the Leipzig²⁸ and Pearson²⁹ scales (1 = none, 2 = occasional cough but no clinical problems, 3 = constant cough worsening with meals or swallowing, 4 = pulmonary complications). The same criteria with the Leipzig²⁸ and Pearson²⁹ scales were adopted to evaluate speech (1 = excellent

Table I. Demographic and clinical data of the patients (n = 33).

Patient Characteristics	No. (%)
Sex	
Male	30 (94)
Female	2 (6)
Age, y	
Range	24-80
Median	64.8
Follow-up, mo	
Range	6-116
Median	47.3
T3 tumor subsite	
Glottis	24 (75)
Glottis/supraglottis	8 (25)
Pathological nodal stage	
N0	26 (82)
N1	3 (9)
N2b	3 (9)
Type of laryngectomy	
CHEP	14 (44)
CHP	18 (56)
Type of neck dissection	
HSND	17 (54)
BSND	9 (28)
SND + MRND	4 (14)
HMRND	1 (4)

Abbreviations: BSND, bilateral selective neck dissection (levels II-IV); CHEP, cricohyoidepiglottopexy; CHP, cricohyoidopexy; HMRND, homolateral modified radical neck dissection; HSND, homolateral selective neck dissection (levels II-IV); SND + MRND, selective neck dissection + modified radical neck dissection.

subjective speech, 2 = communication with voice primarily, 3 = occasional word or syllable produced, 4 = requires lip reading to understand sounds).

The variables were tested by the Pearson χ^2 test or Fisher exact test, when appropriate. Significance was defined at the $P \leq .05$ level. All survival curves were calculated by the Kaplan-Meier product-limit method SPSS software (version 20.0; SPSS, Inc, an IBM Company, Chicago, Illinois) and for all statistical evaluations.

Results

Thirty male (94%) and 2 female (6%) patients with a mean (SD) age of 62 (12) years (range, 24-80 years) fulfilled the inclusion criteria of the study. Twenty-four of 32 patients had glottic and 8 of 32 had glottic-supraglottic neoplasia. Supracricoid partial laryngectomy was performed with CHP in 18 (56%) cases and with CHEP in 14 (44%) cases. One arytenoid was spared in 29 (91%) cases, while both were spared in 3 (9%) cases. Patients were smokers in 28 (88%) cases and nonsmokers in 4 (12%) cases. All patients were clinically staged as T3: 27 (85%) N0, 3 (9%) N1, and 2 (6%) N2b. The final pathology report staged 7 (22%) cases

Table 2. Complications after supracricoid partial laryngectomy.

Complications (n)	Treatment	Results
Medical		
Early		
Aspiration pneumonia (4)	Medical therapy	1 cured 1 patient died on PO day 23 2 patients required PEG positioning
Late		
Neolarynx stenosis (2)	Repositioning of tracheostomy tube	Normalization of breathing
Aspiration pneumonia (1)	Medical therapy	Complete healing
Surgical		
Early		
Wound hematoma (3)	Surgical revision	Complete healing
Pharyngocutaneous fistula (1)	Dressings	Complete healing
Late		
None		

Abbreviations: PEG, percutaneous endoscopic gastrostomy; PO, postoperative.

as T2, 19 (59%) as T3, and 6 (19%) as T4a, as well as 26 (82%) as N0, 3 (9%) as N1, 3 (9%) as N2b. Perineural invasion was never observed. Surgical margins were always free of tumor. Postoperative RT was used in 2 (6%) patients (both pT4aN0), and postoperative CRT was used in 3 (9%) patients (1 with pT3pN2b and 2 with pT4apN2b, all with ECS+).

No intraoperative complications were observed. Eight (25%) patients had early complications (4 surgical and 4 medical). The 4 surgical complications were hematomas on the first postoperative day, which were treated with a surgical revision (3 cases), and the pharyngocutaneous fistula (1 case) was treated with dressings. Aspiration pneumonia was the early medical complication in 4 cases. One patient died of pneumonia after 23 days of recovery in the intensive care unit. Medical therapy was successfully administered in the other 3 cases, even when positioning of percutaneous endoscopic gastrostomy (PEG) tubes was required in 2. Three (9%) patients had late complications (2 cases of neolaryngeal stenosis and 1 case of aspiration pneumonia). All were treated by repositioning of a tracheostomy tube and with medical therapy (**Table 2**).

Follow-up after surgery varied from 6 to 116 months, with a median of 47.3 months.

The DFS rates at 1, 3, and 5 years were 96.9%, 89.4%, and 78.2%, respectively. The OS rates at 1, 3, and 5 years were 96.9%, 93.2%, and 87.3%, respectively (**Figure 1**).

One patient (3%) who developed a local recurrence after 16 months underwent CRT as salvage treatment and died of the disease. No recurrence on the neck was observed. Two (6%) patients had lung metastasis after 37 and 41 months. One of them survives after 20 months of chemotherapy, while the other died of the disease. Another patient (3%) was diagnosed for a second primary tumor on the lung. Twenty-three months after surgery, the patient was treated with surgery and still survives after 3 years without

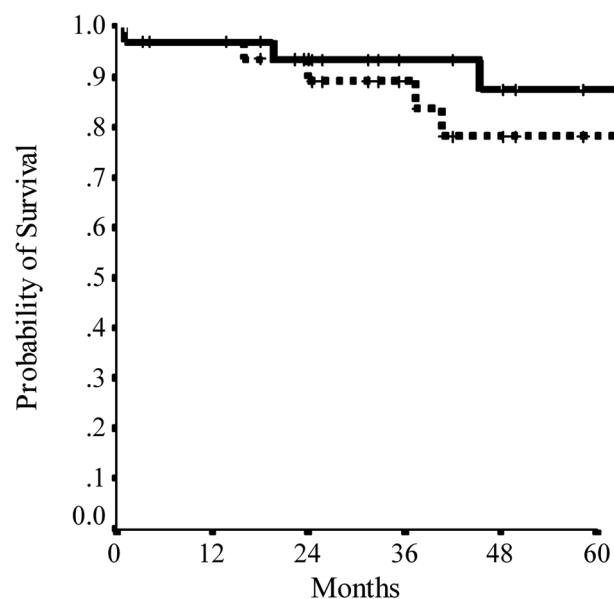


Figure 1. Survival in relation to time. Disease-free survival, dotted line; overall survival, solid line.

evidence of disease. Thus, the LC and the LCR rates at 1, 3, and 5 years were 100%, 96.2%, and 96.2%, respectively. The DM-free survival rates at 1, 3, and 5 years were 100%, 100%, and 88.2%, respectively (**Figure 2**).

Results of swallowing and speech of 31 live patients were assessed after 6 months of surgery once the postoperative healing process was completed. Decannulation was achieved in 28 of 31 (91%) patients. The 3 patients who maintained the tracheostomy tube had an edema of the neolarynx and did not tolerate the closure of the stoma. The mean (SD) decannulation time was 15 (10) days. The NGT was removed in all patients. Two (6%) patients were not able to swallow without aspiration and underwent PEG. The

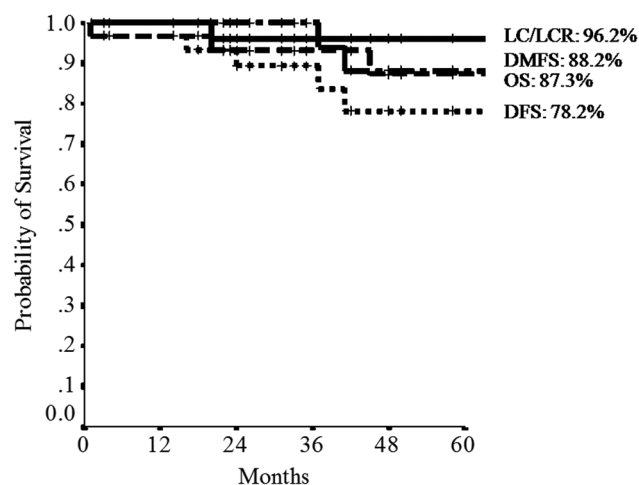


Figure 2. Survival and disease control in relation to time. DFS, disease free survival; OS, overall survival; LC, local control; LCR, local control rate; DMFS, distant metastasis-free survival.

mean (SD) time of NGT removal was 28 (19) days. The statistical analysis did not show any difference between decannulation and/or deglutition by age and sex as well as the type of surgery (SCPL with CHP/CHPEP) and the presence of 1 or both arytenoids.

Among the 31 patients evaluated for subjective aspiration and for assessment of swallowing by the Leipzig²⁸ and Pearson²⁹ scales, 21 (68%) were classified as group 1, 4 (13%) as group 2, 5 (16%) as group 3, and 1 (3%) as group 4. Of the 2 patients with PEG, 1 was in group 3 and 1 was in group 4. Both patients, due to good voice and breathing (grade 1), had preferred to maintain PEG and refused functional TL. Evaluation of speech with the Leipzig²⁸ and Pearson²⁹ scales showed grade 1 in 27 (87%) cases and grade 2 in 4 (13%).

Discussion

A wide consensus shows that oncological and functional results of glottic and supraglottic T1 (stage I) and T2 (stage II) tumors treated by TLS or RT are equivalent, reaching 80% to 95% of disease LC.^{17,30-34} The VA and RTOG91-11 studies^{8-9,35} evaluated RT and CRT as an alternative to TL for stage III/IV glottic and supraglottic advanced laryngeal cancer in terms of laryngeal preservation without survival detriment. The NCCN guidelines divide T3 laryngeal cancer into 2 categories regarding treatment options: “select T3 not requiring TL” and “most T3 requiring TL.” The NCCN guidelines indicate conservative surgery or RT alone for the “select T3 not requiring TL” group, while CRT is the best option with a category 1 recommendation for the “T3 requiring TL” group. Consequently, the T3 stage should be treated in 2 different ways according to whether TL is necessary. In practice, most institutions opt for CRT as the preferred nonsurgical option for T3 tumors. The risk for the patient is considered unsuitable for such a challenging surgical procedure, as SCPL is considered; as a

consequence, CRT could be a unique alternative to TL. A recent study showed that conservative surgery for T3 laryngeal cancer has yet to be considered an option.¹⁴ From the literature, 5-year DFS for advanced laryngeal cancer after RT or CRT varies between 28% and 58%.^{14,35} The best results are obtained in T3, even if only 50% to 80% of the survivors retain their larynx.^{8,14,35}

Hoffman et al¹⁰ reported a decrease in survival for laryngeal cancer, when the 1990s were compared with the 1980s, that can be related to the use of CRT. Olsen¹³ was concerned about a debatable laryngeal function despite anatomic preservation. Lefebvre and Ang³⁶ stressed the concept of excluding CRT patients who were candidates for a partial laryngectomy, excluding patients with pretracheotomy, and assessing the functional outcome of the preserved larynx. Careful evaluation of the potential effects on survival as well as the likelihood of retained function must precede the use of organ-preserving regimens for advanced-stage laryngeal cancer. Just as resection of a structure that can be cured oncologically and preserved functionally with nonsurgical treatment does not seem reasonable, resistance to excision of resectable tumors that are likely to have poor residual function after organ-preserving CRT regimens is similarly problematic. This is especially true in the latter instance if the nonsurgical approach has the potential to result in decreased survival or increased morbidity.³⁷

We reviewed the subgroup of patients classified as “select T3 not requiring TL” and submitted to SCPL, which represented 37% of all SCPLs performed in the same period and 23% of all T3 observed in the same period (32/139); all others were treated by TL, RT, or CRT. In this study, there were biases related to the selection of patients and tumors, but the decision on therapy, based on performance status, is important for candidates for SCPL as well as for CRT. The performance status score of candidates for SCPL or CRT is expected to be similar. For patients with those characteristics (cT3 amenable to SCPL) and without patient-related contraindications, the policy of the tumor board of our institution was to offer the patient a choice between SCPL and nonsurgical options. Thus, the bias present regarded patient preference.

We observed a 5-year DFS and OS of 78.2% and 87.3%, respectively. The LC and LCR at 5 years were 96.6%. This is the real value of the procedure, which is considered excellent. The decrease in OS was due to distant metastasis and second primary cancer. The high survival rate of glottic and supraglottic T3 laryngeal cancer confirms previously published papers.^{3,22,23} All patients maintained their larynx. Literature data may be influenced by the use of postoperative RT as reported by Lima et al.²² In their study, 62.5% of patients underwent adjuvant RT or CRT, and thus the real efficacy of the surgery can be hidden by adjuvant treatment. In our study, only 5 of 32 patients benefited from adjuvant treatment, and therefore the efficacy of surgery alone was tested in 85% of cases. We achieved 5-year LC, LCR, and DM-free survival rates of 96.2%, 96.2%, and 88.2%, respectively. Only 1 patient with local recurrence died after

refusing TL. The high rate of LC represents the greatest advantage of this technique compared with TLS. According to Blanch et al,³⁸ TLS is feasible in selected T3 laryngeal cancers with disease-specific survival and laryngectomy-free survival of 79.5% and 71.4% but with a local recurrence rate of 38%. Furthermore, in general, the selection of these T3 tumors suitable for endoscopic removal should be carried out with much caution.^{6,7} In contrast, SCPL has fewer limitations than TLS because it allows “en bloc” removal of the entire thyroid cartilage and its surrounding soft tissue structures, with wide surgical margins.

The nonsurgical alternative for these patients would be RT or CRT. The retrospective comparison is not feasible due to the bias in the selection of both approaches. In any case, such high rates of LC and OS are not reported in nonsurgical treatment series for T3.^{8,9,14}

Several controversies exist regarding neck dissection (ND) associated with SCPL due to the low rate of neck metastasis.²⁴ In the present study, all patients underwent an ND, even in N0 cases, due to the risk of occult nodal metastasis in T3. The evidence of pathologic nodes was 18%. We have had no regional failure or complications related to ND. The adopted policy (SCPL + ND) allowed us to have a final pathology report showing an over (19%) or under (22%) stage on T, documenting the exact number of lymph nodes affected and the presence of ECS+. As a result, it was possible to tailor the best adjuvant treatment for each patient.

Some authors have already demonstrated the acceptable functional results of the procedure.^{15,39,40} Good functional results translate into recovery of the 3 main functions of the larynx: voice, breathing, and swallowing. Our patients achieved good swallowing and speech ability as expected by the literature, even if early or late complications occurred in 34%. Speech was subjectively judged as satisfying. Other authors have demonstrated that speech is obviously worse compared with normal subjects.¹⁶ Twenty-eight of 31 cases were decannulated, and 3 still use a tracheostomy. Of the patients, 81% were able to swallow without any risk of developing pneumonia. Twelve percent had early surgical complications that were easily managed, while 15% had aspiration pneumonia that required medical therapy alone (1 case), medical therapy and repositioning of the tracheostomy tube (1 case), or medical therapy and positioning of PEG (2 cases). One patient was admitted at the intensive care unit for respiratory failure and died despite therapy. The mortality rate related to surgery was 3% (1/32). Forastiere et al⁹ reported an incidence of grade 3 or 4 late toxic effects of 24% to 36% in the RTOG91-11 study. In our study, 2 of 32 cases had an unexpected high incidence of severe dysphagia and still require PEG feeding, compared with 2 of 78 cases of salvage SCPL after RT failure documented in a previous study.²⁰ Permanent tracheostomy in 9% may seem a high incidence rate compared with similar reported cases, but the presence of a tracheostomy is also reported in nonsurgical studies.^{8,9}

The voice quality score was very good in our series according to the patients' judgment. However, worse voice scores resulted compared with nonsurgical reports.

In all the nonsurgical series using RT or CRT, the end point was survival and larynx preservation. Thus, the live patients were divided into 2 groups (with or without a larynx). All live patients in our series had a preserved larynx. However, 26 of 31 had all 3 functions restored, 29 of 31 had both breathing and voice preservation, and 28 of 31 had at least swallowing and voice restoration. The different functional results in similar studies may also be related to the type of SCPL. Lima et al²² reported one of the largest published series with 107 CHEPs of 110 SCPLs. In contrast, the number of CHPs and CHEPs was similar in our series, with 91% of patients having only 1 arytenoid preserved and all patients having ND. Therefore, different functional results must be related to these technical variables.

For T3 cancer, a comparison of functional results regarding SCPL in this study and RT or CRT in the literature is not feasible. Nevertheless, we should expect considerably more early complications than late ones with SCPL compared with RT and CRT and vice versa. In the present study, all surviving patients retained their larynx with a high LC rate. Data from published studies obviously cannot be compared, and a randomized prospective study comparing oncologic and functional outcomes of SCPL and RT or CRT in T3 cancer should be performed, despite the difficulty in obtaining a consensus from patients to be randomized in a surgical or nonsurgical arm.

Conclusions

Supracricoid partial laryngectomy for selected glottic and supraglottic T3 tumors has excellent oncologic and functional results. By far, the most common complication is aspiration pneumonia. Selection of patients and tumors represents a pivotal step toward achieving good results. In T3 laryngeal cancer, SCPL is an important treatment option to be included in the available armamentarium.

Acknowledgment

The authors acknowledge Ms Tania Merlino for the English language editing.

Author Contributions

Giuseppe Mercante, study design, data acquisition and analysis, data interpretation, drafting and revising manuscript, final approval; **Alberto Grammatica**, data acquisition and analysis, data interpretation, drafting and revising manuscript, final approval; **Paolo Battaglia**, study design, data acquisition and analysis, data interpretation, drafting and revising manuscript, final approval; **Giovanni Cristalli**, data analysis and interpretation, drafting and revising manuscript, final approval; **Raul Pellini**, data analysis and interpretation, drafting and revising manuscript, final approval; **Giuseppe Spriano**, study conception and design, data acquisition and analysis, data interpretation, drafting and revising manuscript, final approval.

Disclosures

Competing interests: None.

Sponsorships: None.

Funding source: None.

References

- Majer EH, Rieder W. Technic of laryngectomy permitting the conservation of respiratory permeability (cricohyoidopexy) [in French]. *Ann Otolaryngol*. 1959;76:677-681.
- Labayle J, Bismuth R. Total laryngectomy with reconstitution [in French]. *Ann Otolaryngol Chir Cervicofac*. 1971;88:219-228.
- Piquet JJ, Desauty A, Decroix G. Crico-hyoido-epiglottopexy: surgical technic and functional results [in French]. *Ann Otolaryngol Chir Cervicofac*. 1974;91:681-686.
- Laccourreye H, Laccourreye O, Weinstein G, Menard M, Brasnu D. Supracricoid laryngectomy with cricohyoidopexy: a partial laryngeal procedure for selected supraglottic and transglottic carcinomas. *Laryngoscope*. 1990;100:735-741.
- Laccourreye H, Laccourreye O, Weinstein G, Menard M, Brasnu D. Supracricoid laryngectomy with cricohyoidoepiglottopexy: a partial laryngeal procedure for glottic carcinoma. *Ann Otol Rhinol Laryngol*. 1990;99:421-426.
- Peretti G, Piazza C, Cocco D, et al. Transoral CO(2) laser treatment for T(is)-T(3) glottic cancer: the University of Brescia experience on 595 patients. *Head Neck*. 2010;32:977-983.
- Hinni ML, Salassa JR, Grant DG, et al. Transoral laser microsurgery for advanced laryngeal cancer. *Arch Otolaryngol Head Neck Surg*. 2007;133:1198-1204.
- Induction chemotherapy plus radiation compared with surgery plus radiation in patients with advanced laryngeal cancer. The Department of Veterans Affairs Laryngeal Cancer Study Group. *N Engl J Med*. 1991;324:1685-1690.
- Forastiere AA, Goepfert H, Maor M, et al. Concurrent chemotherapy and radiotherapy for organ preservation in advanced laryngeal cancer. *N Engl J Med*. 2003;349:2091-2098.
- Hoffman HT, Porter K, Karnell LH, et al. Laryngeal cancer in the United States: changes in demographics, patterns of care, and survival. *Laryngoscope*. 2006;116:1-13.
- Lefebvre JL. Laryngeal preservation in head and neck cancer: multidisciplinary approach. *Lancet Oncol*. 2006;7:747-755.
- Lefebvre JL. Surgery for laryngopharyngeal SCC in the era of organ preservation. *Clin Exp Otorhinolaryngol*. 2009;2:159-163.
- Olsen KD. Reexamining the treatment of advanced laryngeal cancer. *Head Neck*. 2010; 32:1-7.
- Al-Mamgani A, Tans L, van Rooij P, Levendag PC. A single-institutional experience of 15 years of treating T3 laryngeal cancer with primary radiotherapy, with or without chemotherapy. *Int J Radiat Oncol Biol Phys*. 2012;83:1000-1006.
- de Vincentiis M, Minni A, Gallo A, Di Nardo A. Supracricoid partial laryngectomies: oncologic and functional results. *Head Neck*. 1998;20:504-509.
- Alicandri-Ciuffelli M, Piccinini A, Grammatica A, et al. Voice and swallowing after partial laryngectomy: factors influencing outcome. *Head Neck*. 2013;35:214-219.
- Caicedo-Granados E, Beswick DM, Christopoulos A, et al. Oncologic and functional outcomes of partial laryngeal surgery for intermediate-stage laryngeal cancer. *Otolaryngol Head Neck Surg*. 2013;148:235-242.
- Spriano G, Pellini R, Romano G, Muscatello L, Roselli R. Supracricoid partial laryngectomy as salvage surgery after radiation failure. *Head Neck*. 2002;24:759-765.
- Makeieff M, Venegoni D, Mercante G, Crampette L, Guerrier B. Supracricoid partial laryngectomies after failure of radiation therapy. *Laryngoscope*. 2005;115:353-357.
- Pellini R, Pichi B, Ruscito P, et al. Supracricoid partial laryngectomies after radiation failure: a multi-institutional series. *Head Neck*. 2008;30:372-379.
- Deganello A, Gallo O, De Cesare JM, et al. Supracricoid partial laryngectomy as salvage surgery for radiation therapy failure. *Head Neck*. 2008;30:1064-1071.
- Lima RA, Freitas EQ, Dias FL, et al. Supracricoid laryngectomy with cricohyoidoepiglottopexy for advanced glottic cancer. *Head Neck*. 2006;28:481-486.
- Dufour X, Hans S, De Mones E, Brasnu D, Menard M, Laccourreye O. Local control after supracricoid partial laryngectomy for "advanced" endolaryngeal squamous cell carcinoma classified as T3. *Arch Otolaryngol Head Neck Surg*. 2004;130:1092-1099.
- Chevalier D, Laccourreye O, Brasnu D, Laccourreye H, Piquet JJ. Cricohyoidoepiglottopexy for glottic carcinoma with fixation or impaired motion of the true vocal cord: 5-year oncologic results with 112 patients. *Ann Otol Rhinol Laryngol*. 1997;106:364-369.
- Soudry E, Marmor Y, Hazan A, Marx S, Sadov R, Feinmesser R. Supracricoid partial laryngectomy: an alternative to total laryngectomy for locally advanced laryngeal cancers. *J Laryngol Otol*. 2008;122:1219-1223.
- Pfister DG, Ang K, Brockstein B, et al. NCCN practice guidelines for head and neck cancers. *Oncology*. 2000;14:163-194.
- Sobin LH GM, Wittekind C. *TNM Classification of Malignant Tumors*. 7th ed. New York, NY: John Wiley; 2009.
- Leipzig B. Neoglottic reconstruction following total laryngectomy: a reappraisal. *Ann Otol Rhinol Laryngol*. 1980;89:534-537.
- Pearson BW. Subtotal laryngectomy. *Laryngoscope*. 1981;91:1904-1912.
- Mendenhall WM, Amdur RJ, Morris CG, Hinerman RW. T1-T2N0 squamous cell carcinoma of the glottic larynx treated with radiation therapy. *J Clin Oncol*. 2001;19:4029-4036.
- Mendenhall WM, Parsons JT, Million RR, Fletcher GH. T1-T2 squamous cell carcinoma of the glottic larynx treated with radiation therapy: relationship of dose-fractionation factors to local control and complications. *Int J Radiat Oncol Biol Phys*. 1988;15:1267-1273.
- Mendenhall WM, Parsons JT, Stringer SP, Cassisi NJ. Management of Tis, T1, and T2 squamous cell carcinoma of the glottic larynx. *Am J Otolaryngol*. 1994;15:250-257.
- Ambrosch P. The role of laser microsurgery in the treatment of laryngeal cancer. *Curr Opin Otolaryngol Head Neck Surg*. 2007;15:82-88.
- Peretti G, Cappiello J, Nicolai P, Smussi C, Antonelli AR. Endoscopic laser excisional biopsy for selected glottic carcinomas. *Laryngoscope*. 1994;104:1276-1279.

35. Forastiere AA, Zhang Q, Weber RS, et al. Long-term results of RTOG 91-11: a comparison of three nonsurgical treatment strategies to preserve the larynx in patients with locally advanced larynx cancer. *J Clin Oncol*. 2013;31:845-852.
36. Lefebvre JL, Ang KK. Larynx preservation clinical trial design: key issues and recommendations—a consensus panel summary. *Int J Radiat Oncol Biol Phys*. 2009;73:1293-1303.
37. Cognetti DM, Randal SW, Lai SY. Head and neck cancer: an evolving treatment paradigm. *Cancer*. 2008;113:1911-1932.
38. Blanch JL, Vilaseca I, Caballero M, Moragas M, Berenguer J, Bernal-Sprekelsen M. Outcome of transoral laser microsurgery for T2-T3 tumors growing in the laryngeal anterior commissure. *Head Neck*. 2011;33:1252-1259.
39. Simonelli M, Ruoppolo G, de Vincentiis M, et al. Swallowing ability and chronic aspiration after supracricoid partial laryngectomy. *Otolaryngol Head Neck Surg*. 2010;142:873-878.
40. Pinar E, Imre A, Calli C, Oncel S, Katilmis H. Supracricoid partial laryngectomy: analyses of oncologic and functional outcomes. *Otolaryngol Head Neck Surg*. 2013;147:1093-1098.