

REVIEW

Current assessment of Hemospermia

Konstantinos Stamatiou¹, Gianpaolo Perletti^{2,3}, Vittorio Magri⁴, Hippocrates Moschouris⁵, Raffi Avakian¹, Nectaria Rekleiti⁶, Alberto Trinchieri⁷.

¹ Urology Dpt, Tzaneion Hospital, Piraeus, Greece

² Department of Biotechnology and Life Sciences, Section of Medical and Surgical Sciences, Università degli Studi dell'Insubria, Varese, Italy

³ Faculty of Medicine and Medical Sciences, Ghent University, Ghent, Belgium

⁴ Urology Secondary Care Clinic, ASST-Nord, Milan, Italy

⁵ Radiology Dpt, Tzaneion Hospital, Piraeus, Greece

⁶ Microbiology Dpt, Tzaneion Hospital, Piraeus, Greece

⁷ Urology Complex Unit, A. Manzoni Hospital, Lecco, Italy

Abstract

Introduction/Aim: Hemospermia is defined as the presence of red blood cells in the semen. Although hemospermia is a rare sign, its presence is annoying and worrisome for patients. In addition, it is often overlooked by healthcare professionals due to its short duration and to its presumably benign origin. Currently, there are no set guidelines regarding the evaluation of hemospermia that would allow a definitive diagnosis, and only limited evidence is available. The aim of this review is to investigate the current trends on the assessment and management of hemospermia.

Materials and Methods: The present review was based on a search in the relevant Greek and international bibliography. The PubMed database was searched for bibliographic data. The keywords used were "hemospermia" in combination with "etiology" and "treatment". Search was done by title, abstract or keywords.

Results: The actual incidence of hemospermia is unknown; however, it appears to be more common in men under the age of 40. It is usually a sign of short duration and is self-limited; hence, it often does not require further evaluation or treatment. When evaluated in men younger than 40 without risk factors, hemospermia is usually associated with benign causes and in the majority of cases responds well to treatment. In patients with risk factors and/or associated symptoms, hemospermia usually recurs and may not respond to treatment. In men over 40 years of age with persistent or recurrent hemospermia, systemic diseases and malignant conditions associated with hematospermia may be present. In rare cases hemospermia may be the only symptom of uncommon diseases.

Conclusions: Hemospermia has been linked with a variety of conditions. in-depth investigation may be intricate, and it should be performed in persistent or recurrent cases before definitive diagnosis.



Konstantinos Stamatiou, Gianpaolo Perletti, Vittorio Magri, Hippocrates Moschouris, Raffi Avakian, Nectaria Rekleiti, Alberto Trinchieri.
Current assessment of Hemospermia. *Hellenic Urology* 2019, 31(1): 52-60

Corresponding author:

Dr. Konstantinos Stamatiou

Urology Dpt, Tzaneion Hospital, Piraeus, Greece, e-mail: stamatiouk@gmail.com



Introduction

In normal conditions red blood cells are not detectable in the semen. Hemospermia (hematospermia), the presence of blood in the ejaculate, is a rather rare sign/symptom. Hemospermia is annoying and worrisome for patients, but is often overlooked as a minor symptom for which diagnostic investigation is not considered necessary. However, hemospermia may be associated with serious conditions like neoplasia and infection. Until recently hemospermia was considered primary in most cases, though a better understanding of the pathophysiology of the urogenital system and advances in medical imaging and laboratory techniques have made possible to determine an underlying cause to as much as 85% of the cases. Thus, cases that were attributable to excessive masturbation, to prolonged sexual abstention, or to intense sexual intercourse and were not considered significant were demonstrated to have a clinical background (e.g., prostatic lithiasis, infection or combination of the two). Yet, there are still unknown aspects of this condition, like for example its true incidence or underlying mechanisms hemospermia. The purpose of this study is to present the current knowledge about diagnosis and management of hemospermia.

Methods

The present review was based on a search in the relevant international bibliography. The PubMed database was searched for bibliographic data. The keywords used were "hemospermia/hematospermia" in combination with "etiology", "diagnosis", "workup" and "treatment". Search was done by title, abstract or keywords.

Results and discussion

1-Incidence

The exact incidence of hemospermia remains unknown as most men do not observe their sperm and therefore many episodes remain unnoticed. Moreover, it is difficult to quantify and to grade hemospermia as ejaculate is not always visible and measurable. It is also difficult to know the true relative frequency of the causes of hemospermia because patients present to healthcare workers after a single episode of hemospermia out of concern for malignancy or venereal disease. Moreover,

most publications tends to favour the reporting of new or unusual causes of hemospermia. The occurrence of hemospermia appears to be higher in men under the age of 40. In many cases (about 40%) hemospermia involves infectious or inflammatory conditions such as chronic prostatitis, epididymitis, orchitis and urethritis. Sexual attitudes are also often involved in the

generation of hemospermia (about 30%). The most important risk factors for hemospermia include a history of urogenital cancer, disorders of the urogenital system and coagulation disorders. Common causes include urogenital trauma, calcification of the seminal vesicles and prostate, history of radiation in the pelvic region, and urogenital cancer (prostate, testis and rarely bladder). Rarely, hemospermia is associated to local vascular malformations (such as distended veins in the prostatic urethra), systemic diseases (amyloidosis, lupus, etc.), chronic liver disease and hypertension. Causes (behavioral and non-behavioral) and underlying conditions generating hemospermia often concur with each other.

No specific guidelines exist for diagnosis and management of hemospermia, and only few diagnostic algorithms have been published up to date,,,,,,.

2-Causes

Urethritis (mainly caused by sexually transmitted pathogens such as *Chlamydia trachomatis*, *Ureaplasma urealyticum* or common pathogens such as *Enterococcus faecalis*) has been identified as a major cause of hemospermia, especially in younger men (Table 1). Some authors, however, suggest that hemospermia can be a manifestation of complicated urethritis. In such a case, urethral strictures are the main underlying factor for this condition. Epididymitis and orchitis are reputed to be the cause of late hemospermia in 30% of patients. Common pathogens and sexually transmitted pathogens are the source of infection. Other infectious causes include tuberculosis, HSV infection, HIV infection, and cytomegalovirus infection. Hemospermia in patients with urogenital tuberculosis ranges between 3.3 and 14% and shows geographical distribution. Schistosomiasis and Parasitic infection caused by *Echinococcus* have also been reported as causes of hemospermia,. Although viral papillomas are the most common neoplasms of the urethra (67.3%), they do not commonly cause urethral hemospermia. Few cases of hemospermia due to human papilloma virus (HPV) and Zika virus infections



Key words

Hemospermia, cancer, risk factors.



have been reported,

Hemospermia was found to be as the primary clinical manifestation in 26.2% of chronic prostatitis cases, though it is believed that more cases of prostatitis can present with associated hemospermia. In fact, the diagnostic procedure of patients presenting with hemospermia is usually limited to urinalysis with research for sexually transmitted infections, and does not include systematic methods for the evaluation of a potentially underlying chronic prostatitis. Thus, data focusing on the relationship between hemospermia and chronic prostate infection are scant. Two recent studies using powerful prostatitis assessment methods associated more than half (>50%) of hemospermia-assessed cases with underlying chronic prostatitis. The pathogens most commonly associated with hemospermia are *Staphylococcus aureus* and *Ureaplasma urealyticum*. Underlying conditions such as prostatic calcifications and granulomas may add to the risk for the development of prostatitis-associated hemospermia. In fact, prostatic calcifications are highly prevalent among patients with chronic prostatitis, and may often cause mechanical and chemical corrosive effects on the surrounding tissue. A TRUS-based study demonstrated a 47.05% incidence of periurethral calcifications and calcifications of the two glandular lobes in patients with hemospermia. Similarly, granulomas are believed to be caused by a blockage of prostatic ducts leading to stasis of prostate gland secretions, subsequently resulting in an inflammatory response. It has been demonstrated that hemospermia can be an accompanying symptom of xanthogranulomatous prostatitis in 40% of cases.

In a study by Yu and coworkers, inflammation and concomitant swelling of seminal vesicles were associated with up to 69.5% of cases of hemospermia. Hemospermia usually lasts several months and in a small percentage of cases (1.1%) recurs after treatment. In such a case, *struvite* (magnesium ammonium phosphate) stones within the seminal vesicles may be the main causative determinant.

Other risk factors include cysts and polyps of seminal vesicles, utricle cysts, as well as inflammation of the posterior urethra and prostate carcinoma³³.

Sexual attitudes such as excessive masturbation, prolonged sexual abstinence, and prolonged/interrupted sexual intercourses have been linked to hemospermia. Certainly, the role of sexual behavior as a cause of hemospermia is not easy to determine because its evaluation is based on patients' report and for this reason there are

limited studies examining this topic. The most possible explanation for blood in the ejaculate following excessive sexual intercourse or masturbation is the presence of a ruptured blood vessel, as the epididymal duct can become unable to recover its normal function after repeated ejaculations. Usually the condition resolves without any intervention in about 1-2 months. Cases of hemospermia due to prolonged sexual abstinence were shown to have an underlying clinical condition (e.g., prostatic lithiasis, infection or urethral venous malformation). However, in about half of these cases underlying conditions remained unknown, likely due to poor patient evaluation.

Urethral and prostatic teleangiomas and varicose veins of the bladder neck are rare vascular malformations which may be sometimes associated with hemospermia (10.3% of cases)²⁵. In these cases, hemospermia is accompanied by urethral haemorrhage and final hematuria (usually after sexual intercourse or intense exercise). In addition, haemospermia has been reported in a patient with congenital arteriovenous malformation of the internal iliac vessels.

Coagulation disorders related to hemospermia may be congenital or acquired. Congenital bleeding disorders such as haemophilia A, prothrombin deficiency, factor V deficiency and von Willebrand disease, rarely cause hemospermia which usually occurs when underlying conditions are present. While therapy with anticoagulants is a common cause of unwanted bleeding, only few cases of hemospermia associated with clopidogrel and aspirin use have been reported. Notably, low dose aspirin usage has not been associated with hemospermia in patients undergoing prostate biopsy.

Iatrogenic haemospermia may occur frequently after prostate or urethral surgery. The most common cause for such event is prostate biopsy regardless of the technique adopted, and its incidence according to bibliographic references is $\pm 50\%$. Iatrogenic haemospermia presents in a mild form and lasts for about one month (4 ± 1.4 weeks)⁷. According to some researchers, no clinical or pathologic parameter (e.g., serum PSA, DRE, Gleason score) can predict its appearance or duration⁴⁸, though the presence of prostatic calculi appears to be an independent risk factor. Ultrasonic guided transrectal implantation (i) of radionuclide markers into the prostate for image-guided radiotherapy of prostate cancer or (ii) of brachytherapy granules for the treatment of prostate cancer were associated with hemospermia in 3.2-13% of cases⁷. Transurethral prostatectomy (for treatment of benign prostatic hyperplasia) and pelvic radiation

Table 1 Aetiology of hemospermia

Infection (prostatitis, urethritis, epididymitis & orchitis):
>Bacterial (e.g. gonorrhoea, enterococcal, staphylococcal, Ureaplasma, Chlamydia, tuberculosis)
>Viral (e.g. human immunodeficiency virus -HIV, Cytomegalovirus -CMV, Herpes simplex virus -HSV)
>Parasitic (schistosomiasis)
Iatrogenic trauma or irritation
>Post-transrectal ultrasound (TRUS) biopsy
>Prostate radiotherapy or brachytherapy
>Post-prostatectomy
Non iatrogenic trauma or irritation
>Trauma
>Coital trauma
>Prolonged abstinence
Malignancy
>Prostate
>Bladder
>Testicles
>Urethra
>Seminal Vesicles
Obstruction
>Ductal obstruction
>Cysts of seminal vesicles/Wolffian duct/utricle
>Calculi of seminal vesicles, ejaculatory duct, prostate, urethra
Systemic disorders
>Hypertension
>Chronic liver disease
>Lymphoma
>Leukaemia
>Amyloidosis
>Bleeding disorders
>Idiopathic

(for treatment of bladder, prostate and rectal cancer) were linked with hemospermia in 2.5-17% of the cases. Sclerotherapy injections for haemorrhoid treatment, urethral trauma (iatrogenic or non-iatrogenic) caused by insertion of objects into the urethra, urethral injury

following male coital trauma and testicular and perineal injuries as well, were also found to induce hemospermia in a limited number of patients^{3,4}.

Benign urethral lesions such as papillary urethritis are more commonly associated with the occurrence of haemospermia (26%)⁵, compared to primary malignant lesions of the testicles, prostate (0.5-6.5%) and seminal vesicles (extremely rare). A case of adenomyosis and a case of squamous cell carcinoma of the seminal vesicle, as well as a case of metastasis to the seminal vesicles of renal cell carcinoma presenting with hemospermia have been also reported^{6,7}.

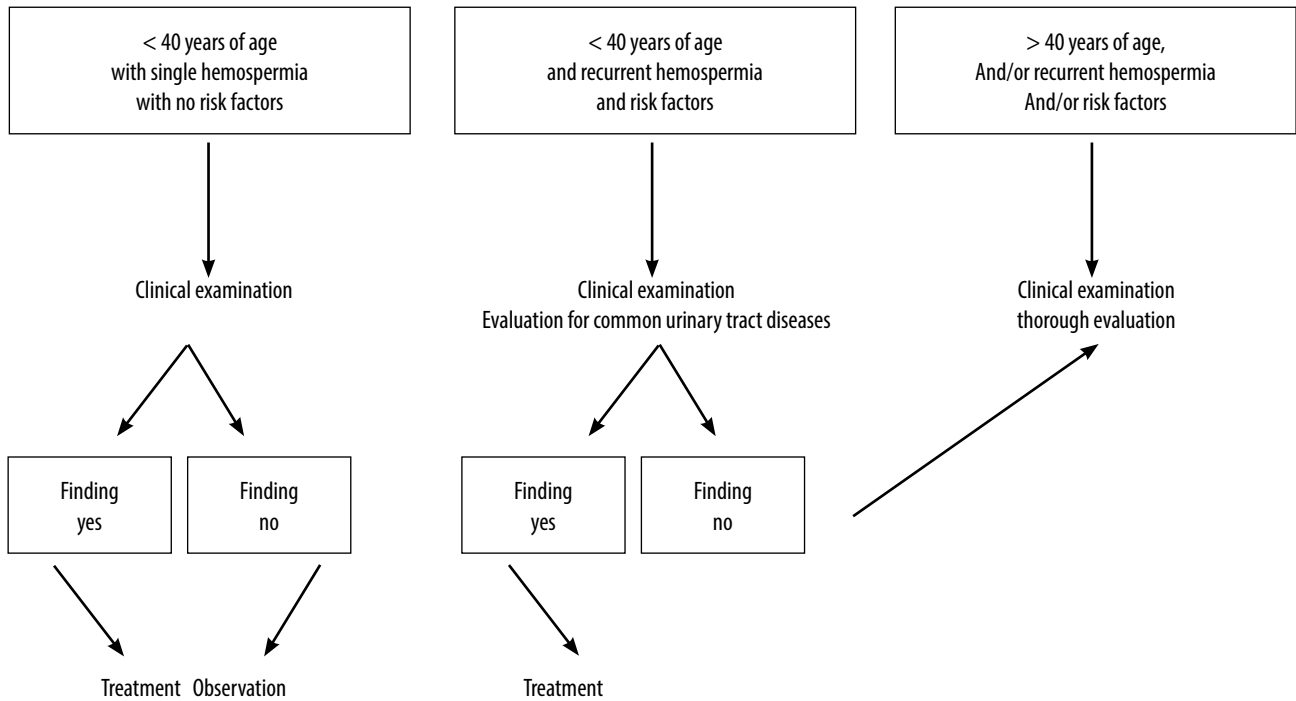
Systemic disorders that have been connected to hemospermia include malignant hypertension, chronic liver disease, amyloidosis, hyperuricemia and lymphoma. All of the above conditions have been reported in association with hemospermia as individual cases or in small numbers of patients⁸.

3-Differential diagnosis and clinical evaluation

Differential diagnosis includes cases of pseudo-hemospermia, manifesting in the form of sperm mixed with blood (origin: hematuria, menstruation of the sexual partner) or colored/stained semen (melanospermia due to the presence of melanin in the rare case of primary or metastatic melanoma in the prostate or seminal vesicles). Semen analysis may be useful for differentiating actual hemospermia from the above mentioned conditions⁹.

The aim of clinical evaluation is to identify the underlying causes of hemospermia. Because of the paucity of research literature, there is little evidence on which basis clinicians can evaluate patients with hemospermia. On one hand, accumulated evidence shows that hemospermia is more likely to be due to benign causes. On the other hand, individual cases and small cases series demonstrated that hemospermia can be caused by bladder, prostate or systemic malignancies. Given the variety of the aetiology and the rarity of certain causes, a "universal workup" of hematospermia can be cumbersome, time-consuming and less likely to be productive. Therefore, an efficient evaluation should equally focus on the patient (age, habits, sexual history, medication and medical history) and the symptom (presentation, seriousness, duration and associated symptoms). In men younger than 40 years of age, with no harmful habits, no medication intake, non-conclusive medical history, and in the absence of risk factors, hemospermia is almost never a sign of cancer, especially when it regresses

Figure 1 Algorithm for the hemospermia evaluation in absence of accompanying symptoms



spontaneously after a first episode⁵. In contrast, in men over 40 years of age having a risk factor (e.g. bleeding disorder, acquired anatomical abnormalities of the urogenital system) hemospermia is usually persistent or recurrent and may not respond to treatment⁴⁴. In such a case it is necessary to subject the patient to laboratory and instrumental tests in order to find an optimal treatment. Intermediate conditions, e.g. in patients under the age of 40 with limited incidents, are often evaluated for common urinary tract diseases⁴⁴.

Another factor that dictates the depth/extent of the evaluation and treatment is the concomitant presence of any associated symptom. Accompanying symptoms include local pain or discomfort, urinary symptoms or systemic symptoms such as tiredness or fatigue. They are usually associated with non-self-limiting situations requiring additional assessments. In particular, local pain or ejaculatory pain may be associated with prostatitis, urgency and painful urination may indicate urethritis, whereas a decreased volume of ejaculate is associated with prostatitis or obstruction of ejaculatory ducts. Concomitant haematuria may indicate malignancy of the bladder or prostate, as well as morphological abnormalities. On the other side, systemic symptoms (e.g. weight loss, night sweats, severe uncontrolled hypertension,

chills, bone pain) may indicate a severe neoplastic or infectious source.

Simple clinical examination may reveal elevated blood pressure, fever (that escaped the patient's attention) and indicates infection, malignancy or another systemic cause. Examination of the inguinal region may reveal lymph node enlargement associated with infection or urogenital tumors. Examination of the scrotum may reveal swelling of tumor of the epididymis or the testicle, while digital rectal examination of the prostate may show infection or tumor. The penis (foreskin and glans) should also be carefully examined to rule out any bleeding lesion, possibly contributing to hemospermia, and the urethral orifice should be examined for secretions in order to rule out urethritis⁷⁵.

A single episode of painless hemospermia in younger patients, with no associated symptoms and presenting after prolonged sexual intercourse is probably of benign origin. In such a case, hemospermia is usually self-limiting and further evaluation or treatment may be unnecessary. In contrast, patients with painful hemospermia and/or associated symptoms –especially those with risk factors- should undergo white blood count, biochemical tests, assessment of inflammation and cancer markers -including PSA- evaluation for

bleeding disorders (and coagulation studies if necessary), urinalysis and urine culture (for specific infections if necessary) with antibiogram, urine cytology, prostatic secretion and/or semen culture and cytology. If a sexually-transmitted infection is suspected, culture of urethral secretions and focused tests (e.g. nucleic acid amplification test for Chlamydia) should be performed. If tuberculosis or schistosomiasis are the suspected causes of hemospermia, urine and semen analysis for acid-fast bacilli and parasites could be performed.

Abdominal ultrasound may not be recommended as routine tests in patients initially presenting with hematospermia. However, ultrasound is necessary for evaluating older patients or those with persistent hemospermia or associated symptoms. In addition, scrotal ultrasound and TRUS are valuable for the visualization of testicles, seminal vesicles, prostate, and ampullary portions of the *vas deferens*⁶³. Simple or flexible cystoscopy, abdominal CT and MRI may be also required.

Figure 1 shows a simple algorithm for evaluation and management of hemospermia, in patients younger or older than 40 years, presenting with or without specific symptoms or risk factors.

Conclusions

On the basis of limited published evidence, particularly regarding the correlation of hemospermia with other, clinical recommendations are limited to level C (*limited evidence available*). Key factors in the evaluation of this condition are age, duration of symptoms and associated symptoms or risk factors.

>For patients under the age of 40 who have a single episode of hemospermia and no risk factors or associated symptoms, observation is usually the most appropriate management strategy.

>In men aged 40 years or over, patients who have associated symptoms or those who have persistent hematospermia, the evaluation should be more extensive and should include assessment for underlying prostate cancer.

>Men in whom an etiology is not elucidated require monitoring within three to six months to

Περίληψη

Εισαγωγή / Σκοπός: Με τον όρο αιμοσπερμία ονομάζεται η παρουσία ερυθρών αιμοσφαιρίων στο σπέρμα. Αν και είναι ένα σπάνιο σύμπτωμα, η παρουσία του είναι ενοχλητική και ανησυχητική για τους ασθενείς. Από την άλλη πλευρά, συχνά παραβλέπεται από τους επαγγελματίες

υγείας λόγω της σύντομης διάρκειας του συμπτώματος και της πιο πιθανής καλοήθους αιτιολογίας τους. Επί του παρόντος, δεν υπάρχουν καθορισμένες κατευθυντήριες γραμμές σχετικά με την αξιολόγηση της αιμοσπερμίας που θα επέτρεπαν την οριστική διάγνωση ενώ υπάρχουν μόνο περιορισμένα στοιχεία για ορισμένα από τα αίτια και την διάγνωσή τους. Σκοπός της παρούσας μελέτης είναι η διερεύνηση των σημερινών τάσεων στην αξιολόγηση της αιμοσπερμίας. Υλικό και Μέθοδος: Η παρούσα μελέτη είναι μια επισκόπηση με αναζήτηση στη σχετική ελληνική και διεθνή βιβλιογραφία και στις ηλεκτρονικές βάσεις δεδομένων για τα βιβλιογραφικά δεδομένα του PubMed. Οι λέξεις-κλειδιά που χρησιμοποιήθηκαν ήταν η αιμοσπερμία σε συνδυασμό με τους όρους αιτιολογία και τη θεραπεία. Η αναζήτηση έγινε με τίτλο, περίληψη ή λέξεις-κλειδιά (TITLE-ABSTRACT-KEYWORD).

**Λέξεις
ευρητηριασμού**
αιμοσπερμία, καρκίνος, παράγοντες κινδύνου

Αποτελέσματα: Η πραγματική συχνότητα εμφάνισης αιμοσπερμίας είναι άγνωστη. Ωστόσο, φαίνεται πιο συνηθισμένη στους άνδρες κάτω από την ηλικία των 40 ετών. Συχνά έχει μικρή διάρκεια και περιορίζεται αυτόματα και συνεπώς δεν απαιτεί περαιτέρω αξιολόγηση ή

θεραπεία. Όταν αξιολογείται, η αιμοσπερμία σε άνδρες ηλικίας κάτω των 40 ετών χωρίς παράγοντες κινδύνου συσχετίζεται συνήθως με καλοήθη αίτια και στην πλειονότητα των περιπτώσεων ανταποκρίνεται καλά στη θεραπεία. Σε ασθενείς με παράγοντες κινδύνου και / ή συνοδά συμπτώματα, η αιμοσπερμία συνήθως επανεμφανίζεται και μπορεί να μην ανταποκρίνεται στη θεραπεία. Σε άνδρες ηλικίας άνω των 40 ετών με επίμονη ή υποτροπιάζουσα αιμοσπερμία μπορεί να υπάρχουν συστηματικές ασθένειες και κακοήθεις καταστάσεις που σχετίζονται με αυτήν. Σε πολύ σπάνιες περιπτώσεις, η αιμοσπερμία μπορεί να είναι το μόνο σύμπτωμα ασυνήθιστων ασθενειών.

Συμπεράσματα: Η αιμοσπερμία έχει συνδεθεί με ποικίλες παθήσεις. Η έρευνα μπορεί να είναι δύσκολη, ωστόσο πρέπει να γίνεται σε επίμονα ή υποτροπιάζοντα περιστατικά πριν τεθεί οριστική διάγνωση.

References

1. Drake T, Hanna L, Davies M. Haemospermia. *BMJ*. 2016;355:i5124.
2. Papp GK, Kopa Z, Szabó F, Erdei E. Aetiology of haemospermia. *Andrologia*. 2003;35(5):317-320.
3. Ng YH, Seeley JP, Smith G. Haemospermia as a presenting symptom: Outcomes of investigation in 300 men. *Surgeon* 2013;11:35-38
4. Mulhall JP, Albertsen PC. Hemospermia: diagnosis and management. *Urology*. 1995;46(4):463-467
5. Weiss BD, Richie JP. Hematospermia. Uptodate, <https://www.uptodate.com/contents/hematospermia>, Visited: Mar 10, 2019
6. Leary FJ, Auguilo JJ. Clinical significance of haemospermia. *Mayo Clin Proc*. 1974;49:815-817.
7. Ahmad I, Krishna NS. Hemospermia. *J Urol* 2007;177:1613-18
8. Kumar P, Kapoor S, Nargund V. Haemospermia - a systematic review. *Ann R Coll Surg Engl*. 2006;88(4):339-42.
9. Dantanarayana N. Haemospermia. *Aust Fam Physician* 2015;44(12):907-910
10. Stefanovic KB, Gregg PC, Soung M. Evaluation and treatment of hematospermia. *Am Fam Physician*. 2009;80(12):1421-7.
11. Mathers MJ, Degener S, Sperling H, Roth S. Hematospermia - a Symptom With Many Possible Causes. *Dtsch Arztebl Int*. 2017;114(11):186-191.
12. Munkelwitz R, Krasnokutsky S, Lie J, Shah SM, Bayshtok J, Khan SA. Current perspectives on hematospermia: a review. *J Androl*. 1997;18(1):6-14.
13. Aslam MI, Cheetham P, Miller MA. A management algorithm for hematospermia. *Nat Rev Urol*. 2009;6(7):398-402.
14. Leocádio DE, Stein BS. Hematospermia: etiological and management considerations. *Int Urol Nephrol*. 2009;41(1):77-83.
15. Tessier J. Hémospermie: Ne pas paniquer. *Can Fam Physician*. 1991;37:930-1.
16. Fuse H, Komiya A, Nozaki T, Watanabe A. Hematospermia: etiology, diagnosis, and treatment. *Reprod Med Biol*. 2011;10(3): 153-159.
17. Bamberger E, Madeb R, Steinberg J, Paz A, Satinger I, Kra-Oz Z, et al. Detection of sexually transmitted pathogens in patients with hematospermia. *Isr Med Assoc J*. 2005;7(4):224-7
18. Koment RW, Poor PM. Infection by human cytomegalovirus associated with chronic hematospermia. *Urology* 1983;22:617.
19. Kurscheidt FA, Damke E, Bento JC, Balani VA, Takeda KI, Piva S, et al. Effects of herpes simplex virus infections on seminal parameters in male partners of infertile couples. *Urology* 2018;113:52-58
20. Kulchavenya E, Zhukova I, Khol'tobin D. Spectrum of urogenital tuberculosis. *J Infect Chemother*. 2013;19(5):880-3.
21. Zhukova II, Kul'chavenia EV, Khol'tobin DP, Brizhatiuk EV, Khomiakov VT, Osadchiĭ AV. Urogenital tuberculosis today. *Urologiia* 2013;(1):13-6.
22. Sampalmieri G, Giancola FL, Cabras A. Hemospermia: cause, clinical significance and our experience. *Riv Eur Sci Med Farmacol*. 1992;14:135-7
23. Pal DK. Haemospermia: an Indian experience. *Trop Doct*. 2006;36(1):61-2.
24. Downs JA, de Dood CJ, Dee HE, McGeehan M, Khan H, Marenga A, et al. Schistosomiasis and Human Immunodeficiency Virus in Men in Tanzania. *Am J Trop Med Hyg*. 2017;96(4):856-862.
25. Lang R, Minion J, Wong A. Hematospermia in a returned traveler. *Can Urol Assoc J*. 2017;11(1-2):E41-E43.
26. Segal AS, Kan IaD, Dunaevskii IaL, Dolgopiatov DG. Benign neoplasms of the urethra in men. *Urol Nefrol (Mosk)*. 1996;(3):39-42.
27. Hills SL, Russell K, Hennessey M, Williams C, Oster AM, Fischer M, Mead P. Transmission of Zika virus through sexual contact with travelers to areas of ongoing transmission - Continental United States, 2016. *MMWR Morb Mortal Wkly Rep*. 2016;65(8):215-6.
28. Heras-Cañas V, Gutiérrez-Soto B, Serrano-García ML, Vázquez-Alonso F, Navarro-Marí JM, Gutiérrez-Fernández J. Chronic bacterial prostatitis. Clinical and microbiological study of 332 cases. *Med Clin (Barc)*. 2016;147(4):144-7.
29. Stefanovic KB, Gregg PC, Soung M. Evaluation and treatment of hematospermia. *Am Fam Physician*. 2009;80(12):1421-7.
30. Lee G. Chronic Prostatitis: A Possible Cause of Hematospermia. *World J Mens Health*. 2015;33(2):103-8.
31. Saracoglu M, Ozturk H, Duran A, Atalay S. Effect of microorganisms on etiology of hematospermia. *Arch Ital Urol Androl*. 2015;87(1):80-2.
32. Gattoni F, Avogadro A, Sacrini A, Blanc M, Pozzato C, Spagnoli I, Uslenghi C. Transrectal prostatic echography in the study of hemospermia. An assessment of an 85-patient case load. *Radiol Med*. 1996;91(4):424-8.
33. Pastore AL, Palleschi G, Fuschi A, Porta N, Cerbelli B, Di Cristofano C, et al. Hematospermia and xanthogranulomatous prostatitis: An unusual onset of a rare diagnosis. *Can Urol Assoc J*. 2013;7(11-12):E820-2.
34. Yu JJ, Xu YM, Zhang J, Liu ZS, Zhang XR, Chen R. Etiopathogenesis and management of seminal vesicle enlargement. *Zhonghua Nan Ke Xue* 2008;14(3):231-3.
35. Liu GL, Wang GY, Wu KR, Yin WQ, Wu WJ. Etiological factors for calculus-associated seminal vesiculitis: Analysis of calculus composition in 6 cases. *Zhonghua Nan Ke Xue* 2018;24(2):128-132
36. Coppens L, Bonnet P, Andrianne R, de Leval J. Adult müllerian duct or utricle cyst: clinical significance and therapeutic management of 65 cases. *J Urol*. 2002; 167:1740.
37. Wang TM, Chuang CK, Lai MK. Seminal vesicle cyst: an unusual cause of hematospermia--a case report. *Changcheng Yi Xue Za Zhi* 1993;16:275.
38. Mayersak JS, Viviano CJ. Unilateral seminal vesicle cyst presenting as hematospermia; diagnosis established by transrectal prostatic ultrasound. *Wis Med J*. 1992; 91:629.

39. Cattolica EV. Massive hemospermia: a new etiology and simplified treatment. *J Urol.* 1982;128(1):151-2.
40. Correa-Pérez JR. Short Communication: Occurrence of Nonpersistent Hemospermia After a Prolonged Period of Daily Ejaculatory Intensity Longer Than 3 Weeks. *J Assist Reprod Genet.* 2004;21:341-2.
41. Sampalmieri G, Giancola FL, Cabras A. Hemospermia: cause, clinical significance and our experience. *Riv Eur Sci Med Farmacol.* 1992;14(2):135-7.
42. Gkougkousis EG, Khan M, Terry TR, Mellon JK. Urethral venous malformation: an unusual cause of recurrent post-coital gross haematuria in association with haemospermia. *Ann R Coll Surg Engl.* 2009;91(6):532-4.
43. Lemesh RA. Case report: recurrent hematuria and hemospermia due to prostatic telangiectasia in classic von Willebrand's disease. *Am J Med Sci* 1993; 306:35.
44. Furuya S, Ogura H, Tanaka Y, et al. Hemangioma of the prostatic urethra: hemospermia and massive postejaculation hematuria with clot retention. *Int J Urol.* 1997;4:524.
45. Suzuki K, Nishimi D, Morioka H, Takanami M. Hemospermia associated with congenital arteriovenous malformation of internal iliac vessels. *Int J Urol.* 2007;14(4):370-372.
46. Minardi D, Scortechini AR, Milanese G, Leoni P, Muzzonigro G. Spontaneous recurrent hematuria and hemospermia: Unique manifestations of von Willebrand disease type I. Case report. *Arch Ital Urol Androl.* 2016;88(1):62-3.
47. Emori Y, Sakugawa M, Niiya K, Kiguchi T, Kojima K, Takenaka K, et al. Life-threatening bleeding and acquired factor V deficiency associated with primary systemic amyloidosis. *Blood Coagul Fibrinolysis.* 2002;13(6):555-9.
48. Celik A, Gundes A, Camsari A. Hemospermia due to clopidogrel: the unknown side effect. *Blood Coag Fibrinolysis.* 2015;26(1):113
49. Najafi L, Noohi AH. Recurrent hematuria due to aspirin. *Indian J Med Sci.* 2009;63(6):259-60.
50. Vasudeva P, Kumar N, Kumar A, Singh H, Kumar G. Safety of 12 core transrectal ultrasound guided prostate biopsy in patients on aspirin. *Int Braz J Urol.* 2015;41(6):1096-100.
51. Rietbergen JB, Kruger AE, Kranse R, Schröder FH. Complications of transrectal ultrasound-guided systematic sextant biopsies of the prostate: evaluation of complication rates and risk factors within a population-based screening program. *Urology* 1997;49(6):875-80.
52. Abdelkhalek MA, Abdelshafy M, Elhelaly HA, El Nasr MK. Hemospermia after transrectal ultrasound (TRUS) -guided prostatic biopsy: a prospective study. *J Egypt Soc Parasitol.* 2012;42(1):63-70.
53. Bokhorst LP, Lepistö I, Kakehi Y, Bangma CH, Pickles T, Valdagni R, et al. Complications after prostate biopsies in men on active surveillance and its effects on receiving further biopsies in the Prostate Cancer Research International: Active Surveillance (PRIAS) study. *BJU Int.* 2016;118(3):366-71.
54. Dell'Atti L. Ultrasound detection of prostatic calculi as a parameter to predict the appearance of hemospermia after a prostate biopsy. *Int Braz J Urol.* 2017;43(6):1136-1143
55. Kliton J, Ágoston P, Szabó Z, Major T, Polgár C. Use of gold radionuclide markers implanted into the prostate for image-guided radiotherapy in prostate cancer: side effects caused by the marker implantation. *Magy Onkol.* 2014;58(3):182-7.
56. Gill S, Li J, Thomas J, Bressel M, Thursky K, Styles C, et al. Patient-reported complications from fiducial marker implantation for prostate image-guided radiotherapy. *Br J Radiol.* 2012;85(1015):1011-7.
57. Matta R, Chapple CR, Fisch M, Heidenreich A, Herschorn S, Kodama RT, et al. Pelvic complications after prostate cancer radiation therapy and their management: An international collaborative narrative review. *Eur Urol.* 2019;75(3):464-476.
58. Ferrari N. Hemospermia demystified. *Harvard Health*, <https://www.health.harvard.edu/blog/hemospermia-demystified-2009031142>
59. Cheng YS, Lin JS, Lin YM. Isolated posterior urethral injury: an unusual complication and presentation following male coital trauma. *Asian J Androl* 2006;8:379-81.
60. Girolami A, Scarparo P, Candeo N, Sartori R, Scandellari R, Girolami B. Hemospermia in patients with congenital coagulation disorders: a study of three cases. *Acta Haematol* 2009;121:42-6.
61. Navío Niño S, Jiménez Cruz JF, González R, Alonso JG, Boronat F. Hemospermia caused by proliferative papillary urethritis. *Actas Urol Esp.* 1981;5(5):331-4.
62. Furuya S, Ogura H, Shimamura S, et al. Clinical manifestations of 25 patients with prostatic-type polyps in the prostatic urethra. *Hinyokika Kyo* 2002;48:337.
63. Ishigooka M, Hashimoto T, Kodama C, et al. Polyps of the prostatic urethra. Report of four cases. *Urol Int.* 1993; 50:57.
64. Maheshkumar P, Otite U, Gordon S, et al. Testicular tumor presenting as hemospermia. *J Urol* 2001;165:188.
65. Han M, Brannigan RE, Antenor JA, Roehl KA, Catalona WJ. Association of hemospermia with prostate cancer. *J Urol.* 2004;172(6 Pt 1):2189-92.
66. Stamatou K, Sfikakis P, Kontostolis S, Moschouris H, Sermpetzoglou A. Primary adenocarcinoma of the seminal vesicles - a phantom tumour. *Hell J Surg.* 2011;83(6) 356-360
67. Fujisawa M, Ishigami J, Kamidono S, Yamanaka N. Adenomyosis of the seminal vesicle with hemospermia. *Hinyokika Kyo* 1993;39:73.
68. Yanagisawa N, Saegusa M, Yoshida T, Okayasu I. Squamous cell carcinoma arising from a seminal vesicular cyst: possible relationship between chronic inflammation and tumor development. *Pathol Int* 2002;52:249.
69. Yamamoto S, Mamiya Y, Noda K, et al. A case of metastasis to the seminal vesicle of renal cell carcinoma. *Nihon Hinyokika Gakkai Zasshi* 1998;89:563.
70. Close CF, Yeo WW, Ramsay LE. The association between haemospermia and severe hypertension. *Postgrad Med J.* 1991;67(784):157-158.
71. Kurkar A, Elderwy AA, Awad SM, Abulsorour S, Aboul-Ella HA, Al-taher A. Hyperuricemia: a possible cause of hemospermia. *Urology* 2014;84(3):609-12.
72. Zargooshi J, Nourizad S, Vaziri S, Nikbakht MR, Almasi A, Ghadiri K et al. Hemospermia: long-term outcome in 165 patients. *Int J Impot*



- Res. 2014;26(3):83-6.
73. Papoutsoglou N, Burger M, Riedmiller H. Persistent painless hemospermia due to metastatic melanoma of the right seminal vesicle. *BMC Urol.* 2013;13:43.
 74. Foahom Kamwa AD, Mateus C, Thanigasalam R, Boulay-Coletta I, Duchatelle V, Triller M, et al. Seminal vesicle metastasis of cutaneous malignant melanoma: An unusual and challenging presentation. *Can Urol Assoc J.* 2015;9(3-4):E220-3
 75. Tosev G, Kuru TH, Huber J, Freier G, Bergmann F, Hassel JC, et al. Primary melanoma of the prostate: case report and review of the literature. *BMC Urol.* 2015;15:68.
 76. Polito M, Giannubilo W, d'Anzeo G, Muzzonigro G. Hemospermia: diagnosis and treatment. *Arch Ital Urol Androl.* 2006;78(2):82-5.
 77. Szlauer R, Jungwirth A. Haemospermia: Diagnosis and treatment. *Andrologia* 2008;40:120-24
 78. Jinza S1, Noguchi K, Hosaka M. Retrospective study of 107 patients with hemospermia. *Hinyokika Kyo.* 1997;43(2):103-7.
 79. Akhter W, Khan F, Chingwundoh F. Should every patient with hemospermia be investigated? A critical review. *Cent European J Urol.* 2013;66(1):79-82.
 80. Tapper AD. Hemospermia Workup. *Medscape*, <https://emedicine.medscape.com/article/457632-workup>. Visited: Mar 14, 2019
 81. Magoha GA, Magoha OB. Aetiology, diagnosis and management of haemospermia: a review. *East Afr Med J.* 2007;84(12):589-94.
 82. Worischek JH, Parra RO. Chronic hemospermia: assessment by transrectal ultrasound. *Urology* 1994;43(4):515-520.