



¹Division of Internal and
Cardiovascular Medicine,

Department of Medicine and Surgery,
University of Perugia, Perugia, Italy;

²Diagnostic and Therapeutic Medicine
Department, University Campus
Bio-Medico of Rome, Rome, Italy;

³Department of Medicine,
Fondazione Policlinico

Universitario A. Gemelli IRCCS,
Università Cattolica del Sacro
Cuore, Rome, Italy;

⁴Department of Medicine and Ageing
Sciences, University
G. D'Annunzio, Chieti-Pescara, Italy;

⁵Department of Medicine and
Surgery, University of Insubria,
Varese, Italy;

⁶Department of Experimental
and Clinical Medicine, "Careggi"
University Hospital, University
of Florence, Florence, Italy;

⁷Department of Medicine and Surgery,
Section of Ophthalmology, University
of Perugia, Perugia, Italy

Antithrombotic treatment of retinal vein occlusion: a position statement from the Italian Society on Thrombosis and Haemostasis (SISSET)

Francesco Paciullo^{*}, Emanuele Valeriani^{2*}, Angelo Porfidia^{3*}, Marcello Di Nisio⁴, Marco P. Donadini⁵, Rossella Marcucci⁶, Domenico Prisco⁶, Carlo Cagini⁷, Paolo Gresele¹, Walter Ageno⁵

Retinal vein occlusion (RVO) represents a common cause of visual impairment and blindness. RVO may be associated with both local (e.g., hyperopia, glaucoma) and systemic (e.g., hypertension, diabetes, smoking, obesity, and dyslipidaemia) risk factors. The association with thrombophilia remains controversial. Data on the use of antithrombotic therapy for RVO are poor and inconsistent with most of the information being derived from observational studies. Here we provide a position statement from the Italian Society on Thrombosis and Haemostasis (SISSET) to guide the clinical and therapeutic management of patients with RVO based on the available evidence and expert opinion.

Keywords: anticoagulant agents, antiplatelet agents, evidence-based medicine, retinal vein occlusion.

INTRODUCTION

Retinal vein occlusion (RVO) is a venous thrombosis in an unusual site that may involve the central retinal vein (central vein occlusion, CRVO) or its branches (branch vein occlusion, BRVO)¹.

More than 16 million people worldwide are affected by RVO, making it the second most common retinal vascular disease after diabetic retinopathy². The estimated age- and sex-standardised prevalence of BRVO and CRVO are 4.4 and 0.8 per 1,000, respectively, with higher values in elderly, Asian, and Hispanic populations². The cumulative 10-year incidence of RVO ranges between 1.38% and 1.92%³. Clinical manifestations may be widely variable ranging from a mild, and sometimes not perceived, visual impairment to important functional deterioration; development of neovascular glaucoma and retinal detachment is rare⁴. RVO diagnosis requires ophthalmic evaluation, including an accurate medical history (timing and duration of symptoms), ocular tone measurement, fundus examination, and visual acuity assessment. Fluorescein angiography and/or optical coherence tomography may confirm diagnosis and objectively measure retinal perfusion and macular oedema at diagnosis and during follow-up⁵.

SCOPE AND METHODOLOGY

Evidence to guide antithrombotic management strategies for RVO is scarce and is mostly derived from observational studies and few small randomised controlled trials (RCTs). This position statement aims to provide clinicians with practical advice on how to identify those patients who may benefit from antithrombotic treatment and to suggest the best management according to procedures currently available. MEDLINE and EMBASE databases were systematically screened from inception up to February 2021, and clinical trial registries (i.e., clinicaltrials.gov) were searched to retrieve additional information from ongoing studies.

Following a literature review, the articles selected were critically evaluated to formulate a series of statements on relevant clinical topics. These statements were proposed and discussed by the panel of experts based on their expertise and the evidence available in the field. Each member of the panel finally expressed his/her agreement or disagreement (*Online Supplementary Content, Table S1*). “Recommend” indicates a strong statement with high consensus among members of the panel (>75%), whereby the clinician should consider adopting the practice in most cases. “Suggest” reflects a weaker guidance statement with only moderate consensus among panel members (50-75%), whereby the clinician may choose to adopt the statement or use an alternative approach to manage patients. No attempt to formally grade the evidence was made due to the insufficiency of good quality intervention trials.

CLINICAL HISTORY OF RETINAL VEIN OCCLUSION PATIENTS

RVO usually manifests as a sudden and painless impairment or loss of visual acuity, mainly due to the formation of retinal oedema; it may result in retinal haemorrhages, glaucoma, neovascularisation, and retinal detachment leading to blindness⁶. CRVO is usually characterised by more severe visual impairment and lower rate of spontaneous remission than BRVO⁷.

Information on the risk of recurrent RVO remains limited but case numbers seem to suggest that this is not a rarity; the cumulative risk at 2- and 4-year follow-up was reported to be 0.9% and 2.5% for cases in the same eye, and 7.7% and 11.9% for cases in the other eye⁸. A more recent 8-year

follow-up case control study reported a recurrence of 11.1% in untreated patients⁹. The risk of recurrent RVO seems to be higher in patients with hypertension and hyperlipidaemia¹⁰. Patients with RVO have a higher long-term risk of cardiovascular events. In several studies, cardiovascular risk was higher than in the general population with a roughly two-fold increased risk of developing stroke, myocardial infarction, and cardiovascular death^{9,11-15}. The results of a meta-analysis of six studies (total 549 patients) reported that the Framingham score of RVO patients (10.1%; 95% CI: 9.9-10.2) is significantly higher than that of 8.4 million people aged 40-74 years from the general Canadian population (difference in percentage risk = 4.1; 95% CI: 4.0-4.2; $p < 0.0001$).

Appropriate management of relevant cardiovascular risk factors (e.g., arterial hypertension, diabetes, dyslipidaemia) is strongly advisable to reduce the risk of future complications¹⁶. However, no data are available on the effect of different therapeutic strategies on long-term clinical outcomes in patients with RVO.

RETINAL VEIN OCCLUSION PATHOGENESIS AND RISK FACTORS

RVO is often associated with local risk factors (e.g., hyperopia, glaucoma) which, by increasing intraocular pressure, favour stasis, and thus thrombosis. Moreover, a wide range of systemic disorders and risk factors have been associated with RVO^{5,11}. The close relationship between RVO and traditional cardiovascular risk factors (e.g., hypertension, diabetes, smoking, obesity, and dyslipidaemia), atherosclerosis and arterial thrombosis has been suggested by many observational studies^{9,16-19}. It has been proposed that conventional cardiovascular risk factors may favour blood stasis in the retinal veins through their compression by the atherosclerotic retinal arteries⁴. Other non-conventional cardiovascular risk factors, like lipoprotein (a) or increased platelet reactivity, may further contribute to RVO development^{17,20,21}.

The role of thrombophilia in RVO is controversial^{4,5}. In spite of the reports from individual studies of an association between RVO and some typical vein thrombosis-associated thrombophilic alterations (i.e., hyperhomocysteinaemia, prothrombin gene and factor V Leiden mutations, antithrombin, protein C or S deficiencies), recent meta-analyses produced conflicting

results²⁰⁻²⁶. Antiphospholipid syndrome is responsible for roughly a two-fold increased risk of RVO, especially in patients with triple positivity (i.e., lupus anticoagulant, anti-cardiolipin and anti- β 2-glycoprotein). Similarly, antiphospholipid antibody titres were significantly higher in patients with RVO than in the general population, even in the absence of other cardiovascular risk factors²⁷. However, concerns remain about the estimated risk of RVO in patients with antiphospholipid syndrome. In the available studies, the incidence of lupus anticoagulant was higher than previously reported, no information was available as to the timing of lupus anticoagulant measurement (i.e., during or after anticoagulant therapy), and only activated partial thromboplastin time-derived tests were used while other recommended tests (e.g., dilute Russell viper venom test) were not performed²⁸.

The strongest association between RVO and thrombophilia has been reported in younger patients (age ≤ 45 years), those with a family or personal history of venous thromboembolism, and those without cardiovascular risk factors²⁹⁻³¹. Autoimmune diseases (e.g., systemic lupus erythematosus) as well as oestrogen therapy, may also represent potential risk factors for RVO, although evidence is limited³²⁻³⁵.

RETINAL VEIN OCCLUSION TREATMENT

To date there is still no universally agreed gold standard of treatment for RVO; therapy aims to reduce local complications (e.g., oedema and neovascularisation), favour recanalisation, and prevent cardiovascular events³⁶.

Ophthalmologic management of local complications

Ophthalmological interventions, including dexamethasone intraocular implant and intravitreal injection of angiogenesis inhibitors (e.g., bevacizumab), are aimed at reducing local oedema and neovascularisation. A recent meta-analysis including 4 RCTs and 12 observational studies reported a greater lower letter gain in best corrected visual acuity (mean difference -6.59; 95CI: -8.87 to -4.22) in dexamethasone implants versus angiogenesis inhibitors³⁷.

Other treatments that have been suggested to improve visual acuity include grid macular laser photocoagulation, arteriovenous sheathotomy, and intravitreal streptokinase⁵.

Efficacy of antithrombotic treatment

Data on the efficacy of antithrombotic drugs for the treatment and prevention of RVO are inconsistent. Few RCTs are available, and most data come from small, low-quality observational studies at high risk of bias (Table I)^{38,39}.

The use of antiplatelet therapy in RVO is supported by the results of only one placebo-controlled trial. This study compared six months of therapy with ticlopidine 250 mg twice daily with no treatment in 89 patients with acute RVO. Visual acuity improvement was significantly greater after antiplatelet administration, especially in patients with increased platelet aggregation and hyperlipidaemia⁴⁰. More recently, data from a prospective cohort of 307 patients with acute RVO showed that antiplatelet therapy significantly reduced the absolute risk of recurrence (by 7.2% with aspirin and of 9.2% with ticlopidine) compared with no antithrombotic use⁴¹.

The efficacy of low molecular weight heparin (LMWH) was assessed in three RCTs comparing parnaparin or dalteparin with aspirin in patients with recent onset

Table I - Randomised controlled trials evaluating antithrombotic treatment in patients with retinal vein occlusion (RVO)

Author	RVO diagnosis	Sample (case/controls)	Treatment	Comparator	Follow-up	Setting	Outcome
Huotsmuller, 1984		48/41	Ticlopidine	Placebo	Not specified	Acute RVO	Visual acuity
Farahvash, 2008	Visual acuity, Fundus, FAG	24/23	Dalteparin	ASA	12 months	Acute BRVO	Visual acuity
Farahvash, 2008	Visual acuity, Fundus, FAG	47/46	Dalteparin	ASA	6 months	Acute CRVO	Visual acuity
Agno, 2010	Visual acuity, FAG	28/30	Parnaparin	ASA	6 months	Acute RVO	Eye worsening assessed with FAG, visual acuity and visual field

ASA:acetylsalicylic acid; FAG: fluoro-angiography; RVO: retinal vein occlusion.

(within 15-30 days) BRVO or CRVO⁴²⁻⁴⁴. Parnaparin at a fixed daily dose of 12,800 International Units (IU) for seven days followed by 6,400 IU for three months was significantly more effective than aspirin in reducing functional impairment at follow-up (20.7% vs 59.4%) and recurrent RVO (0% vs 10%), without any difference in bleeding rates⁴². In a similar manner, dalteparin at the dose of 100 IU/kg twice daily for ten days followed by 100 IU/kg once a day for another ten days significantly reduced neovascularisation and visual impairment as compared to aspirin administered at the dose of 100 mg once a day for 20 days^{43,44}. A subsequent meta-analysis including these three studies for a total of 229 patients confirmed these observations, reporting a 78% relative risk reduction of adverse ocular outcomes after LMWH administration, without any increase in the risk of vitreous haemorrhage³⁹. Observational data suggest that the use of warfarin, as anticoagulant, with an International Normalized Ratio (INR) range between 2 and 3, may improve ocular outcomes (i.e., visual acuity and vessel recanalisation) as compared to antiplatelet therapy, especially in patients aged <50 years and with antiphospholipid syndrome⁴⁵. Data on fondaparinux (2.5 mg daily) are available

only from small case series in which visual acuity improvement was achieved in 9 of 11 included patients (81%) during a median follow-up of 13.5 months⁴⁶.

Finally, no clinical studies have so far evaluated the role of direct oral anticoagulants (DOACs) in RVO. A recent study including a cohort of 281,970 patients with non-valvular atrial fibrillation reported a higher occurrence of RVO in patients treated with DOACs than in warfarin-treated patients (odds ratio 1.59; 95% CI: 1.35-1.86), but a lower risk of intraocular bleeding (odds ratio 0.86; 95% CI: 0.75-0.98)⁴⁷.

The role of antithrombotic agents in the extended secondary prevention of RVO and in the prevention of cardiovascular events remains unexplored because treatment duration in RCTs ranged from few weeks to six months⁷. Currently, there is no evidence to support the use of anticoagulant therapy, if prescribed, beyond 1-3 months.

For the prevention of cardiovascular events, the use of antiplatelet agents should be based on the overall assessment of cardiovascular risk factors and on the individual risk profile, possibly considering RVO as an additional predictor of future events. Based on currently

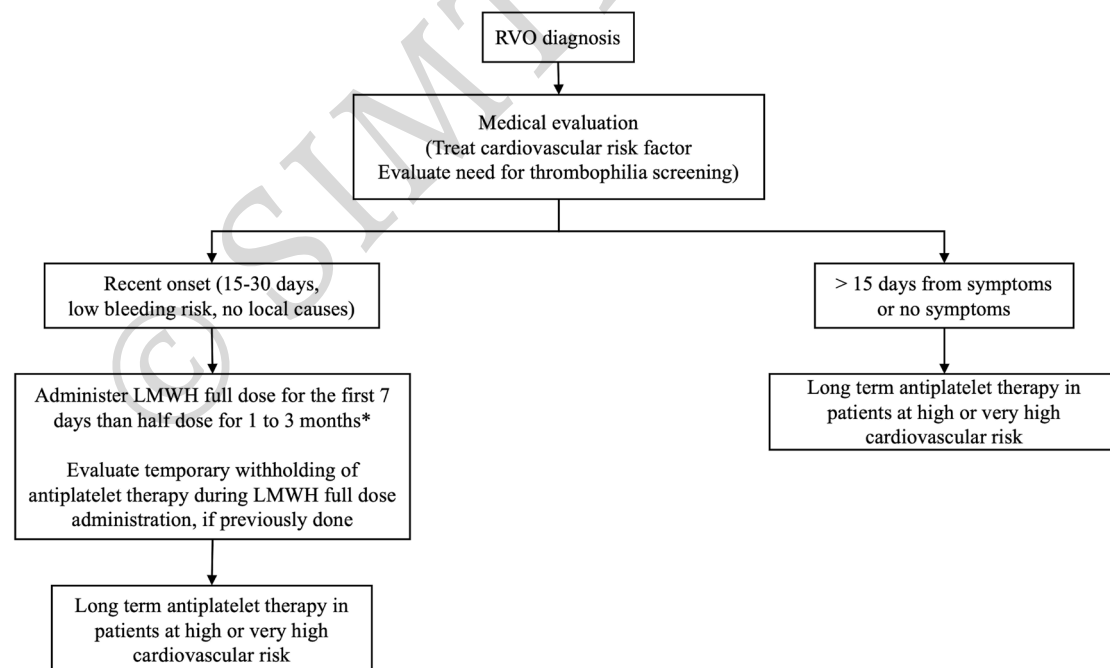


Figure 1 - Therapeutic approach to manage patients with retinal vein occlusion (RVO)

*Small and isolated retinal haemorrhage does not represent an absolute contraindication to antithrombotic treatment. Perform vitreal procedures at the trough levels of anticoagulant therapy, when indicated.

available evidence, a suggested approach to manage patients with RVO is outlined in **Figure 1**.

Antithrombotic treatments and intraocular haemorrhage

Retinal haemorrhages are quite common complications of RVO and are the consequence of venous obstruction or neoangiogenesis⁴⁸. Intraocular bleeding is often found at the time of RVO diagnosis making therapeutic choices challenging⁴⁹. These bleedings, however, require prompt intervention (e.g., laser photocoagulation, cryotherapy or pars plana vitrectomy) only in case of submacular, subhyaloid, and vitreous localisation, to avoid a permanent loss of vision^{50,51}. Despite no available information on the safety of LMWH in patients presenting with retinal haemorrhage, data from three RCTs provided reassuring results showing that patients receiving LMWH had a lower risk of intraocular bleeding than those receiving antiplatelet therapy⁴²⁻⁴⁴. In these RCTs, the presence of retinal haemorrhage at diagnosis did not exclude patients from being assigned to antithrombotic treatment⁴²⁻⁴⁴.

Antithrombotic therapy and vitreal surgery

Patients with RVO are frequently treated with intravitreal injections, and sometimes vitreal surgery. In a small case series of 25 patients undergoing vitreal surgery while on warfarin (INR between 1.5 and 3; median 2), one patient experienced intraretinal perioperative haemorrhage. According to the few available data, it seems reasonable to perform vitreal procedures at the trough levels of anticoagulant therapy^{52,53}.

POSITION STATEMENTS

1. In all patients with suspected RVO, we recommend immediate ophthalmic consultation including visual acuity assessment, fundus and ocular tone examination, optical coherence tomography, and fluorescein-angiography if ischaemia is suspected, to confirm diagnosis and assess degree of functional impairment.
2. In all patients with a confirmed diagnosis of RVO, we recommend a multidisciplinary approach involving an expert in thrombosis and haemostasis to plan risk factor assessment and treatment strategies.
3. In patients with RVO who have no apparent systemic risk factors, especially in those aged <45 years, we suggest assessing the complete panel of

antiphospholipid antibodies (i.e., lupus anticoagulant, anti-cardiolipin and anti- β 2-glycoprotein) and measurement of homocysteine. The search for lupus anticoagulant should be performed when patients are far from anticoagulation.

4. In all patients with RVO, we recommend careful assessment and treatment of cardiovascular risk factors, with particular attention to arterial hypertension, dyslipidaemia, diabetes mellitus, and hyperhomocysteinaemia.
5. Considering the potential prothrombotic effect of oestrogen therapy, we suggest alternative contraceptive methods in all women in whom these agents may have contributed to RVO development.
6. In patients with recent onset RVO (within 15-30 days) at low bleeding risk and without local risk factors (e.g., hyperopia, glaucoma), we recommend the use of a therapeutic dose of LMWH for the first week followed by half-dose LMWH for 1-3 months over aspirin or no treatment.
7. We suggest not to consider small and isolated retinal haemorrhage as an absolute contraindication to antithrombotic treatment in patients with RVO.
8. In patients taking antiplatelet therapy for stable arterial disease, we suggest to temporarily withhold antiplatelet therapy when full-dose LMWH therapy is prescribed for recent RVO.
9. We recommend performing vitreal procedures, when indicated, at the trough levels of anticoagulant therapy.
10. We recommend considering long-term aspirin administration for primary prevention of cardiovascular disease in patients with RVO at high or very high cardiovascular risk.

ACKNOWLEDGMENTS

We thank Professor Gianni Virgili of the Department of Neurosciences, Psychology, Drug Research and Child Health - NEUROFARBA, University of Florence, Italy, for his contribution to the revision of manuscript

CONFLICT OF INTEREST

FP, EV, MPD, CC, and DP have nothing to disclose. AP reports personal fees from Bayer, Boehringer Ingelheim, Daiichi Sankyo, BMS-Pfizer, Novartis and Aspen, outside the submitted work. MDN reports personal fees from Bayer, Daiichi Sankyo,

BMS-Pfizer, Leo Pharma, Sanofi, and Aspen, outside the submitted work; RM reports lecture fees and advisory board from Amgen, Sanofi, Werfen, Bayer, Daiichi-Sankyo, Pfizer, Viatrix; PG reports speaker's fees outside the submitted work from; WA has received a research grant from Bayer to support a clinical study in patients with splanchnic vein thrombosis, received honoraria for participation at advisory boards from Bayer, Boehringer Ingelheim, Daiichi Sankyo, BMS/Pfizer, Sanofi, and Portola, and reports grants and personal fees from Bayer, and personal fees from BMS/Pfizer, Daiichi Sankyo, Sanofi, Aspen, Janssen, and Portola.

REFERENCES

- Prisco D, Marcucci R, Bertini L, et al. Cardiovascular and thrombophilic risk factors for central retinal vein occlusion. *Eur J Intern Med* 2002; **13**: : 163-9.
- Rogers S, McIntosh RL, Cheung N, et al. The prevalence of retinal vein occlusion: pooled data from population studies from the United States, Europe, Asia, and Australia. *Ophthalmology* 2010; **117**: 313-9.
- Song P, Xu Y, Zha M, et al. Global epidemiology of retinal vein occlusion: a systematic review and meta-analysis of prevalence, incidence, and risk factors. *J Glob Health* 2019; **9**: 010427.
- Mikhailova MA, Sizova MV, Shelankova AV. [Pathogenesis of retinal vein occlusions]. *Vestn Oftalmol* 2014; **130**: 88-92.
- Garcia-Horton A, Al-Ani F, Lazo-Langner A. Retinal vein thrombosis: The Internist's role in the etiologic and therapeutic management. *Thromb Res* 2016; **148**: 118-24.
- Marcucci R, Sofi F, Grifoni E, et al. Retinal vein occlusions: a review for the internist. *Intern Emerg Med* 2011; **6**: 307-14.
- Agno W, Beyer-Westendorf J, Garcia DA, et al. Guidance for the management of venous thrombosis in unusual sites. *J Thromb Thrombolysis* 2016; **41**: 129-43.
- Hayreh SS, Zimmerman MB, Podhajsky P. Incidence of various types of retinal vein occlusion and their recurrence and demographic characteristics. *Am J Ophthalmol* 1994; **117**: 429-441.
- Di Capua M, Coppola A, Albinini R, et al. Cardiovascular risk factors and outcome in patients with retinal vein occlusion. *J Thromb Thrombolysis* 2010; **30**: 16-22.
- Dodson PM, Kubicki AJ, Taylor KG, et al. Medical conditions underlying recurrence of retinal vein occlusion. *Br J Ophthalmol* 1985; **69**: 493-6.
- Cugati S, Wang JJ, Rochtchina E, et al. Ten-year incidence of retinal vein occlusion in an older population: the Blue Mountains Eye Study. *Arch Ophthalmol* 2006; **124**: 726-32.
- Khan Z, Almeida DR, Rahim K, et al. 10-Year Framingham risk in patients with retinal vein occlusion: a systematic review and meta-analysis. *Can J Ophthalmol* 2013; **48**: 40-5.
- Ho JD, Liou SW, Lin HC. Retinal vein occlusion and the risk of stroke development: a five-year follow-up study. *Am J Ophthalmol* 2009; **147**: 283-90.
- Zhong C, You S, Zhong X, et al. Retinal vein occlusion and risk of cerebrovascular disease and myocardial infarction: A meta-analysis of cohort studies. *Atherosclerosis* 2016; **247**: 170-6.
- Wu CY, Riangwiwat T, Limpruttidham N, et al. Association of retinal vein occlusion with cardiovascular events and mortality: a systematic review and meta-analysis. *Retina* 2019; **39**: 1635-45.
- Capua MD, Minno MN, Guida A, et al. Coronary artery disease, cerebral non-fatal ischemic stroke in retinal vein occlusion: an 8-yr follow-up. *Nutr Metab Cardiovasc Dis* 2012; **22**: 23-7.
- Paciullo F, Giannandrea D, Virgili G, et al. Role of Increased Lipoprotein (a) in Retinal Vein Occlusion: A Systematic Review and Meta-analysis. *TH Open* 2021; **5**: e295-e302.
- O'Mahoney PR, Wong DT, Ray JG. Retinal vein occlusion and traditional risk factors for atherosclerosis. *Arch Ophthalmol* 2008; **126**: 692-9.
- Wong TY, Larsen EK, Klein R, et al. Cardiovascular risk factors for retinal vein occlusion and arteriolar emboli: the Atherosclerosis Risk in Communities & Cardiovascular Health studies. *Ophthalmology* 2005; **112**: 540-7.
- Leoncini G, Signorello MG, Segantini A, et al. In retinal vein occlusion platelet response to thrombin is increased. *Thromb Res* 2009; **124**: e48-55.
- Leoncini G, Bruzzese D, Signorello MG, et al. Platelet activation by collagen is increased in retinal vein occlusion. *Thromb Haemost* 2007; **97**: 218-27.
- Janssen MC, den Heijer M, Cruysberg JR, et al. Retinal vein occlusion: a form of venous thrombosis or a complication of atherosclerosis? A meta-analysis of thrombophilic factors. *Thromb Haemost* 2005; **93**: 1021-6.
- Zhu W, Wu Y, Xu M, et al. Antiphospholipid antibody and risk of retinal vein occlusion: a systematic review and meta-analysis. *PLoS One* 2014; **10**: e0122814.
- Romiti GF, Corica B, Borgi M, et al. Inherited and acquired thrombophilia in adults with retinal vascular occlusion: A systematic review and meta-analysis. *J Thromb Haemost* 2020; **18**: 3249-66.
- Hayreh SS, Zimmerman B, McCarthy MJ, et al. Systemic diseases associated with various types of retinal vein occlusion. *Am J Ophthalmol* 2001; **131**: 61-77.
- Kuhli-Hattenbach C, Hellstern P, Nægler DK, et al. Prothrombin polymorphism A19911G, factor V HR2 haplotype A4070G, and plasminogen activator-inhibitor-1 polymorphism 4G/5G and the risk of retinal vein occlusion. *Ophthalmic Genet* 2017; **38**: 413-7.
- Hernández JL, Sanlés I, Pérez-Montes R, et al. Antiphospholipid syndrome and antiphospholipid antibody profile in patients with retinal vein occlusion. *Thromb Res* 2020; **190**: 63-8.
- Tripodi A, Cohen H, Devreese KMJ. Lupus anticoagulant detection in anticoagulated patients. Guidance from the Scientific and Standardization Committee for lupus anticoagulant/antiphospholipid antibodies of the International Society on Thrombosis and Haemostasis. *J Thromb Haemost* 2020; **18**: 1569-75.
- Kuhli-Hattenbach C, Scharrer I, Lüchtenberg M, et al. Coagulation disorders and the risk of retinal vein occlusion. *Thromb Haemost* 2010; **103**: 299-305.
- Napal JJ, Neila S, Pérez-Montes R, et al. The role of coagulation disorders in patients with retinal vein occlusion. *QJM* 2016; **109**: 97-102.
- Napal Lecumberri JJ, Sedano Balbas C, Cañal Villanueva J, et al. Thrombophilia and vascular risk factors in retinal vein occlusion. *Rev Clin Esp (Barc)* 2013; **213**: 229-34.
- Aggarwal RS, Mishra VV, Aggarwal SV. Oral contraceptive pills: A risk factor for retinal vascular occlusion in in-vitro fertilization patients. *J Hum Reprod Sci* 2013; **6**: 79-81.
- Yen YC, Weng SF, Chen HA, et al. Risk of retinal vein occlusion in patients with systemic lupus erythematosus: a population-based cohort study. *Br J Ophthalmol* 2013; **97**: 1192-6.
- Vessey MP, Hannaford P, Mant J, et al. Oral contraception and eye disease: findings in two large cohort studies. *Br J Ophthalmol* 1998; **82**: 538-42.
- Kirwan JF, Tsaloumas MD, Vinal H, et al. Sex hormone preparations and retinal vein occlusion. *Eye (Lond)* 1997; **11**: 53-6.
- Schmidt-Erfurth U, Garcia-Arumi J, Gerendas BS, et al. Guidelines for the Management of Retinal Vein Occlusion by the European Society of Retina Specialists (EURETINA). *Ophthalmologica* 2019; **242**: 123-62.
- Ming S, Xie K, Yang M, et al. Comparison of intravitreal dexamethasone implant and anti-VEGF drugs in the treatment of retinal vein occlusion-induced oedema: a meta-analysis and systematic review. *BMJ Open* 2020; **10**: e032128.
- Squizzato A, Manfredi E, Bozzato S, et al. Antithrombotic and fibrinolytic drugs for retinal vein occlusion: a systematic review and a call for action. *Thromb Haemost* 2010; **103**: 271-6.
- Lazo-Langner A, Hawel J, Agno W, et al. Low molecular weight heparin

- for the treatment of retinal vein occlusion: a systematic review and meta-analysis of randomized trials. *Haematologica* 2010; **95**: 1587-93.
40. Houtsmuller AJ, Vermeulen JA, Klompe M, et al. The influence of ticlopidine on the natural course of retinal vein occlusion. *Agents Actions Suppl* 1984; **15**: 219-29.
 41. Belcaro G, Dugall M, Bradford HD, et al. Recurrent retinal vein thrombosis: prevention with Aspirin, Pycnogenol®, ticlopidine, or sulodexide. *Minerva Cardioangiologica* 2019; **67**: 109-14.
 42. Ageno W, Cattaneo R, Manfredi E, et al. Parnaparin versus aspirin in the treatment of retinal vein occlusion. A randomized, double blind, controlled study. *Thromb Res* 2010; **125**: 137-41.
 43. Farahvash MS, Moghaddam MM, Moghimi S, et al. Dalteparin in the management of recent onset central retinal vein occlusion: a comparison with acetylsalicylic acid. *Can J Ophthalmol* 2008; **43**: 79-83.
 44. Farahvash MS, Moradimogadam M, Farahvash MM, et al. Dalteparin versus aspirin in recent-onset branch retinal vein occlusion: a randomized clinical trial. *Arch Iran Med* 2008; **11**: 418-22.
 45. Sartori MT, Barbar S, Donà A, et al. Risk factors, antithrombotic treatment and outcome in retinal vein occlusion: an age-related prospective cohort study. *Eur J Haematol* 2013; **90**: 426-33.
 46. Steigerwalt RD, Pascarella A, De Angelis M, et al. An ultra-low-molecular-weight heparin, fondaparinux, to treat retinal vein occlusion. *Drug Discov Ther* 2016; **10**: 167-71.
 47. Park SJ, Lee E, Lee K, et al. Efficacy and safety of non-vitamin K-antagonist oral anticoagulants for retinal vascular diseases in patients with atrial fibrillation: Korean cohort study. *Sci Rep* 2020; **10**: 4577.
 48. Natural history and clinical management of central retinal vein occlusion. The Central Vein Occlusion Study Group. *Arch Ophthalmol* 1997; **115**: 486-91.
 49. el Baba F, Jarrett WH, Harbin TS, et al. Massive hemorrhage complicating age-related macular degeneration. Clinicopathologic correlation and role of anticoagulants. *Ophthalmology* 1986; **93**: 1581-92.
 50. Kanukollu V, Ahmad S. Retina Hemorrhage; 2021. Available at: <https://www.ncbi.nlm.nih.gov/books/NBK560777/>. Accessed on 22/11/2021.
 51. Saxena S, Jalali S, Verma L, et al. Management of vitreous haemorrhage. *Indian J Ophthalmol* 2003; **51**: 189-96.
 52. Narendran N, Williamson TH. The effects of aspirin and warfarin therapy on haemorrhage in vitreoretinal surgery. *Acta Ophthalmol Scand* 2003; **81**: 38-40.
 53. Fu AD, McDonald HR, Williams DF, et al. Anticoagulation with warfarin in vitreoretinal surgery. *Retina* 2007; **27**: 290-5.

ONLINE SUPPLEMENTARY CONTENT

Table SI- Panelist' agreement to the proposed position statements

Statement	I agree	I do not agree
In all patients with suspected RVO, we recommend immediate ophthalmic consultation including visual acuity assessment, fundus and ocular tone examination, optical coherence tomography, and fluorescein-angiography if ischemia suspected, to confirm diagnosis and assess degree of functional impairment.	10	0
In all patients with a confirmed diagnosis of RVO, we recommend a multidisciplinary approach involving an expert in thrombosis and haemostasis to plan risk factor assessment and treatment strategies.	10	0
In patients with RVO who have no apparent systemic risk factors, especially in those aged < 45 years, we suggest assessing the complete panel of antiphospholipid antibodies (i.e., lupus anticoagulant, anti-cardiolipin and anti- β 2-glycoprotein) and measurement of homocysteine. The search for lupus anticoagulant should be performed when patients are far from anticoagulation.	7	3
In all patients with RVO, we recommend careful assessment and treatment of cardiovascular risk factors, with particular attention to arterial hypertension, dyslipidemia, diabetes mellitus, and hyperhomocysteinemia.	10	0
Considering the potential prothrombotic effect of estrogen therapy, we suggest alternative contraceptive methods in all women in whom these agents may have contributed to RVO development.	7	3
In patients with recent onset RVO (within 15-30 days) at low bleeding risk and without local risk factors (e.g., hyperopia, glaucoma), we recommend the use of therapeutic dose of LMWH for the first week followed by half dose LMWH for 1 to 3 months over aspirin or no treatment.	8	2
We suggest not to consider small and isolated retinal haemorrhage as an absolute contraindication to antithrombotic treatment in patients with RVO.	7	3
In patients taking antiplatelet therapy for stable arterial disease, we suggest to temporarily withhold antiplatelet therapy when full dose LMWH therapy is prescribed for recent RVO.	7	3
We recommend performing vitreal procedures, when indicated, at the trough levels of anticoagulant therapy.	10	0
We recommend considering long-term aspirin administration for primary prevention of cardiovascular disease in patients with RVO at high or very high cardiovascular risk.	10	0